



ISSN (P): 2521-3466  
ISSN (E): 2521-3474  
© Clinical Orthopaedics  
[www.orthoresearchjournal.com](http://www.orthoresearchjournal.com)  
2022; 6(3): 17-22  
Received: 15-05-2022  
Accepted: 23-07-2022

**Jakkula Nityananda Rao**  
MD, MBBS, MS Orthopedics Ex  
Fellow in Trauma, Orthopedics,  
Elmhurst hospital, ICAHN  
School of Medicine at Mount  
Sinai, New York, USA

**Moola Sohith Mahadeva Reddy**  
MBBS Student, Kamineni  
Institute of Medical Science,  
Narketpally, Nalgonda,  
Telangana, India

**Karri Jagadeeswar Reddy**  
MBBS MS ortho Consultant  
Orthopaedic Surgeon, Palnadu  
Hospitals, Piduguralla, Guntur,  
Andhra Pradesh, India

## Postoperative complications following ACL reconstruction: Prevention and management

**Jakkula Nityananda Rao, Moola Sohith Mahadeva Reddy and Karri Jagadeeswar Reddy**

DOI: <https://doi.org/10.33545/orthor.2022.v6.i3a.369>

### Abstract

This article aims to conduct a literature analysis on the current care and prevention strategies for postoperative problems following the repair of the anterior cruciate ligament (ACL). A presentation will be given on current trends in rehabilitation procedures, suggestions for interventions, and anticipated milestones in the healing process after ACL surgery. In recent years, protocols for ACL repair have progressed to a criterion-based progression rather than a tissue healing time frame. Because of advancements in ACL surgical reconstruction techniques and rehabilitation protocols, the danger of postoperative complications can manifest itself at any point during the recovery process. This includes both the beginning and the end of the process. In this paper, we will examine the significance of preventative measures for postoperative patient who has undergone ACL repair. Infection and loss of knee motion and strength are short-term complications that can occur after an ACL reconstruction. Long-term complications can include a secondary ACL injury to either the involved knee or the contralateral knee and the inability to return to high-level sports after this procedure. The multifaceted causes of secondary ACL injuries and the limited capacity of patients to return to high-level activities should continue to be the focus of future research.

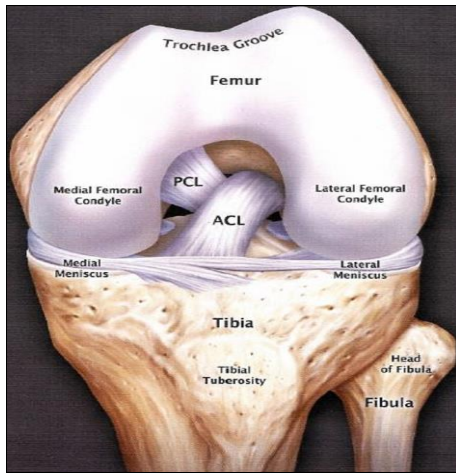
**Keywords:** ACL reconstruction, sport, rehabilitation, postoperative, complications

### Introduction

It is estimated that 200,000 anterior cruciate ligaments (ACL) reconstructions are performed annually in the United States. In addition, epidemiological data reveals that recent trends point to an increase in the incidence of ACL tears, leading to an increase in the number of subsequent reconstructions [1, 2]. The goal of surgical restoration of the anterior cruciate ligament (ACL) is to return the knee joint to its normal anatomy and biomechanics, enabling patients to resume their prior athletic or occupational activity [3]. The athlete's rehabilitation should proceed safely using a tiered approach based on established recommendations to minimize any issues that may arise as a result of the surgery [4]. It is essential to keep the patient's goals in mind throughout the rehabilitation process to ensure that specific functional and sport-specific exercises are incorporated when appropriate. In addition, the patient, the rehabilitation staff, and the surgeon must maintain open lines of communication in order to facilitate a safe and effective healing process [5, 6].

### Corresponding Author:

**Jakkula Nityananda Rao**  
MD, MBBS, MS Orthopedics Ex  
Fellow in Trauma, Orthopedics,  
Elmhurst hospital, ICAHN  
School of Medicine at Mount  
Sinai, New York, USA



**Fig 1:** Schematic presentation of AC

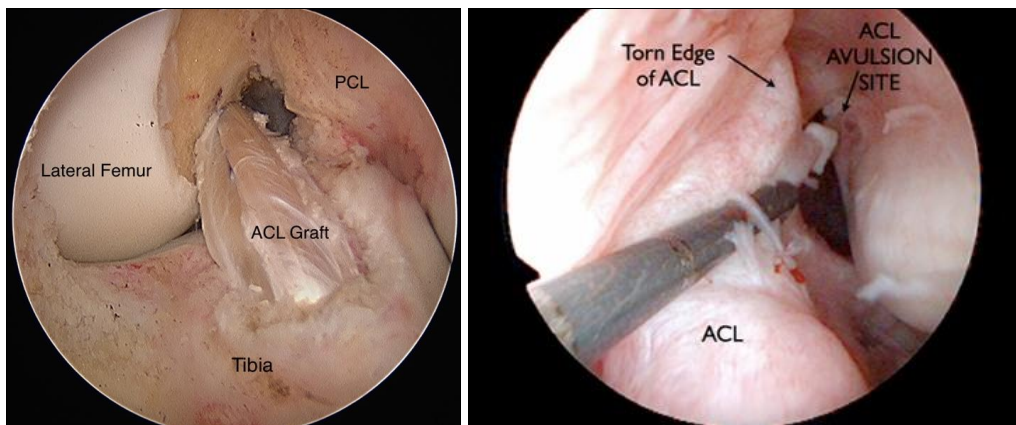
### Rehabilitation Practices

The surgical and rehabilitation staff encourages monitoring should any concerns develop because the postoperative knee joint infection is uncommon but possible. According to Gobbi *et al.*, the infection rate following ACL repair was 0.37%, with an infection's beginning time from surgery ranging from 7.5 to 61.7 days [7, 8]. The presence of an acutely swollen and painful knee joint, restricted knee ROM, and a sudden increase in pulsatile knee pain rapidly increased. Persistent effusion, incisional drainage, local erythema, warmth, intermittent fever (typically over 38 °C), and hyperemia with serous or purulent discharge can all be an infection in this population. When a postoperative patient exhibits symptoms of a suspected infection, the surgeon and the rehabilitation staff must keep lines of communication open [9, 10].

After surgery, formal physical therapy is frequently started three to ten days later. The patient is frequently trained on the use of

crutches for ambulation with weight-bearing as tolerated as well as the use of ice to treat discomfort and swell at the time of discharge right after ACL reconstruction surgery [11, 12]. Depending on the surgeon's decision, a postoperative knee brace may or may not be used. Enhancing knee range of motion is one of the main objectives of physical therapy during the early postoperative rehabilitation phase. Within the first two weeks, the patient should be able to extend their knee fully, both passively and actively [13]. Arthrofibrosis is a possible consequence and can have a substantial long-term impact on pain, gait, and function when complete knee extension ROM is not achieved. Arthrofibrosis is an inflammatory response that causes joint fibrosis and reduced knee motion following knee surgery, trauma, or immobilization. Early after surgery, the main objective should be to prevent knee joint stiffness and

Possible arthrofibrosis [14]. The patient must continue the home exercises created to treat knee extension ROM. The frequency of physical therapy sessions must be set to maximize the earliest possible recovery of full knee extension ROM. Recognizing that even a loss of fewer than 5 degrees of knee extension range of motion (ROM) can cause problems with long-term patellofemoral discomfort, weak quadriceps muscles, and an irregular bent-knee stride. Therefore, consideration should be given to these workouts' frequency, duration, and intensity. If knee extension ROM does not improve, the intervention dosage may need to be increased; conversely, if knee discomfort, swelling, or ROM gets worse, the dosage, especially intensity, may need to be reduced. Low-load, long-duration stretching is advised for people with a knee extension range of motion to help them improve their extension mobility. For those not responding to conventional therapies, adding serial casts, drop-out casts, and daily physical therapy may further address the loss of motion [15-17].



**Fig 2:** ACL surgery

Dealing with knee effusion and stretching and manual therapy techniques may help increase knee ROM and quadriceps muscle activation. Knee compression with a knee sleeve or compression wrap and cryotherapy may help to reduce postoperative knee joint swelling. Electrical stimulation, analgesic drugs, and cryotherapy effectively treat postoperative pain [18]. After surgery, rehabilitation should be planned and advanced gradually to avoid complications like tendonitis or pain in the anterior knee. Rehabilitation should concentrate on restoring strength throughout the postoperative course of care because strength impairments are frequent following ACL reconstruction. The quadriceps femoris muscle activation should

be addressed during early recovery. This can be determined by observing the quadriceps contract visibly when the knee is fully extended, at which point the patella should be observed sliding superiorly. The inability to fully extend the knee will interfere with the quadriceps set's ability to achieve greater patella glide. Performing an active straight leg lift against gravity without a lag or being unable to sustain full knee extension with the knee straight is another achievement. The capacity to maintain the knee in full extension for 10 to 30 repetitions without experiencing a lag is frequently used as a benchmark for when the postoperative knee brace can be removed [19-21].

### Final postoperative Obstacles

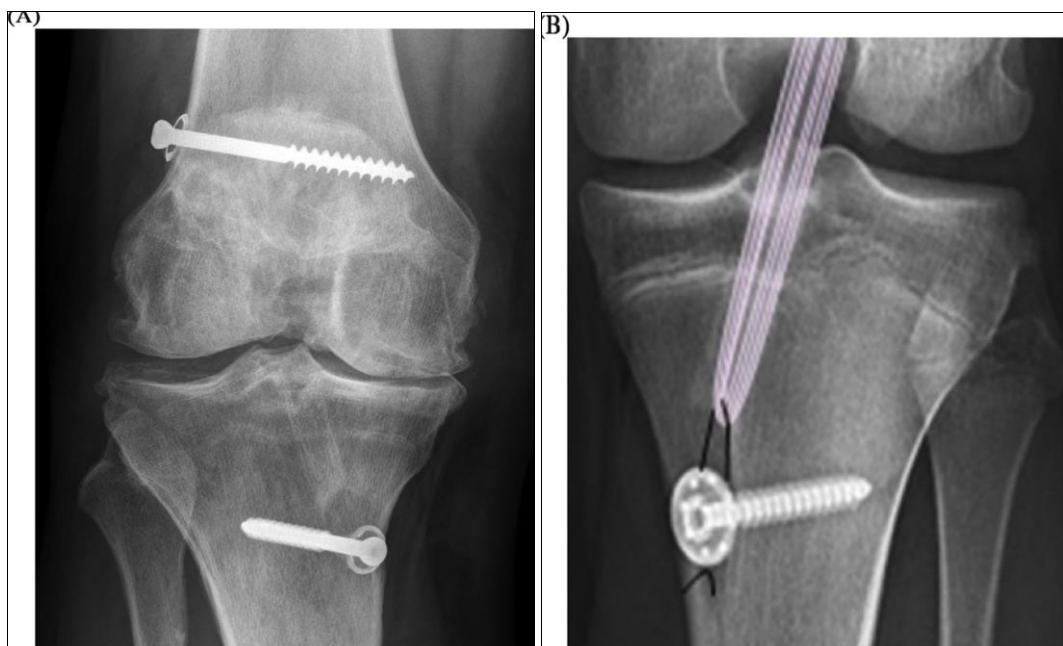
Following ACL surgery, strength deficits, particularly in the quadriceps femoris muscle group, are a severe problem because they can significantly limit functional capacity and increase the risk of lower-extremity injury. Additionally, it is a deficiency that can be reduced by using practical strength training and neuromuscular rehabilitation methods. Bilateral landing knee joint loading patterns are significantly impacted by isometric quadriceps femoris strength deficiencies of more than 15% [22, 23]. In a recent study, Schmitt and colleagues discovered that people with quadriceps femoris strength impairments had altered landing patterns. These altered landing patterns include lower peak knee external flexion moment, lower peak vertical ground response forces, and higher peak loading rates for limbs that were not involved in the landing. In addition to functional asymmetries at the knee joint, compensatory loading changes in the landing mechanics of the trunk, hip, and ankle joints may also be seen after ACL reconstruction. After ACL reconstruction, functional impairments in force development and absorption as measured by vertical single-leg jump height have remained [24-26].

Strength testing should be done frequently to monitor recovery and see if function-advancing milestones are reached. Handheld or isokinetic dynamometry is the method of choice when attempting to quantify the strength of the quadriceps and hamstrings. A deficit of less than 20-30% is acceptable for advancement into running and light plyometrics. In comparison, a loss of less than 10% on quadriceps and hamstring strength is acceptable for progression into sport-specific skills and activities. If no isokinetic equipment is available, a 1-repetition maximal leg press may be used in its place [27]. If all phase goals are accomplished, including the patient obtaining less than a 20% deficit on quadriceps strength testing, functional hop

testing can begin at least 12 weeks after surgery. The four hop tests that are advised are the single-leg for distance, triple-leg for distance, crossover hop for distance, and 6-m timed hop for distance. Additional objective information would be available to advance into sport-specific activities with a deficit of less than 10% on all tests. After ACL surgery, 63-65% of patients return to sport, with 44-46% returning to competitive participation. [28]. Those who failed the six-month return-to-sport test showed altered contralateral hip strategy with restricted motion and attenuating forces about the damaged knee during locomotion. A systemic assessment of 15 research found weak evidence that functional knee bracing lowers the re-injury rate. However, functional knee bracing may benefit via *in vivo* knee kinematics after ACL surgery [29-31].

### Management of re-injury

It has been discovered that having an ACL tear is linked to an increased chance of suffering a second ACL injury and long-term cartilage deterioration. A secondary injury is thought to have a multifactorial mechanism. Seven months after returning to the sport, re-injury risk is highest [32]. In young, active people, second ACL injuries have been found to occur as frequently as 24% of the time. A higher risk of subsequent ACL damage is linked to younger ages and resuming high levels of activity (cutting/pivoting sports). Second ACL tears are more common in the limb on the opposite side and may be brought on by asymmetrical stress. Wright *et al.* reported a second injury rate of 17.2%, with graft failure rates of 11.8% contralateral and 5.8% ipsilateral. According to a recent study, women are 33.7% more likely than men to need contralateral ACL surgery. The increased risk may result from increased compensatory loads on the unaffected limb for the opposite extremity [33-35].



**Fig 3:** ACL reconstruction

### Prevention and care

During the rehabilitation process for people who have had an ACL reconstruction, prevention of ACL injuries should be considered. These individuals probably have poor neuromuscular control and biomechanical impairments because many ACL injuries originate from noncontact [36]. Programs for preventing ACL injuries that include a dynamic warm-up with

strengthening, agility, balancing, and plyometric exercises have generally been proven successful in the short term. These exercises both have neuromuscular training components and can potentially lower the rate of ACL injury. Since concentrating only on one kind of exercise alone has been demonstrated to be ineffective for preventing ACL injuries, preventative programs should incorporate various neuromuscular training methods [37].

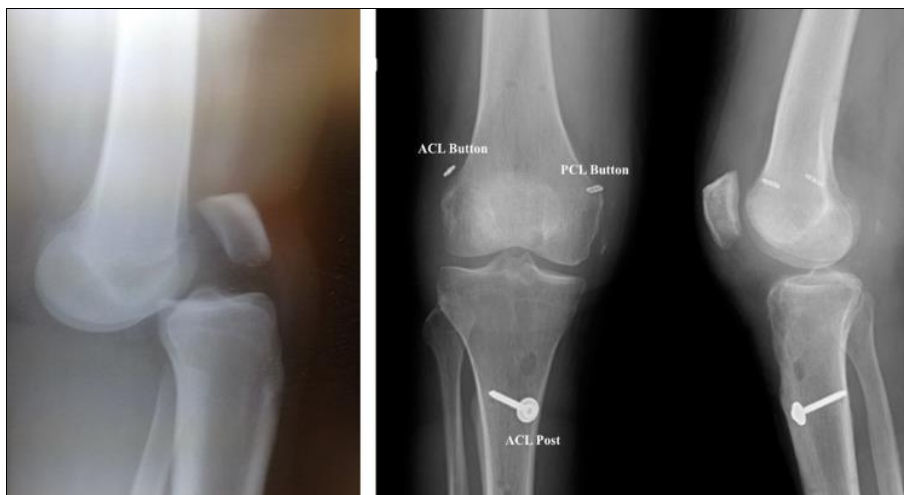
Thirty minutes twice a week during in-season training was determined to be the most beneficial dosage in these preventative regimens. Multiple studies discovered that including proximal control training exercises such as planks, side planks, sit-ups, push-ups, and upper body weight training led to a more significant reduction in ACL injuries. When focusing on balance, strength, movement feedback, and neuromuscular control, a relative risk decrease of 73.4% have been documented. Program success may be aided by focusing on biomechanical techniques and customized feedback. According to Benjamin *et al.*, preventative programs only have a limited long-term impact, which is thought to be due to the difficulties in learning and applying newly acquired motor skills. It is possible to use either an internal or external focus of attention to learn and get better at motor tasks. With an internal focus of attention, the athlete would concentrate on the movements themselves, giving cues to keep their knee correctly positioned over their second toe, for example [38].

The athlete would concentrate on the effect and result of the

movement if there was an external focus of attention, such as giving cues to keep their knee in line with a cone or another target. An external focus of attention may boost the athlete's ability to learn skills efficiently, adhere to the program more consistently, and more effectively apply their enhanced motor skills to sports-related activities. The internal focus may provide a more conscious control of movement, which is less than ideal for high-level sports activities. In contrast, the exterior focus may use a more unconscious or automatic control technique. In order to increase the efficiency of motor learning in this group, the manner and timing of feedback transmission should also be taken into account. Additionally, certain people may benefit from combining their internal and exterior focus of attention in order to enhance carryover effectiveness. By targeting neurocognitive and neurophysiological variables, dual-task difficulties such as memory recall, environmental stimulus (ball or partner perturbations), or direct visual perturbations prevention programs can also strengthen prevention programs [39].

**Box 1. Potential complications post anterior cruciate ligament reconstruction and associated symptoms:**

Symptoms	Possible causes
Lax and unstable knee	<ul style="list-style-type: none"> <li>• Graft disruption</li> <li>- Partial and complete tears</li> <li>- Ganglion cyst formation</li> </ul>
Decreased range of motion	<ul style="list-style-type: none"> <li>• Graft impingement</li> <li>- Graft tunnel placement</li> <li>- Intercondylar notch bony spurs</li> <li>• Arthrofibrosis</li> <li>- Diffuse</li> <li>• Localised (cyclops lesion)</li> </ul>



**Fig 4:** ACL surgery and ligament reconstruction

**Management of fear**

Future knee pain, function, and return to sport following an ACL injury were found to be related to self-drive, self-efficacy, and optimism. Knee discomfort and function may be inversely related to kinesiophobia or fear of movement. Tampa Scale of Kinesiophobia will enable the rehabilitation team to identify

patients with a severe fear of movement who, as a result, require a change in the therapeutic strategy. The patient who demonstrates significant fear may benefit from postponing the protocol's progression, receiving information to boost patient self-efficacy, and implementing neuromuscular re-education approaches such as perturbation training. It has been

demonstrated that kinesiophobia and pain catastrophizing are two psychological characteristics significantly associated with not returning to sport [40, 41].

### Application

Although the use of physical therapy sessions following ACL repair is frequently a subject of clinical discussion, there is little evidence. Physical therapists should consider the frequency of visits along the rehabilitation timeline following ACL repair, given the current condition of healthcare spending and the growing need to maximize service efficacy. The frequency of visits is frequently determined by insurance coverage. Thus patient education should be stressed throughout the healing process. Physical therapists are uniquely positioned to decide how frequently patients should be seen throughout the postoperative rehabilitation process [41]. We propose that the main reasons for visits early in the recovery process should be a pain, range of motion, and quadriceps activity. Patients with high levels of discomfort, severe ROM loss, inadequate strength, and restricted quadriceps activation would unquestionably benefit from physical therapy sessions spread throughout the week. As opposed to this, patients who are still in the early stages of their postoperative rehabilitation and who have slight discomfort, improving range of motion, and sound quadriceps activation may benefit from weekly physical therapy sessions for the physical therapist's monitoring and progression. Increased frequency of formal physical therapy sessions may be required as the postoperative course develops to address functional strength and neuromuscular control exercises with an emphasis on appropriate movement patterns. To ensure a safe transition into a running program and sport-specific exercises, as well as to get the best possible outcomes on return to sport testing, a more extended period of care may also be necessary [42].

### Conclusions

In conclusion, ACL rehabilitation principles constantly change in response to new data. Physicians and surgeons should maintain an appropriate conversation to maximize a patient's safe rehabilitation and return to sport. Instead of focusing on time, current protocols highlight criteria for moving on to the next step. For progress, it is essential to use both patient-reported and objective functional outcome indicators. Early emphasis on extension of the range of motion is crucial. If a patient receives little to gain from physical therapy, it may be necessary to visit a patient more frequently in the early stages of rehabilitation. Quadriceps strength is another essential element in preventing complications, and NMES is advised for all patients as it has been demonstrated to help with quadriceps function restoration. Re-injury rates are significant, but programs to prevent injuries have shown they can lower ACL tears.

If all of the advice in this article are followed, there is a good chance of successful recovery with few difficulties.

**Conflict of Interest:** None

**Funding Support:** Nil

### References

1. Lin TY, Chung CC, Chen WC, Su CW, Fang HW, Lu YC. Complications following all-inside anterior cruciate ligament reconstruction. *International Orthopaedics*; c2022. p. 1-8.
2. Sayegh MJ, Burgess C, Paulino F, Sgaglione NA. Management of the Stiff ACL Reconstruction. In Revision Anterior Cruciate Ligament Reconstruction. Springer, Cham; c2022. p. 289-300.
3. Rodríguez-Merchán EC, De la Corte-Rodríguez H, Encinas-Ullán CA, Gómez-Cardero P. Complications of surgical reconstruction of multiligament injuries of the knee joint: diagnosis, prevention and treatment. *EFORT Open Reviews*. 2021;6(10):973-981.
4. Bayle-Iniguez X, Cassard X, Vinciguerra B, Murgier J. Postoperative thromboprophylaxis does not reduce the incidence of thromboembolic events after ACL reconstruction. *Orthopaedics & Traumatology: Surgery & Research*. 2021;107(4):102904.
5. Nair RS, Nair RR, Munshi S, Walkay S, Radhamony NG. Analysis of postoperative complications following elective arthroscopic surgeries of the knee-a retrospective cohort study. *Annals of Medicine and Surgery*. 2022;77:103546.
6. Sezer HB, Noailles T, Toanen C, Lefèvre N, Bohu Y, Fayard JM, *et al*. Early postoperative practices following anterior cruciate ligament reconstruction in France. *Orthopaedics & Traumatology: Surgery & Research*. 2021;107(8):103065.
7. Ridenour R, Kowalski C, Yadavalli A, Ba D, Liu G, Leslie D, *et al*. Preoperative opioid use is associated with persistent use, readmission, and postoperative complications after arthroscopic knee surgery. *Arthroscopy: The Journal of Arthroscopic & Related Surgery*. 2021;37(5):1567-1572.
8. Battaglia TC. Management of Intraoperative Graft-related Challenges in Anterior Cruciate Ligament Reconstruction. *Journal of the American Academy of Orthopaedic Surgeons*. 2022;30(10):448-456.
9. Jin T, Li Y, Yang G, Liao X, Wang G, Wang F. Comparison of Rapid Rehabilitation after Anterior Cruciate Ligament Reconstruction with Tensioning Technique and Traditional Rehabilitation. *Disease Markers*; c2022.
10. Leland DP, Pareek A, Therrien E, Wilbur RR, Stuart MJ, Krych AJ, *et al*. Neurological Complications Following Arthroscopic and Related Sports Surgery: Prevention, Workup, and Treatment. *Sports medicine and arthroscopy review*. 2022;30(1):e1-e8.
11. Kaneguchi A, Ozawa J, Minamimoto K, Yamaoka K. Low-Level Laser Therapy Attenuates Atherogenic Contracture Induced by Anterior Cruciate Ligament Reconstruction Surgery in Rats. *Physiological Research*. 2022, 71(3).
12. Chergui S, Denis A, Meterissian J, Benaroch L, Pauyo T. Biologics: Post-traumatic Osteoarthritis Following Anterior Cruciate Ligament Reconstruction. In *Advances in Knee Ligament and Knee Preservation Surgery*. Springer, Cham; 2022. p. 133-149.
13. Bolia IK, Horatian A, Bell JA, Hasan LK, Saboori N, Palmer R, *et al*. Managing perioperative pain after anterior cruciate ligament (ACL) reconstruction: perspectives from a sports medicine surgeon. *Open Access Journal of Sports Medicine*. 2021;12:129.
14. Xiong J, Zhang Q, Li Y. Clinical Study of Neuromuscular Electrical Stimulation in the Prevention of Deep Venous Thrombosis of Lower Extremities after Anterior Cruciate Ligament Reconstruction. *Journal of Healthcare Engineering*, 2022.
15. Yapıcı F, Gür V, Sarı İF, Köksal A, Yurten H, Üçpunar H, *et al*. Prescription of knee braces after anterior cruciate ligament reconstruction: Fact or fiction; c2022.
16. Mousavi H, Akbari-Aghdam H, Entezari R. The effect of tranexamic acid injection during anterior cruciate ligament reconstruction surgery on postoperative bleeding, pain, and

- swelling. *European Journal of Orthopaedic Surgery & Traumatology*; c2022. p. 1-6.
17. Geethan I, Easwaran R, Sahanand S, Sivaraman A, Gupta A, Devgan A, *et al.* Management guidelines for infection after ACL reconstruction: expert opinion statement based on the modified Delphi survey of Indian arthroscopy surgeons. *Indian journal of orthopedics*. 2021;55(2):342-351.
  18. Fouasson-Chailloux A, Crenn V, Louguet B, Grondin J, Menu P, Dauty M. Therapeutic Patient Education after Anterior Cruciate Ligament Reconstruction: Evaluation of the Knowledge and Certitudes with a Self-Report Questionnaire. In *Healthcare*. 2022 May;10(5):934. MDPI.
  19. McIntire SC, Bernstein EM, Company TM, Briggs AM, Ferris WJ, Renninger CH, *et al.* Aspirin for Deep-Venous Thrombosis Prophylaxis After Anterior Cruciate Ligament Reconstruction. *Military Medicine*. 2021;186(7-8):656-660.
  20. Vertullo CJ. Editorial commentary: is it time for the vancomycin wrap to become a universal recommendation for the prevention of septic arthritis following anterior cruciate ligament reconstruction? *Arthroscopy: The Journal of Arthroscopic & Related Surgery*. 2021;37(5):1691-1693.
  21. Zhou Q, Yu L, Yin C, Zhang Q, Tai Y, Zhu L, *et al.* Effect of Transauricular Vagus Nerve Stimulation on Rebound Pain After Ropivacaine Single Injection Femoral Nerve Block for Anterior Cruciate Ligament Reconstruction: A Randomized Controlled Trial. *Journal of Pain Research*. 2022;15:1949.
  22. Tapasvi S, Shekhar A. Revision ACL reconstruction: principles and practice. *Indian Journal of Orthopaedics*. 2021;55(2):263-275.
  23. Fury MS, Paschos NK, Fabricant PD, PLUTO Study Group, *et al.* Assessment of skeletal maturity and postoperative growth disturbance after anterior cruciate ligament reconstruction in skeletally immature patients: a systematic review. *The American Journal of Sports Medicine*. 2022;50(5):1430-1441.
  24. Schmitz JK. Complications Following Anterior Cruciate Ligament Reconstruction (Doctoral dissertation, Karolinska Institutet (Sweden); c2021.
  25. Khatri K, Sidhu G, Jindal S, Bansal D, Goyal D. Low-dose Perioperative Dexamethasone Improves 24-hour Postoperative Pain after Anterior Cruciate Ligament Reconstruction. *Malaysian Orthopaedic Journal*. 2022;16(1):76.
  26. Pullen WM, Money AJ, Ray TE, Freehill MT, Sherman SL. Postoperative Infection: Prevention, Diagnosis, and Treatment Guidelines for the Sports Surgeon. *Sports Medicine and Arthroscopy Review*. 2022;30(1):17-23.
  27. Maheshwer B, Drager J, John NS, Williams BT, LaPrade RF, Chahla J. Incidence of Intraoperative and Postoperative Complications After Posterolateral Corner Reconstruction or Repair: A Systematic Review of the Current Literature. *The American Journal of Sports Medicine*. 2021;49(12):3443-3452.
  28. Papalia R, Cicione C, Russo F, Ambrosio L, Di Giacomo G, Vadalà G, *et al.* Does vancomycin wrapping in anterior cruciate ligament reconstruction affect tenocyte activity *in vitro*? *Antibiotics*. 2021;10(9):1087.
  29. Afana HB, Nau T. Physeal-Sparing Anterior Cruciate Ligament Reconstruction for Skeletally Immature Patients: All-Epiphyseal Technique Using Quadriceps Tendon Autograft. *Case Reports in Orthopedics*; c2021.
  30. Glatke KE, Tummala SV, Chhabra A. Anterior Cruciate Ligament Reconstruction Recovery and Rehabilitation: A Systematic Review. *JBJS*. 2022;104(8):739-754.
  31. Cuzzolin M, Previtali D, Zaffagnini S, Deabate L, Candrian C, Filardo G. Anterior Cruciate Ligament Reconstruction versus Nonoperative Treatment: Better Function and Less Secondary Meniscectomies But No Difference in Knee Osteoarthritis: A Meta-Analysis. *Cartilage*. 2021;13(1):1658S-1670S.
  32. Harris BT, Eichman EA, Johal MJ, Burrus MT. Pediatric anterior cruciate ligament reconstruction: A reason not to wait until skeletal maturity. *Cureus*, 2021, 13(11).
  33. Thakur U, Gulati V, Shah J, Tietze D, Chhabra A. Anterior cruciate ligament reconstruction related complications: 2D and 3D high-resolution magnetic resonance imaging evaluation. *Skeletal radiology*, 2022, 1-18.
  34. Moutzouros V, Jildeh TR, Tramer JS, Meta F, Kuhlmann N, Cross A, *et al.* Can we eliminate opioids after anterior cruciate ligament reconstruction? A prospective, randomized controlled trial. *The American journal of sports medicine*. 2021;49(14):3794-3801.
  35. D'Amore T, Rao S, Corvi J, Jack RA, Tjoumakaris FP, Ciccotti MG, *et al.* The Utility of Continuous Passive Motion after Anterior Cruciate Ligament Reconstruction: A Systematic Review of Comparative Studies. *Orthopaedic Journal of Sports Medicine*. 2021;9(6):23259671211013841.
  36. Ehlinger M, Panisset JC, Dejour D, Gonzalez JF, Pailhe R, Favreau H, *et al.* Anterior cruciate ligament reconstruction in the over-50s. A prospective comparative study between surgical and functional treatment. *Orthopaedics & Traumatology: Surgery & Research*. 2021;107(8):103039.
  37. Kaneguchi A, Ozawa J, Minamimoto K, Yamaoka K. Effects of each phase of anterior cruciate ligament reconstruction surgery on joint contracture in rats. *Journal of Investigative Surgery*. 2022;35(5):984-995.
  38. Marom N, Kapadia M, Nguyen JT, Ammerman B, Boyle C, Wolfe I, *et al.* Factors Associated With an Intra-articular Infection After Anterior Cruciate Ligament Reconstruction: A Large Single-Institution Cohort Study. *The American Journal of Sports Medicine*. 2022;50(5):1229-1236.
  39. Dhillon MS, Rangasamy K, Rajnish RK, Gopinathan NR. Paediatric Anterior Cruciate Ligament (ACL) Injuries: Current Concepts Review. *Indian Journal of Orthopaedics*; c2022. p. 1-11.
  40. Morris JL, McEwen P, Letson HL, Dobson GP. Anterior Cruciate Ligament Reconstruction Surgery: Creating a Permissive Healing Phenotype in Military Personnel and Civilians for Faster Recovery. *Military Medicine*; c2022.
  41. Rambaud AJ, Neri T, Dingenen B, Parker D, Servien E, Gokeler A, *et al.* The modifying factors that help improve anterior cruciate ligament reconstruction rehabilitation: A narrative review. *Annals of Physical and Rehabilitation Medicine*. 2022;65(4):101601.
  42. Akhtyamov IF, Aidarov VI, Khasanov ER. Current methods of rehabilitation after arthroscopic reconstruction of the anterior cruciate ligament of the knee joint (review of literature). *Genji Ortop*. 2021;27(1):121-127.