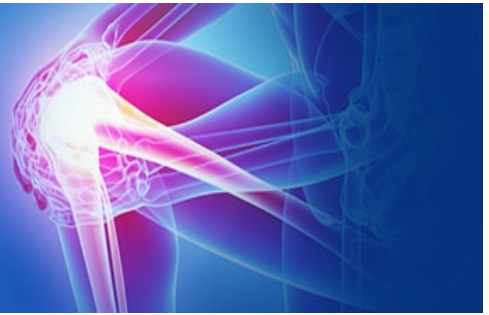

ISSN (P): 2521-3466
ISSN (E): 2521-3474
© Clinical Orthopaedics
www.orthoresearchjournal.com
2022; 6(2): 29-32
Received: 23-02-2022
Accepted: 27-03-2022

Dr. Arunkumar G
Assistant Professor, Department
of Orthopaedics, BIMS,
Belagavi, Karnataka, India

Dr. Ajeet Hundekar
Senior Resident, Department of
Orthopaedics, BIMS, Belagavi,
Karnataka, India

Dr. Satish Nesri
Assistant Professor, Department
of Orthopaedics, BIMS,
Belagavi, Karnataka, India

A prospective study of management of distal end of radius fractures in adults by ligamentotaxis using external fixator with distractor

Dr. Arunkumar G, Dr. Ajeet Hundekar and Dr. Satish Nesri

DOI: <https://doi.org/10.33545/orthor.2022.v6.i2a.364>

Abstract

Background and Objectives: Preservation of the articular congruity is the principle prerequisite for successful recovery following distal radius fractures. The best method of obtaining and maintaining an accurate restoration of articular anatomy however, remains a topic of considerable controversy. External fixator with distractor (UMEX) method is one of the treatment for distal end of radius fracture the main aim of this study is to evaluate the results obtained by treatment of distal end radius fractures by external fixation.

Method: In a prospective controlled study, 30 cases of unstable distal end radius fractures with intra-articular extension were treated by external fixator with distractor (UMEX) using the principle of ligamentotaxis. Mean age of the patients was 42.5 years, external fixator with distractor (UMEX) was applied for a mean duration of 6.5 weeks and cases were followed up for an average of 9 months post operatively.

Results: Assessed as per clinical scoring system of Green DP and O'Brien *et al.* for functional results at the end of 9 months of follow up. Excellent to good functional result was noted in 90%.

Conclusion: External fixation with distractor (Umex) and ligamentotaxis provides better functional and anatomical results in comminuted intra-articular distal radius fractures. The successful use of external fixator with distractor for distal end radial fractures requires careful assessment of fracture pattern, appropriate patient selecting meticulous surgical techniques appropriate choice of fixation, careful post-operative monitoring and aggressive early institution of rehabilitation. The final functional results of treatment of distal end radius fractures not only depends on the anatomical restoration of the articular surface but also on the associated soft tissue injuries and articular damage.

Keywords: Distal end radius fracture, external fixation with distractor (UMEX) ligamentotaxis, intraarticular fractures

Introduction

Fractures of distal radius are one of the most common skeletal injuries treated by orthopaedic or trauma surgeons. In fact these injuries are the most common fractures of the upper extremity and account for approximately 16% of all fractures seen and treated in emergency rooms.

It has become apparent that distal radius fractures associated with high energy trauma in younger adults with definable functional demands and those associated with shearing type fracture dislocations lead to significant functional disability if the articular anatomy is not restored to within a reasonable degree of congruency. The fact that these articulations are not weight bearing does not exclude them from becoming a major source of disability if the articular anatomy is not restored,

In this present study, external fixator with distractor has been used to treat fractures of distal radius. The study has been conducted to find out the efficacy of Universal Mini External Fixator (UMEX) in treatment of distal radius fractures and to gain the experience in the management of distal radius fractures with UME'X fixator and also to assess the complications and pitfalls of the UMEX fixator.

Objectives of the study

To assess the benefits external fixator and ligamentotaxis in comminuted

Corresponding Author:
Dr. Arunkumar G
Assistant Professor, Department
of Orthopaedics, BIMS,
Belagavi, Karnataka, India

- Distal end of radius fracture in adult.
- To assess the anatomical, radiological union and functional result, treated by using external fixator with distractor (Umex) by Green and O'Brein clinical score system.

Methodology

The present study was done on 30 cases of fractures of distal end of the radius which were managed by external fixator with distractor (UMEX) during the period from May 2021 to May 2022 in the Department of Orthopaedics, BIMS, Belagavi. The Clearance from ethical committee was obtained before the start of the study. Design of the study: prospective study. Study period: 12 months. Source of Data: 30 cases of adult patients with comminuted fracture distal end of radius.

Inclusion Criteria

Male and female – age 18 year to 70 years.

- Intra-articular /comminuted fracture of lower end of radius
- Closed and open fractures of distal end of radius (Gustilo – Anderson
- Type – I to Type III B) Fracture less than 3 weeks old
- Patients willing for treatment

Exclusion Criteria

Patients with neurovascular injuries.

- Patients who are medically unfit for surgery.
- Patient with pathological fracture.
- Fracture more than 3 weeks old

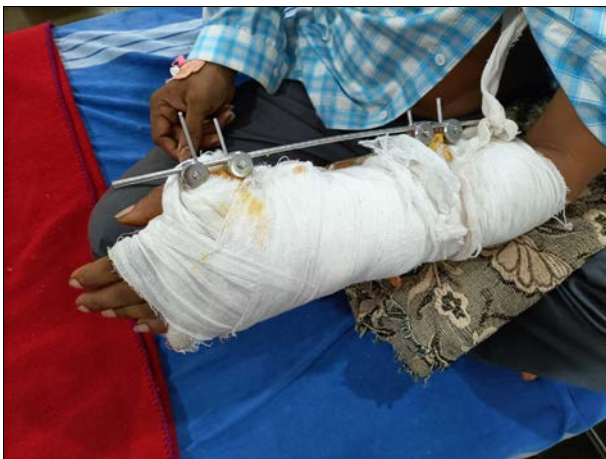

Fig 1: figure - Operated case of distal radius with forearm external fixator

Observation and Results

Discussion

The aims of treatment in fractures of distal end of the radius are to allow early functional recovery of the limb, to improve long term function of the wrist and to prevent cosmetic deformity and

external fixator effectively maintains the reduced position whereas treatment by plaster does not.

Bridging external fixator with ligamentotaxis for treatment of fracture distal end of radius has given promising results. Good functional result usually accompanies a good anatomical reduction. External fixation uses the concept of ligamentotaxis and is very useful in maintaining reduction and radial length. The basic principle of the treatment is to obtain accurate fracture reduction and to maintain the reduction while protecting the wrist in an anatomical position, so that the hand can be rehabilitated well. This study includes 30 cases of distal radius fractures which were managed by external fixator with distractor (UMEX fixator).

There were 19(63%) males and 11(37%) female patients. The increase in number of male patients is because of increase in number of RTA (road traffic accident) high energy trauma and fall which was noticed in young adults. We restricted our study group from 18-70 years because management and rate of union differ in younger and elderly age groups. The peak incidence in our study was in age group of 20-40 years and average age was 42.5 years.

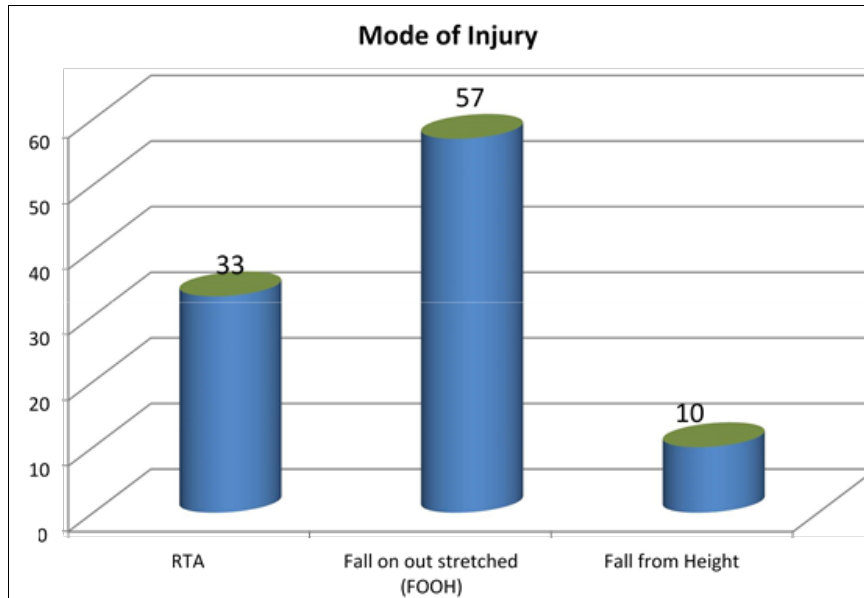
In our study two patients were no diabetic and two were hypertensive, there were no medical problems in others. There were one case of malunion found in our studies with dorsal tilt with limited restriction of movement and function. There were one cases of finger stiffness because of inadequate physiotherapy. None of the cases of non-union and neurological deficit either because of fracture or external fixator.

There were three cases of residual pain which was subsided after medications, there is no pintract infection and pin loosening, there were one case of shoulder hand syndrome noticed and advised for physiotherapy and ROM exercise for shoulder joint. One case of RSD advised for physiotherapy. One case of restricted wrist movement noticed advised physiotherapy and wrist mobilization exercise. In this study 7 had associated injuries, one patient had Ipsilateral clavicle fracture treated conservatively with clavicle brace for 4 weeks, one had ipsilateral bimalleolar fracture of ankle treated conservative management with below knee pop cast for 6 weeks.

One had L1 compression fracture treated conservatively with knight taylor brace, one had segmental ulna fracture treated ORIF with square nail. One had multiple rib injury treated conservatively, One had contralateral calcaneum fracture treated conservative by below knee pop cast for 6 week, one had ipsilateral neck of femur treated CRIF with AO cannulae screws.

Table 1: Mode of Injury

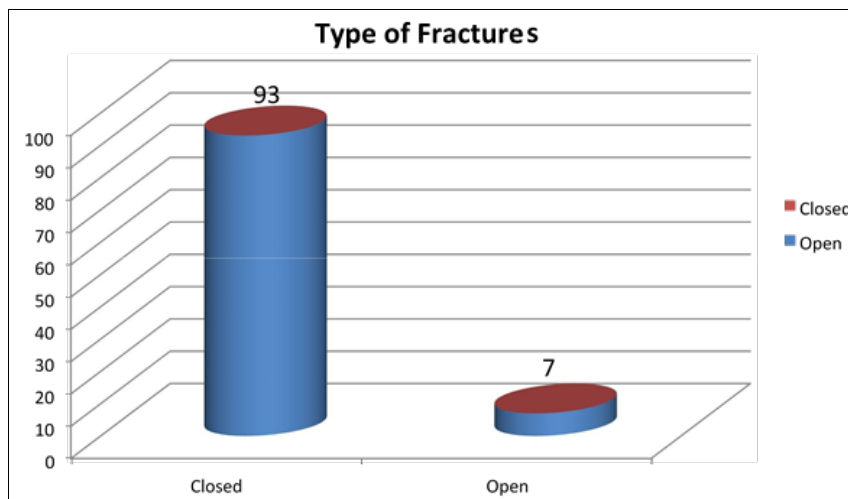
Mode of Injury	No of Cases	Percentage
RTA	10	33
Fall on out stretched (FOOH)	17	57
Fall from Height	3	10



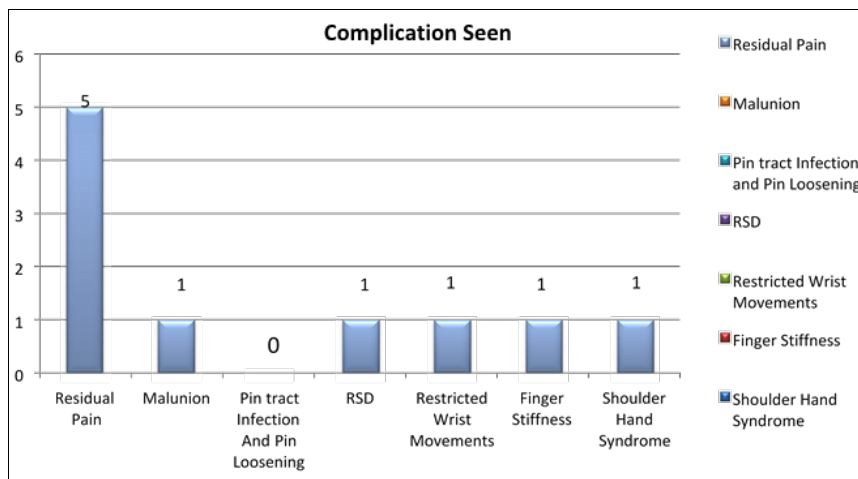
Graph 1: Mode of Injury

Table 2: Type of Fractures

Type	No of Cases	Percentage
Closed	28	93
Open	2	7



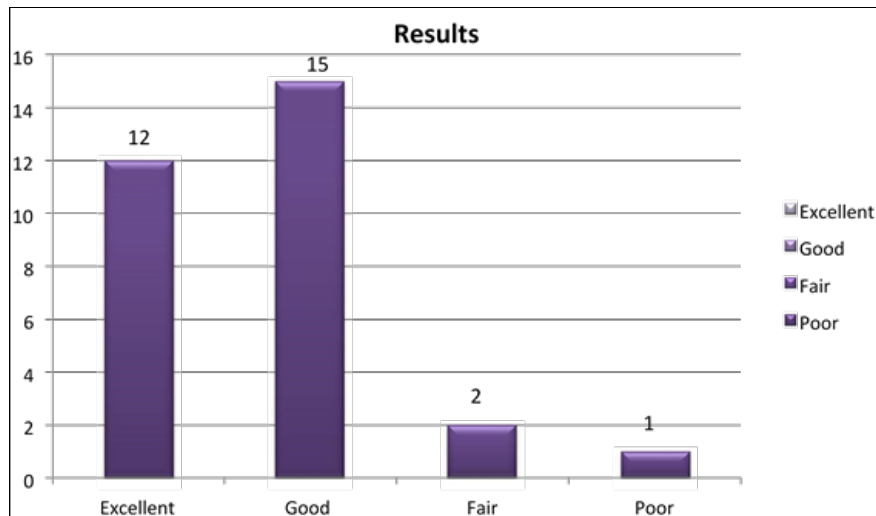
Graph 2: Mode of Fractures



Graph 3: Complication seen

Table 3: Complication Seen

Complication	No of Cases
Residual Pain	5
Malunion	1
Pin tract Infection and Pin Loosening	0
RSD (Reflex Sympathetic Dystrophy)	1
Restricted Wrist Movements	1
Finger Stiffness	1
Shoulder Hand Syndrome	1

**Graph 4:** Result**Conclusion**

Universal mini external fixator is a simple, effective and reasonably complication free tool for the management of comminuted intra articular fractures of the distal radius. UMEX fixator works on the principle of ligamentotaxis which helps in the anatomical reduction of the fracture fragments and the maintenance of reduction.

Good instrumentation and surgical have further refined the outcome in these patients. With precision in case selection, operative technique and adequate physiotherapy, universal mini external fixator consistently results in a favorable outcome in the management of comminuted intra articular distal radius fractures.

In conclusion uniplanar external fixation with distractor (UMEX) is an effective method in treating the unstable intraarticular fractures of the distal end of radius.

The final functional result of treatment of distal end radius fractures not only depends on the anatomical restoration of the articular surface but also on the associated soft tissue injuries and articular damage.

References

1. Colles A. On the Fracture of the carpal Extrimity of the Radius. Edinburg. Anatomical study. Med. Surg. J. 1814;10:182-186.
2. Anderson R, O'Neil G. Comminuted fractures of distal end of the radius. Surg Gyn Obstet. 1944;78:434-442.
3. Gartland J Jr, Werley CW. Evaluation of healed colles fractures J Bone Joint Surg. 1951;33-A:895-907.
4. Lidstrom A. Fractures of the Distal End of the Radius: A clinical and Statistical Study of End Results. Acta Orthop Scand. 1959;41(1):1-118.
5. Ellis J. Smith's and Barton's fractures: A Method of Treatment. J bone Joint Surg. 1965;47-B:724-7275.
6. Frykman G. Fracture of the Distal Radius Including

Sequelae–Shoulder,-Hand Finger Syndrome, Disturbance in the Distal Radio-Ulnar Joint, and Impairment of Nerve Function: A Clinical and Experimental Study. Acta Orthop Scand. 1967;108(1):1-153.

7. Green DP. Pins and Plaster Treatment of comminuted Fractures of the Distal End of the Radius. J Bone Joint Surg. 1975;57-A:304-310.
8. Sarmiento A, Pratt GW, Berry NC, Sinclair F, Colles Fractures: Functional Bracing in supination J Bone Joint Surg. 1975;57-A:311-317.
9. Vidal J, *et al.* Treatment of articular fractures by 'Ligamentotaxis' with external fixator. Edited by Brooker and Edwards: External Fixator- the current state of art. 1978.
10. WP, Linschied RL, Dobyns JH. External Pin Fixation for Unstable Colles' Fractures. J Bone Joint Surg. 1979.
11. Palmer AK, Werner FW. The triangular fibro cartilage complex of the wrist Anatomy and function. J Hand Surg. 1981;6:153-16.