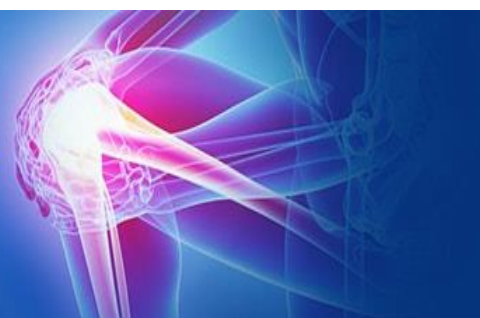



ISSN (P): 2521-3466  
ISSN (E): 2521-3474  
© Clinical Orthopaedics  
[www.orthoresearchjournal.com](http://www.orthoresearchjournal.com)  
2020; 4(1): 122-126  
Received: 06-11-2019  
Accepted: 20-12-2019

**Amar**  
Senior Resident, Gulbarga  
Institute of Medical Sciences,  
Karnataka, India

**Syed Azher Hussain**  
Assistant Professor, Department  
of Ortho, Gulbarga Institute of  
Medical Sciences, Kalaburgi,  
Karnataka, India

## A prospective study: Functional outcome of intra-articular distal humerus fractures treated with bicolunar locking plates in Indian population

**Amar and Syed Azher Hussain**

**DOI:** <https://doi.org/10.33545/orthor.2020.v4.i1c.218>

### Abstract

**Background:** Distal humerus fractures in adults are relatively uncommon and intra articular injuries amounting to 2 to 6 % of all fractures and 30 % of all elbow fractures. The complex shape of the elbow joint, the adjacent neurovascular structures make these fractures difficult to treat. Open reduction and surgical fixation with plating gives good results. The Aim of our study is to evaluate the functional outcome of intra-articular distal humerus fractures by open reduction and internal fixation using bicolunar plating technique.

**Materials and Methods:** A total of 20 intra articular distal humerus fractures were operated between June 2016 to June 2019 were included in the study. All patients are above the age of 18 years. All the patients were operated with pre-counter distal humerus locking plates in orthogonal fashion and outcome was measured by MEPS, rate of union, rate of complications and final range of motion.

**Results:** In our series of 20 cases, there were 14 males and 6 females. 6 cases were due to self-fall, 12 were due to RTA and two due to assault. Out of 20 cases, 1 (5%) were of C1 type of fractures, 16 (80%) were of C2 and 3 (15%) were of C3 type of fractures. The average duration of the radiological union was 13±04 weeks. Excellent results were seen in 10, good in 6 and fair in 3, and poor in 1, according to MEPS. 2 patients had transient radial neuropraxia and 1 had transient ulnar neuropraxia in early postoperative period.

**Conclusion:** To get good functional results with good range of movement and fracture union, precise preoperative planning, adequate surgical approach, anatomical inter fragmentary stabilization, Operative treatment with stable anatomical internal fixation gives best chance to achieve good elbow function.

**Keywords:** Intra-articular distal humerus fractures; ORIF, Bicolunar plating, MEPS.

### Introduction

In adults, most distal humerus fractures are intra-articular and involve both the medial and lateral columns<sup>1</sup>. Distal humerus fractures in adults are relatively uncommon injuries amounting to 2 to 6 % of all fractures and 30 % of all elbow fractures<sup>[15]</sup>. Distal humerus fractures occur in the younger age group secondary to high energy trauma and in elderly woman as a result of relatively low energy trauma<sup>[2]</sup>. Many studies reports as regards to functional outcome of open reduction and internal fixation of these fractures. Also, newer literature suggests, total elbow arthroplasty<sup>[14]</sup>. The complex shape of the elbow joint, the adjacent neurovascular structures and the sparse soft tissue envelope combine to make these fractures difficult to treat. Acceptable results have been reported in a majority of patients treated by open reduction and internal fixation<sup>[3]</sup>. Restoration of painless and satisfactory elbow function after a fracture of the distal humerus requires anatomic reconstruction of the articular surface, restoration of the overall geometry of the distal humerus, and stable fixation of the fractured fragments to allow early and full rehabilitation<sup>[4]</sup>. Based on fracture pattern and displacement, other method of surgical fixation like open reduction and internal fixation with Kirschner wires, semi tubular plates, Dynamic Compression Plates, Reconstruction plates, Locking Compression plates, pre-contoured plates or Double tension band wiring can be done individually or in combination. On the basis of the results reported in the more recent series, fixation with two plates at 90 degrees angle with one another or parallel plate arrangement has become the standard against which all other treatments are measured.

**Corresponding Author:**  
**Syed Azher Hussain**  
Assistant Professor, Department  
of Ortho, Gulbarga Institute of  
Medical Sciences, Kalaburgi,  
Karnataka, India

The Orthopaedic Trauma Association's alpha-numeric system 3, assigned three main types: Type A (extra-articular), Type B (partial articular), and Type C (complete articular). The OTA system's clinical application is limited and is hindered by poor inter-observer reliability beyond identification of the basic three types [15]. The Aim of the present study is to evaluate the functional outcome of surgical management of intra articular distal humerus fractures by open reduction and internal fixation with bicolumnar plating technique using anatomically pre-contoured distal humerus plates.

### Materials and Methods

The present study includes 20 cases of supracondylar fracture with intra articular distal humerus fractures extension treated between June 2016 to June 2019. Both Male and female adult patients with intra articular distal humerus fractures with age above 18 years were included. All the patients were operated with pre countered distal humerus locking plates in orthogonal fashion and outcome was measured by MEPS, rate of union, rate of complications and final range of motion. Patients with open fractures, medically unfit for surgery and those not willing for surgery were not included in this study

### Operative Procedure

All the patients were put in lateral position with arm supported and forearm hanging. Brachial block in 17 cases and General anaesthesia was used in 3 cases. All the patients were operated with Posterior approach, the joint was exposure through olecranon osteotomy in all cases Surgical technique: All cases were approached by a mid line posterior straight incision with a curve around the olecranon on the elbow. Ulnar nerve was isolated and secured with umbilical tape. Articular surface was exposed by chevron olecranon osteotomy. All the fracture fragments were reduced and temporarily fixed with k wires and then fixed with standard plating technique in orthogonal fashion i.e one on medial aspect and another on postero-lateral aspect using pre contoured anatomical locking plates. Olecranon osteotomy fixed either with tension band wiring or CC screw. Wound was closed in layers with negative suction drain in situ. Above elbow plaster of Paris slab was applied. All the patients were observed in intensive care unit for 24 hours. Elbow immobilised in above elbow POP slab. After 48 hours, suction drain removed and dressings changed. Radiographs were taken to confirm the reduction and fixation. With adequate analgesia, passive wrist and finger exercises were started. POP continued for 3 days following which active and assisted elbow exercises are started with removable slab. Sutures removed on 16th day. All the patients were reviewed and evaluated clinically for pain, range of motion, stability and the function of the elbow. Serial radiological examination was done at 6 weeks, 12 weeks, and 6 months for the union of the fracture site and the osteotomy. Full elbow activity started at 8 weeks after radiological evidence of union was evident at the fracture. Active aggressive elbow mobilization was done.

### Results

The mean patient age was 38.45 years. 6(30%) patient were in age group of 20to30 years, 12(60%) patients were between 31-45 years, 2(10%) patients were between 46-60 years (Table 2). 6 patients (30%) were females and 14 patients (70%) were males. left side involvement is more 12(60%) cases and right side in 8(40%) cases. The mechanism of injury was road side accidents

12 cases in most of cases followed by falls 6 cases and assault 2 cases (Table 3). Out of 20 cases, 1(5%) were of C1 type of fractures, 16(80%) were of C2 and 3 (15%) were of C3 type of fractures (Graph 1). Most of the patients were operated after 48 hours of injury. The mean duration of follow up was 10 months, ranging from 8 to 12 months. The mean duration of surgery was 90 ±15min. The duration of fracture healing was 13 weeks, ranging from 9 to 17. The flexion at the elbow joint ranged from 60° to 120° degree. 16 patients had range of movement beyond 90°. Scoring of range of motion is done as per Mayo Elbow Performance Score. The final functional outcome was excellent in 10(50%), good in 6(30%), 3 fair (15%) and poor in 1(5%). Most of the fixations were stable. 2 patients had transient radial neuropraxia in the early post-operative period and 1 patients had transient ulnar neuropraxia and 1 patient had pin loosening and breakage of implant. No patient suffered from iatrogenic vascular injury, Non-union, heterotopic ossification.

**Table 1:** Mayo Elbow performance score

Pain intensity	Motion	Stability	Function (5 pts each)
None – 45 pts	Arc of motion: >100:20 pts	Stable to pts	Comb hair
Mild 30 pts	Arc of motion: 50-100 36 pts	Moderate instability : 5 pts	Feed self
Moderate 15 pts	Arc of motion <50 pts	Gross instability 0 pts	Hygeine
			Can do shirt
			Can do shoes

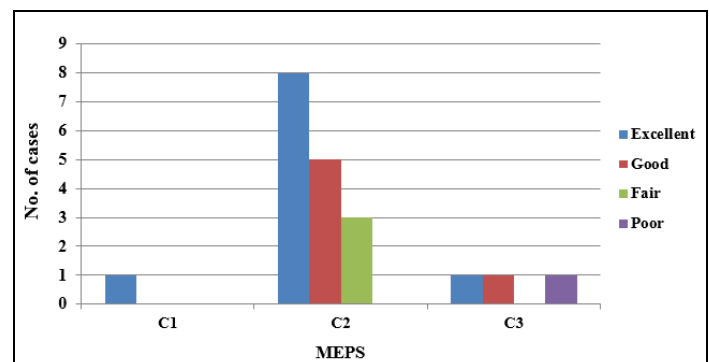
Score>90-Excellent: 75-89: Good; 60-74: Fair: <60: poor

**Table 2:** Age incidence

Age (year)	No. of patients	Percentage
20-30	6	30%
31-45	12	60%
46-60	2	10%

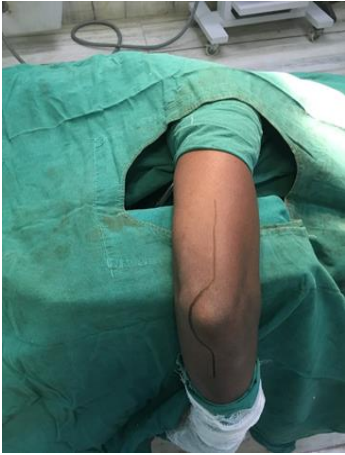**Table 3:** Demographic parameters, sex, side mode of injury

Sex	No. of patient	Percentage
Male	14	70%
Female	6	30%
SIDE		
Right side	8	40%
Left side	12	60%
Mode of injury		
RTA	12	60%
FALL	6	30%
ASSAULT	2	10%

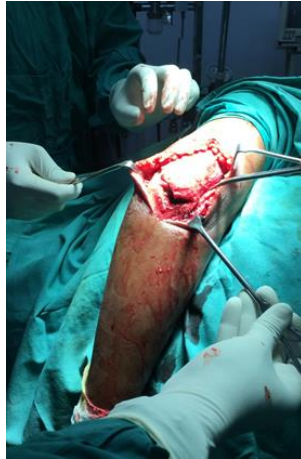

**Graph 1:** showing incidence of fracture, and its outcome

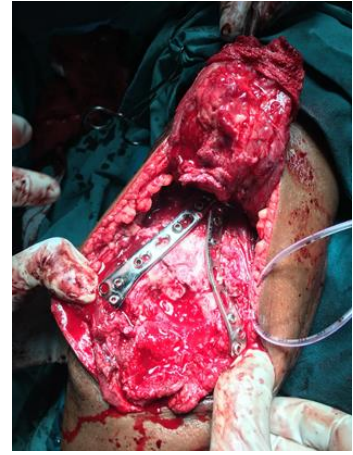**Intra Operative Images**



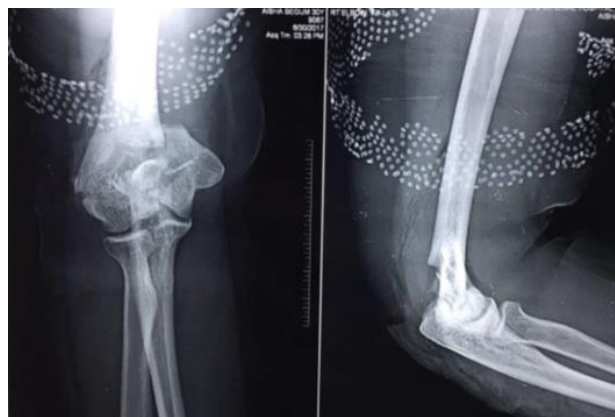**Patient Positioning**



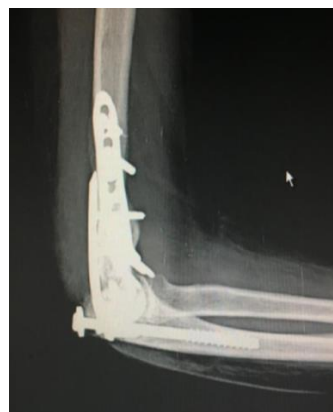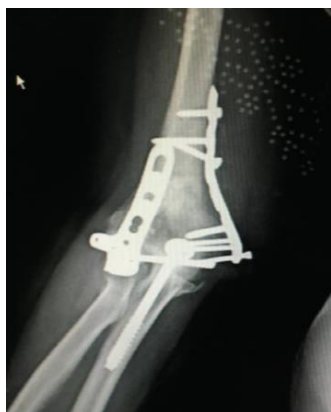**Ulnar Nerve Isolation**



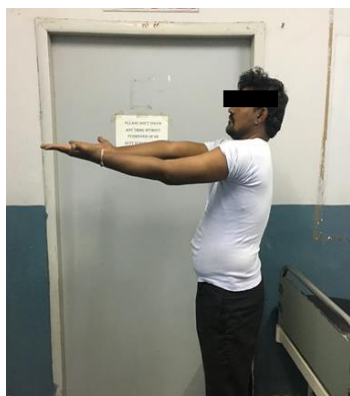**Fracture fixed with Dual Plate**



**Pre-Operative AP and Lateral View**



**Immediate Post op x-ray images**



**Clinical Photograph - Final range of motion at 6 months**



## Discussion

2 – 6% of all fractures are associated with distal humerus fractures, and 30% around elbow. Primary aim of fixation of intra articular distal humerus fracture is to achieve stable and mobile elbow joint. Conservative treatment results in functional impairments and deformities such as osteoarthritis, mal – union and stiffness which are quiet common.

The trend has now shifted to Open Reduction and Internal Fixation to achieve stable fixation and early mobilisation. Proper maintenance of articular surface, stable fixation and early ROM yields better results.

Anatomy of elbow joint poses challenging tasks to a surgeon because of intricate anatomy, sparse neurovascular structures, minimal soft tissue attached to fragments and long operative duration.

In the present study, of the 20 cases taken up for the study, the average age was 38.45 years, and the youngest age was 22 years and the oldest age was 60 years. The male/ female ratio was 7:3. Most of the cases were in the 4<sup>th</sup> decade of age group for they are the working population. Males predominated for they are the predominant working group. In this study, 12 cases sustained left sided injuries, mostly because of reflex mechanism during injury. Fractures sustained in road traffic accident (most common) were more communitated.

In our study all 20 patients were operated with posterior approach using olecranon osteotomy. With all posterior approaches, the ulnar nerve was carefully dissected and secured with umbilical tape. Fracture site reduced temporarily using K – wires, and fixed with standard plating technique of orthogonal plating.

Implant failure and implant loosening is commonly seen with semi tubular plates and reconstruction plates. Precontoured distal humerus locking plates are associated with minimal soft tissue irritation and periosteal stripping and multiple screw slots to give maximum stability to distal humerus. These precontoured locking plates strengthen the bone implant anchorage and hence helps in early fracture union and stable fixation which gives early mobilisation to elbow joint.

Studies by Self *et al.* and Schemitsch *et al.* showed that direct medial and lateral plating is biomechanically sound<sup>[6]</sup>. Sanchez-Sotelo *et al.* listed several principles for distal humeral fracture fixation that we have incorporated into our treatment protocol<sup>7</sup>. Small osteochondral fragments can be fixed with headless screws, countersunk mini fragment screws, or absorbable screws. Our study shows no instability, increased elbow range and early mobilization.

Reising K in their study of 46 consecutive patients concluded that Open reduction and internal fixation with the DHP system provides reliable, stable fixation allowing early functional mobilisation of the elbow joint, even in complex fractures and impaired bone quality, resulting in good outcomes for the majority of patients<sup>[8]</sup>.

Postoperative physiotherapy plays an important role in the outcome. M Dhawan *et al.*<sup>[9]</sup>, studied 108 closed intra articular fractures of distal humerus treated by operative fixation and showed that most of the elbow function was seen to be acquired at three months after the surgery and no improvement was seen after six months in spite of standard physiotherapy.

Newer, minimally invasive, percutaneously inserted bridge plates also have been described and have been used to avoid extensive dissection and potential nerve injury<sup>[16, 17]</sup>.

Olecranon osteotomy provides a good exposure of the fracture site for distal humerus fracture fixation. However, it is not

without its potential disadvantages of delayed union, non-union and other implant related complications. Macko *et al.*, reported elbow symptoms due to prominent k wires in 75 % of their 20 cases and skin breakdown in 20 % of the cases<sup>[10]</sup>. One of the complications of olecranon osteotomy is denervation of Anconeus muscle, which provides dynamic stability to the lateral side of the elbow by preventing varus and posterolateral rotatory instability. Since Bryanand Morrey approach is Anconeus preserving, they do not have this disadvantage.

## Conclusion

Based on our study, it may be concluded that all grades of intra articular fractures of distal humerus requires stable anatomical internal fixation with pre-contoured distal humerus plates. It helps to achieve early fracture healing and stable fixation, to permit early and active post-operative mobilization.

## Reference

1. Athwal GS. Distal Humerus Fractures. In: Rockwood and Green's Fractures In Adults. Ed. Philadelphia: Lippincott Williams & Wilkins. 2010; 7:946-998.
2. Watson – Jones R: Fractures and joint injuries, 6th ed. : Churchill Livingstone, New Delhi, 1993, 2.
3. Kuntz Jr, David G, Baratz ME. Fractures of the elbow. OrthopClin North Am Jun. 1999; 30(1):37-61.
4. Jupiter JB, Neff U, Hoizach P, Ailgower M. Intercondylar fractures of the humerus. An operative approach. J Bone Joint Surg Am. 1985; 67:2623S9
5. Athwal, George S, Rispoli, Damian M, Steinmann, Scott P. The anconeus flap transolecranon approach to the distal Humerus. Technical tricks. J Ortho
6. Campbell's operative Orthopaedics, 12<sup>th</sup> edition, 2013.
7. Sanchez-Sotelo J, Torchia ME, and O'DriscollSW: Complex distal humeral fractures : Internal fixation with a principle-based parallel plate technique. J Bone Joint Surg Am. 2007; 89(5):961-969
8. Reising K, Hauschild O, Strohm PC, Suedkamp NP: Stabilisation of articular fractures of the distal humerus: early experience with a novel perpendicular plate system. 2009; 40(6):611-7. doi: 10.1016/j.injury.2008.12.018.
9. Michael D. McKee, Tracy L. Wilson, Lucy Winston, Emil H. Schemitsch and Robin R. Richards. Functional Outcome Following Surgical Treatment of Intra-Articular Distal Humeral Fractures Through a Posterior Approach. J Bone Joint Surg Am. 2000; 82-A(12):1701-1707.
10. Macko D, Szabo RM. Complications of tension band wiring of olecranon fractures. JBJS Am. 1985; 67:1396-401.
11. Bryan RS, Morrey BF. Extensive posterior exposure of the elbow: A triceps-sparing approach. Clin Orthop Relat Res. 1982; 166:188-92
12. Rakesh Kumar Gupta, Vinay Gupta, Dickey Richard Marak. Locking plates in distal humerus fractures: study of 43 Patients, Chinese Journal of Traumatology. 2013; 16(4):207-211
13. Dr. Gurjinder Singh, Dr. HS Sohal, Dr. Rakesh Sharma, Dr.Jatin Banal and Dr. Jagdish Dhake. Outcome of precontoured locking plate fixation in distal humerus fractures, International Journal of Orthopaedics Sciences. 2017; 3(1):145-148.
14. Virani SR, Sonone S, Dahapute AA, Panda I, Roy KD. Functional Results of Communitated Intra-articular Distal Humerus Fractures Treated with Bicolunmar Plating. J Clin Diagn Res JCDR. 2017; 11(4):01-3.
15. Shaik RB, Reddy VP, Naidu AK. Study of clinical outcome

in intra articular distal humerus fractures treated with dual plating. *Int J Res Med Sci.* 2017; 5:2438-41

16. Livani B, Belangero WD. Osteosynthesis of the humeral shaft fractures, with bridge plate. *Acta Ortopédica Bras.* 2004; 12(2):113-7.
17. Livani B, Belangero WD, Castro de Medeiros R. Fractures of the distal third of the humerus with palsy of the radial nerve: management using minimally-invasive percutaneous plate osteosynthesis. *J Bone Joint Surg Br.* 2006; 88(12):1625.