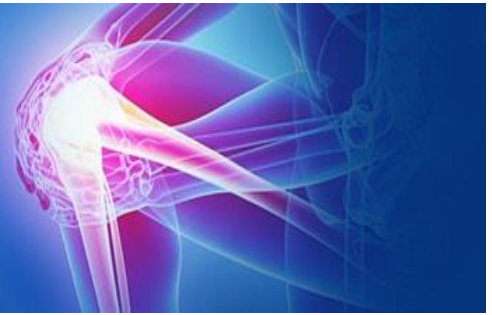

ISSN (P): 2521-3466  
ISSN (E): 2521-3474  
© Clinical Orthopaedics  
www.orthoresearchjournal.com  
2019; 3(3): 33-35  
Received: 20-05-2019  
Accepted: 24-06-2019

**Dr. Umang Agrawal**  
Assistant Professor, Department  
of Orthopaedics, Quarter no. D -  
8, M.P. Shah Medical College  
Campus, Jamnagar, Gujarat,  
India

**Dr. Rahul Parmar**  
Senior Resident, Department of  
Orthopedics, M.K. Thakrar  
Hospital, Porbandar, GEB  
Colony, Porbandar, Gujarat,  
India

## Ultrasound-Guided platelet-Rich plasma (PRP) injection in partial-thickness rotator cuff tear

Dr. Umang Agrawal and Dr. Rahul Parmar

DOI: <https://doi.org/10.33545/orthor.2019.v3.i3a.158>

### Abstract

**Introduction:** The pain and discomfort associated with Rotator Cuff Tear (RCTs) and restriction of shoulder movements can significantly decrease the value of a patient's lifestyle, hindering one from performing daily activities and accomplishing goals as adequately and frequently as one would like. The aim of the study is to evaluate the clinical and ultrasonography changes in the morphology of rotator cuff tendons after ultrasound guided injection of platelet-rich plasma (PRP) for rotator cuff tears.

**Material and methods:** This study is a prospective randomized controlled study which was conducted in the Department of Orthopaedics. PRP injection was done using ultrasonography guide via anterior sub acromial approach. Demographic data were obtained in all patients before the study, and shoulder function was evaluated using the Visual Analogue Scale (VAS) for pain, Quick Disabilities of the Arm, Shoulder and Hand Scale (DASH) score, Oxford shoulder score.

**Results:** Total 87 cases of partial RCTs (diagnosed by USG and MRI) were enrolled in this study. Pre injection mean VAS score, DASH score, OSS score was 6.78, 53.97, 26.48 respectively and post injection at 6 month VAS score, DASH score, OSS score was 0.32, 1.54, 46.8 respectively. Significant improvement was observed after injection. All cases were healed. None case had re-tear.

**Discussion:** Rotator cuff tears are a cause of significant shoulder disability. Surgical repair of rotator cuff tears is complicated by significant re-tear rates and recurrence of symptoms. The use of platelet rich plasma in partial rotator cuff tears may offer a nonsurgical treatment for patients who do not respond to conservative rehabilitation methods. Steroids are available therapeutic agents having short term symptomatic effects but have local and systemic side effects, are costlier compared to PRP and there is the ambiguity of their safety. The critical findings of present study will open up new avenues of research into a better understanding of the role of PRP in RCT.

**Conclusion:** The use of PRP as a minimally invasive treatment option with the prospect of speedier recovery time and less morbidity post-treatment, as opposed to surgical interventions, is thus a highly attractive option and one that ought to be further investigated.

**Keywords:** Partial rotator cuff tear, platelet rich plasma (PRP), vas scale, dash score, OSS score, ultrasound

### Introduction

Rotator cuff tendinopathy (RCT) is a significant source of disability and loss of work. The tendon just proximal to its insertion is prone to tendinopathy degeneration, tears, and rupture. Partial rotator cuff (RC) tears are one of the most common reasons of shoulder pain. The frequency of tears has been shown to increase with increasing age<sup>[1]</sup>.

The management of rotator cuff tears is complex and multifactorial. Partial thickness tears may heal with conservative management and treatment of the predisposing factors. These may include abnormal shoulder biomechanics, debridement of bursae, bony sub acromial spurs, and osteophytes<sup>[2]</sup>. The term PRP may be applied to any fraction of autologous blood, which has a higher concentration of platelet concentration above that of the baseline<sup>[4, 5]</sup>. The centrifugation process allows the separation of blood into its component cells and serum. Depending on the system used, white cells may be removed, resulting in a pure form of PRP termed, preparation rich in growth factors. PRP stimulates the inflammatory response and promotes organized healing (By remodeling and maturation of fibrous tissue).

Platelets are cytoplasmic fragments of megakaryocyte leukocytes, lack nucleoli but contain mitochondria, microtubules, and granules. They have been shown to contain many biological active factors, which promote hemostasis, the synthesis of new connective tissue, and revascularization.

### Correspondence

**Dr. Umang Agrawal**  
Assistant Professor, Department  
of Orthopaedics, Quarter no. D -  
8, M.P. Shah Medical College  
Campus, Jamnagar, Gujarat,  
India

The granules, numbering approximately 50 to 80 per platelet, contain the bioactive proteins, which promote healing termed as growth factors [3].

The main growth factors in the PRP concentrate are transforming growth factor b1 (TGFb), platelet-derived growth factor, vascular endothelial growth factor, hepatocyte growth factor, and insulin-like growth factor 1. These biologically active growth factors work by stimulating angiogenesis, epithelialization, cell differentiation-replication-proliferation, and the formation of extracellular matrix and fibro vascular callus [6, 7]. Besides, platelets have been recognized to be having pain-relieving properties by discharging protease triggered receptor 4 peptides [8].

### AIM

The aim of the study is to assess the role of Ultrasound- guided platelet rich plasma injection in healing of partial-thickness rotator cuff tears and assessment of pain relief and functional outcomes.

### Inclusion Criteria

Degenerative, Partial thickness tears  
Unilateral  
Age 18 - 60  
Willing for follow up

### Exclusion Criteria

H/o Previous shoulder Surgery, injection in last 6 months. DM, RA., Systemic major illness (cardiac, nerves, hematopoietic, renal, hepatic)  
Full thickness tears, Developmental causes  
Anticoagulation Rx, Pregnancy, Metastatic Ds, Thrombocytopenia Allergy to injection

### Materials and Methods

We did a prospective randomized controlled study at our department of orthopedics after ethical clearance and informed consent of all the patients.

We have taken a total of 87 cases of Partial RCT. The selection was based on detectable partial tears with <50% thickness on both magnetic resonance imaging and ultrasonography (USG).

- PRP was prepared using centrifugation technique under all aseptic precautions. Initially, the patient's whole blood was collected with aseptic precautions in sterile tubes. Around 20 ml of patient's whole blood is collected. This whole blood was subjected to centrifugation at 1500 rpm for 15 min at room temperature. The whole blood will separate into three layers. The supernatant layer of plasma and buffy coat were separated and subjected to centrifugation at 3000 rpm (hard spin). In the final end product, the upper two-third of the tube will be containing platelet poor plasma which is removed, and the lower one-third will be PRP enhanced with superficial buffy coat which will be used for injection. The cuff tear size was evaluated using a high-frequency musculoskeletal probe. The procedure initiated with a diagnostic ultrasonogram of the glenohumeral joint. Using a 22-to 25-gauge needle, 2-3 ml of the leukocyte-rich PRP product was injected at the RC tear site, and under ultrasound guidance after painting the patient with betadine and sterilizing the USG probe with betadine and surgical spirit, with patient positioned in sitting position via anterior Subacromial approach. The patients were informed of exaggeration of pain symptom for 2-3 days and advised to avoid NSAIDs and use ice fomentation and physiotherapy

for shoulder twice daily. The injection was repeated at every 2 week interval for a period of total of six weeks. The patients were clinically evaluated every month till 6 months, 1 year and 2 year for ROM (Range of Motion) and physical examination. Radiological evaluation was done by USG to evaluate for tear, tendon thickness. Functional evaluation was done by using the visual analogue scale (VAS) for pain, Disabilities of the Arm, Shoulder and Hand Scale (DASH) score, oxford shoulder score.

### Results

We have M: F ratio 1.55:1. In our study, we have 60 patients injured on dominant side and 27 on the non- dominant side. The difference between Preinjection and Postinjection VAS scores was extremely statistically significant ( $P < 0.001$ ).

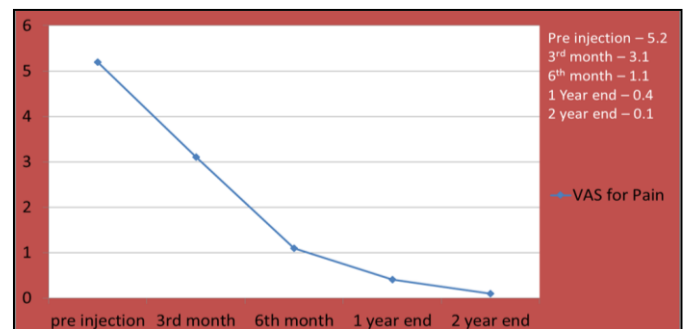

Fig 1: VAS for pain

The Quick dash score showed statistically significant improvement at 8 weeks and 3 months, respectively ( $P < 0.001$ ).

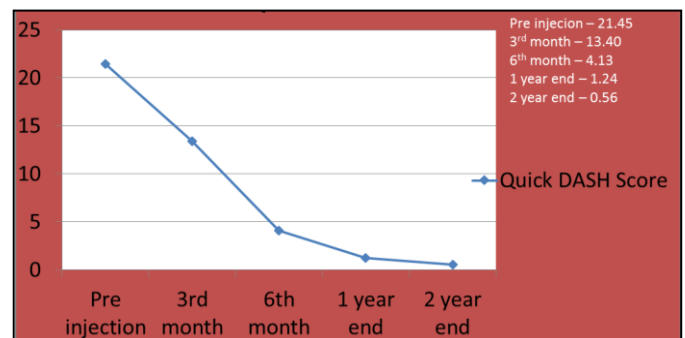


Fig 2: Quick DASH Score

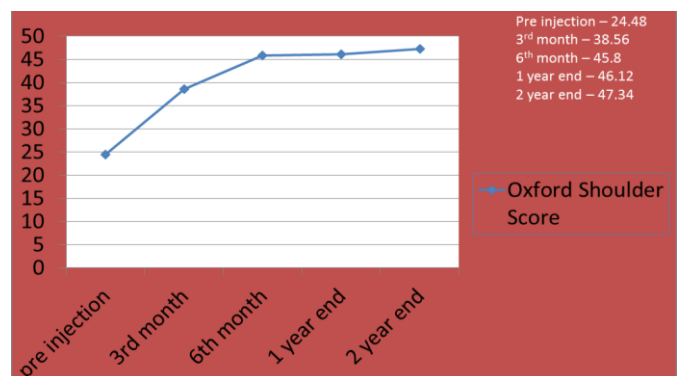


Fig 3: Oxford shoulder score

Pre injection mean VAS score, DASH score, OSS score was 6.78, 53.97, 26.48 respectively and post injection at 6 month VAS score, DASH score, OSS score was 0.32, 1.54, 46.8 respectively.

## Discussion

Rotator cuff tears are a cause of significant shoulder disability. Surgical repair of rotator cuff tears is complicated by significant re-tear rates and recurrence of symptoms. The use of platelet rich plasma in partial rotator cuff tears may offer a nonsurgical treatment for patients who do not respond to conservative rehabilitation methods. PRP is safe & has potential clinical therapeutic effects and longer lasting improvements showing biological and molecular level effects. PRP being autologous & biological, it is safe, well tolerated, cost effective procedure & has less side effects.

Jimenez-Martin *et al.* [9] reported an improved pain score and reduced rehabilitation time when PRP was used in a retrospective cohort comparison and was applied to traditional, mini open, and arthroscopic Subacromial surgery. The exogenous application of platelet leukocyte gel during open Subacromial decompression was thought to contribute to faster recovery, earlier return to daily activities, and less analgesic requirement [10].

Preliminary data suggest that the administration of PRP into injured tissues promotes natural healing mechanisms by release of growth factors and other bioactive substances. This prospective study demonstrates that ultrasound-guided PRP injection resulted in markedly improved clinical, functional, and radiological outcomes. Our study showed a significant change in the reinjection and post injection VAS scores, Quick DASH scores and oxford shoulder score at 8 weeks and 3 months which shows us that the injected product influenced the pain score and functional outcome. Thus, the overall decrease in pain from baseline for group demonstrates that ultra-sonogram-guided injection can be effective in pain control. Little studies are suggesting the effect of ultrasound-guided PRP injection in partial RC tears. Steroids are available therapeutic agents having short term symptomatic effects but have local and systemic side effects, costlier compared to PRP and there is ambiguity of their safety. We feel PRP is a safe & valuable therapeutic option for the armamentarium of the surgeons while managing patients of RCT. The critical findings of present study will open up new avenues of research into a better understanding of the role of PRP in RCT.

## Conclusion

Our study succeeded in demonstrating that patients receiving PRP injections have decreased pain and superior functional outcomes. However, how PRP works on a partially torn RC remains a challenge and deserves ongoing investigation.

The use of PRP has shown to improve healing when compared with standard healing times. We recommend that PRP be used for treatment in randomized prospective controlled studies with a larger sample size so that firm conclusion can be made. More systematic reviews and met analysis will help us to come for a firm conclusion.

The use of PRP as a minimally invasive treatment option with the prospect of speedier recovery time and less morbidity post-treatment, as opposed to surgical interventions, is thus a highly attractive option and one that ought to be further investigated.

## References

1. Seida JC, LeBlanc C, Schouten JR *et al.* Systematic review: non-operative and operative treatments for rotator cuff tears. *Ann Intern Med.* 2010; 15:246–255.
2. Finnan RP, Crosby LA. Partial thickness rotator cuff tears. *J Shoulder Elbow Surg.* 2010; 19:609-616.
3. Harrison P, Cramer EM, Platel *et al.* Pha-granules. *Blood*

Rev. 1993; 7:52-62.

4. Marx RE, Carlson ER, Eichstaedt RM *et al.* Platelet rich plasma: growth factor enhancement for bone grafts. *Oral Surg Oral Med Oral Pathol Oral Radiol Endod.* 1998; 85:638-646.
5. Alsousou J, Thompson M, Huley P *et al.* The biology of platelet rich plasma and its application in trauma and Orthopaedic surgery: a review article. *J Bone Joint Surg Br.* 2009; 51:987.
6. Schnabel LV, Mohammed HO, Miller BJ *et al.* Platelet rich plasma (PRP) enhances anabolic gene expression patterns in flexor Digitorum Superficialis tendons. *J Ortho Res.* 2007; 25:230–240.
7. Sa´nchez M, Anitua E, Azofra J *et al.* Comparison of surgically repaired Achilles tendon tears using platelet-rich fibrin matrices. *Am J Sports Med.* 2007; 35:245-251.
8. Asfaha S, Cenac N, Houle S, Altier C, Papez MD, Nguyen C *et al.* Protease-activated receptor-4: A novel mechanism of inflammatory pain modulation. *Br J Pharmacol.* 2007; 150:176-85.
9. Jimenez-Martin A, Angulo-Gutierrez A, Gonzalez-Herranz J *et al.* Surgery of subacromial syndrome with application of plasma rich in growth factors. *Int. J Shoulder Surg.* 2009; 3:28-33.
10. Everts PA, Devilee RJ, Brown Mahoney C *et al.* Exogenous application of platelet leukocyte gel during open Subacromial decompression contributes to improved patient outcome: A prospective randomised double blind study. *Eur Surg Res.* 2008; 40:203-210.