



ISSN (P): 2521-3466
ISSN (E): 2521-3474
© Clinical Orthopaedics
www.orthoresearchjournal.com
2019; 3(3): 13-17
Received: 09-05-2019
Accepted: 12-06-2019

Dr. Mohammd Ejazul HAQ
Senior Resident, Dept. of
Orthopaedics, Mysore Medical
College and Research Institute,
Mysore, Karnataka, India

Dr. Deepthi KN
Post Graduate, Dept. of
Orthopaedics, Mysore Medical
College and Research Institute,
Mysore, Karnataka, India

Dr. Manjunath M
Assistant Professor, Dept. of
orthopaedics, Mysore Medical
College And Research Institute,
Mysore, Karnataka, India

Dr. Akshay Dhanda
Akshay Dhanda, Post Graduate,
Dept. of orthopaedics, Mysore
Medical College And Research
Institute, Mysore, Karnataka,
India

Dr. Supreeth ER
Post Graduate, Dept. of
Orthopaedics, Mysore Medical
College and Research Institute,
Mysore, Karnataka, India

Correspondence

Dr. Deepthi KN
Post Graduate, Dept. of
Orthopaedics, Mysore Medical
College and Research Institute,
Mysore, Karnataka, India

A prospective study on radiological and functional outcome of Bi-malleolar fractures: A study on 50 cases

**Dr. Mohammd Ejazul HAQ, Dr. Deepthi KN, Dr. Manjunath M,
Dr. Akshay Dhanda and Dr. Supreeth ER**

DOI: <https://doi.org/10.33545/orthor.2019.v3.i3a.153>

Abstract

Introduction: Of all the lower limb fractures ankle fractures are one of the most common accounting for almost 9% with the annual incidence being 107-187 per 1 lakh population. Treatment of this fracture is complicated and challenging as the outcome will influence the locomotive power. Improper and inadequate fixation can cause long term disability as body weight is transmitted through it.

Aim of study: To assess the functional and radiological outcome of displaced bimalleolar ankle fractures and to assess the rate of complications.

Materials and Methods: This prospective study was done at the Department of orthopaedics in K.R. Hospital, Mysuru after obtaining informed consent from patients. A total of 50 patients between the age of 18-50 years were treated with Open Reduction and Internal Fixation with various methods for bimalleolar fracture between August 2017- January 2018; These patients were followed for 12 months and evaluated based on union rate, complications (Infections, Nonunion) and functionally by Baird and Jackson ankle scoring system.

Results: In our study of 50 patients, bimalleolar ankle fractures treated by ORIF by various methods were followed up for 12 months. In our study, majority were males (72%). Mean age group included in the study was 33 years. In majority of patients, the mode of injury was RTA (72%) and most common fracture type being AO Type 44 A (56%). As per Baird and Jackson scoring system excellent to good functional outcome was seen in 78.3% individuals with fair outcome in 17.9% and poor outcome in 5.6%. Complications were seen in 9 patients and only two underwent re surgery for non-union.

Conclusion: We found that ORIF yielded good results in terms of anatomical reduction, stability and post-operative functional outcome. Hence as per our study we can safely conclude that open reduction and internal fixation should be the treatment of choice for all unstable ankle fractures.

Keywords: Bimalleolar fractures, ORIF, association for the study of internal fixation

Introduction

Of all the lower limb fractures, ankle fractures are one of the most common ^[1] accounting for almost 9% ^[2] with the annual incidence being 107-187 per 1lakh population ^[3-5]. These fractures generally affect young men and older women and its commonest below the age of 50 years in men. RTA, twist injuries and fall are the most common cause of ankle fractures ^[5]. Treatment of this fracture is complicated and challenging as the outcome will influence the locomotive power ^[6-7]. Improper and inadequate fixation can cause long term disability as body weight is transmitted through it. As per Paul L Ramsey, 1mm lateral shift in talus produces a decrease of 42% in tibiotalar contact area ^[8]. Hence perfect anatomical reduction is achieved by open reduction and internal fixation. It aims at restoring the joint anatomy and function to maximum, minimize pain and other complications. The superiority of the ORIF over closed treatment has been thoroughly demonstrated in the literature ^[9]. However we have seen that though the fracture is discussed extensively, the treatment varies widely due to differences in classification, reduction techniques and subjective symptoms at follow up.

Patients and methods

This prospective study was done at the Department of orthopaedics in K.R. Hospital, Mysuru after obtaining informed consent from patients. A total of 50 patients between the age of 18-50 years were treated with Open Reduction and Internal Fixation with various methods for

bimalleolar fracture between August 2017- January 2018; these patients were followed for 12 months and evaluated based on union rate, complications (Infections, Nonunion) and functionally by Baird and Jackson ankle scoring system [11]. Fractures of the ankle were evaluated with plain radiographs in antero-posterior, lateral and mortise views. Fractures were classified according to arbeitsgemeinschaft für osteosynthesefragen (AO), (“Association for the Study of Internal Fixation” in English)/orthopedic trauma association system classification [10]. Tibiofibular clear space of >6mm and widening of the medial clear space >4mm were considered indicators of syndesmotic instability.

Materials and Methods

Inclusion criteria

- Displaced/unstable bimalleolar fractures
- Age between 18 to 50 years
- Closed fractures and Gustilo-Anderson’s grade 1 compound fractures
- Fractures less than 1 week old

Exclusion criteria

- Undisplaced bimalleolar fractures
- Pathological fractures
- Gustilo-anderson’s grade 2 and 3 open fractures
- Talar /pilon fractures
- Fractures > 1 week old
- Age less than 25 and greater than 50 years.

All patients were temporarily immobilized with Plaster of Paris slab, underwent routine investigations, obtained anesthetic clearance, analgesics and antibiotics.

Operative technique

Main objective of our surgical treatment is to maintain proper alignment, stable fixation and to address the associated syndesmotic injury.

Under spinal or general anaesthesia, patients were put in supine position. Under tourniquet control and guidance of image intensifier, all lateral malleoli fractures were initially fixed with 1/3 tubular plate/ locking fibular plate. Hook test was done intraoperatively to determine the syndesmotic injury. Syndesmotic injury was addressed with syndesmotic screw.

For lateral malleoli: Vertical incision over the distal fibula of about 8-10 cm and fracture reduced with reduction forceps. A 3.5mm LCP or 1/3 tubular plate applied depending on fracture pattern and surgeon preference with at least 4-6 cortices purchased on either side with proximal and distal screws applied

Fixation of medial malleoli: Curved incision over medial malleoli. Soft tissue dissected and fracture site reduced with pointed reduction forces. The fracture site is temporarily held with guide pin and fixed with malleolar screw or tension band wiring depending on fracture pattern and surgeon preference. Malleolar screw- A 3.7mm hole is drilled over the guide pin and 4.5mm malleolar screw is inserted. Tension band wiring- 2 K wires passed anterior and posterior to guide pin. A unicortical screw is applied at the proximal end of K wire. A 0.8mm SS wire is curved and inserted in figure-of-eight configuration around protruding K wires.

Intra-operatively, all patients received prophylactic IV antibiotic half an hour before surgery. Post operatively, patients were

immobilized with below knee slab and limb elevation.

Post-operative protocol: IV antibiotics for 3 days. Touch down weight bearing was started after three week. Suture removal was done after 10-12 days depending upon healing. Knee mobilization was started immediately. Full weight bearing was withheld until complete radiological fracture union occurred. All patients were assessed serially for 1 year functionally with Baird and Jackson ankle scoring system 4.

Results

In our study of 50 patients, bimalleolar ankle fractures treated by ORIF by various methods were followed up for 12 months. In our study, majority were males (72%). Right sided bimalleolar fractures were more common than left (56%). Mean age group included in the study was 33years. In majority of patients, the mode of injury was RTA (72%) and most common fracture type being AO Type 44 A (56%), the least common being Type 44 B (12%).

Sex of patients

Male	Female	total
36	14	50

Affected side

Right	Left	Total
28	22	50

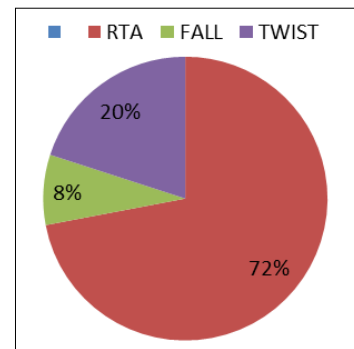


Fig 1: Mode of injury

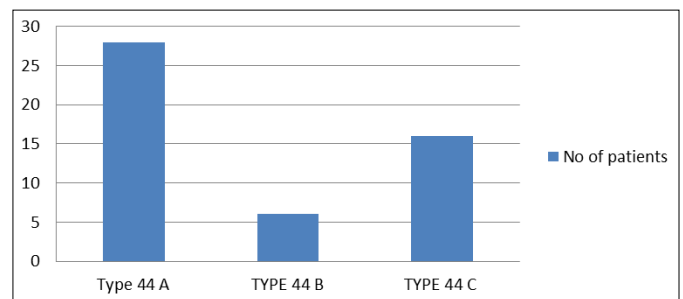


Fig 2: No of patients

The lateral malleoli fractures were fixed with one third tubular plate in 29 patients and locking plate in 21 patients. Syndesmotic injury in 5 patients was treated with Syndesmotic screw. Different methods were used to fix medial malleoli – malleolar screw in 64% and tension band wiring (TBW) IN 36%.

Medial malleoli fixation method

No of cases	Malleolar screw	Tension band wiring
50(100)	32(64)	18(36)

Fracture union was assessed regularly with radiographs taken during follow up and average time for union was 12 weeks. Only 2 patients showed nonunion.

Functional outcome was assessed using Baird and Jackson ankle scoring system with follow up at 8,10,12,14,16 weeks and then at 6 months and 1 year. 28 patients showed excellent functional outcome. Good functional outcome was seen in 10 patients. 3 patients showed poor functional outcome due to nonunion, superficial infection, deep infection. Patients with poor result elicited mild pain in daily activities with decreased ability to work, decreased range of movement and narrowed joint space on radiograph.

In our case series of 50 patients, complications were seen in 9(18%). Superficial infection in 3 and deep infection was seen in 1 patient. All patients were smokers and 1 patient was diabetic. Nonunion of medial malleoli was seen in 2 patients due to inadequate compression at fracture site. Infection was managed with antibiotics and nonunion seen in 2 patients were taken for re-operation.

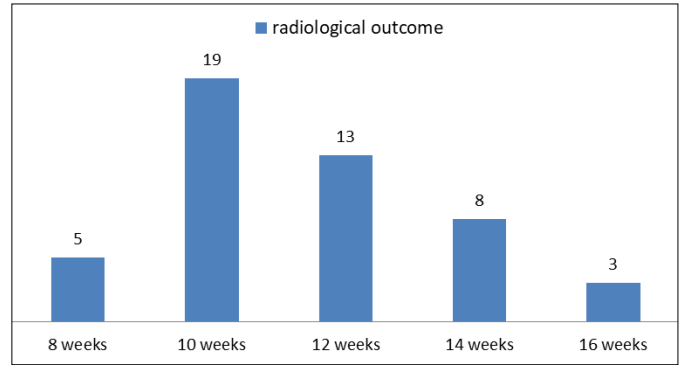
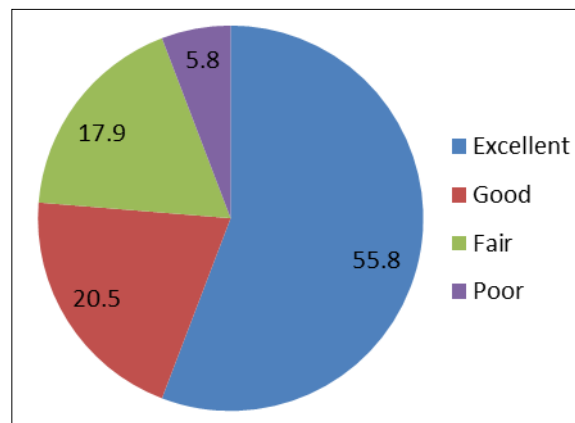


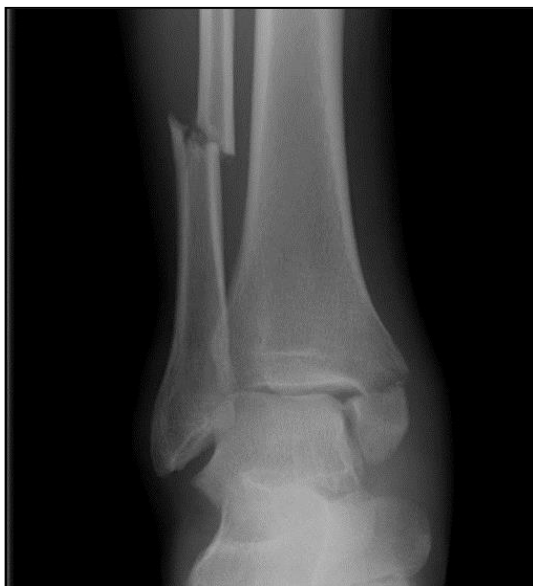Fig 3: Radiological outcome

Different complications

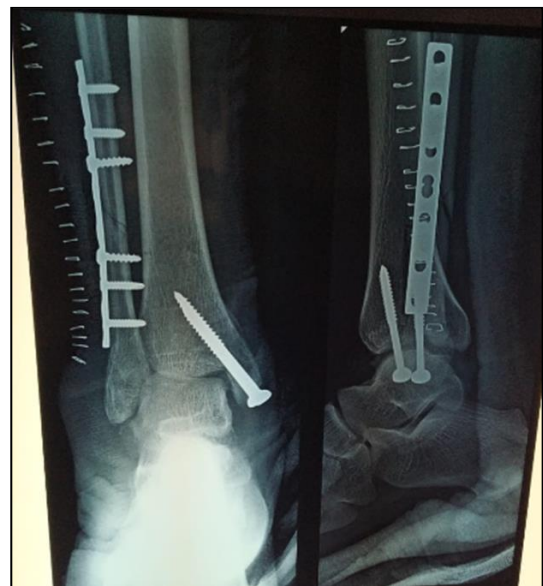Complications	No of patients
Superficial infection	3
Deep infection	1
Non-union	2
Ankle stiffness	3
Total	9



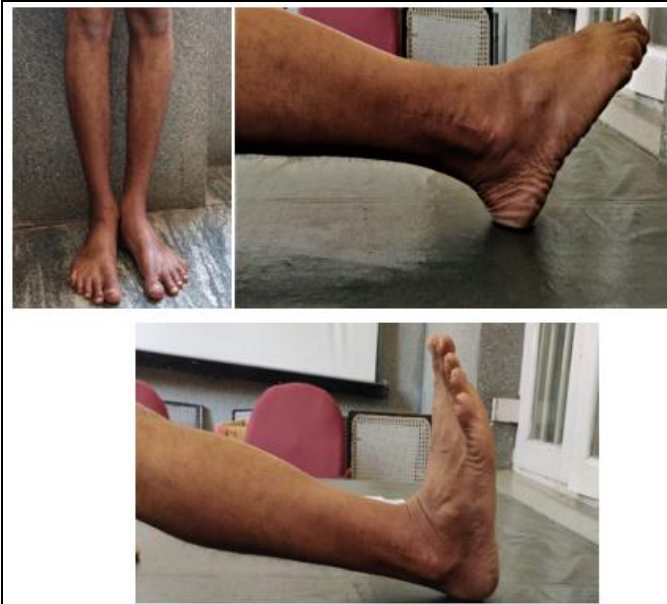Functional Outcome



Pre-op radiograph



Post op



Movements at follow up

Discussion

There has been an increase in the incidence of bimalleolar fractures over the past 2 decades^[4] in young, active and elderly patients. The different treatment modalities are closed reduction and immobilization in POP slab or ORIF. Recent advances have resulted in evolution of management strategies, improved analysis of biomechanics, and improvement in fixation techniques. The main goal of treatment was to provide fracture union and restore normal ankle anatomy with painless and complete range of motion. Closed method of treatment is often inadequate in restoring the anatomy and biomechanics of ankle in unstable/displaced fractures. Several studies have shown that accurate open reduction and stable internal fixation using AO method and principles to give excellent results^[12-14].

In our study of 50 patients, mean age was 37.3 years as compared to previous studies by Motwani *et al.*^[15] - mean age 39.28 years, Kulloli *et al.*^[16] higher mean age of 56.45 years, Maruthi *et al.* - mean age of 28.8 years^[17]. Our study showed male preponderance as compared to study by Baird and Jackson (males -70.0%)^[11] and studies by Indian authors^[15-17].

Road traffic injuries are the frequent cause of ankle fracture^[15, 16], and this is again proven in our study. In contrast, Maruthi *et al.*^[17] report fall as the main cause of fracture, which was the second common cause in our study and in other previous studies^[15, 16]. Right ankle was the most commonly involved joint in our study similar to the previous reports^[15, 17] while; there are reports where in left side was the most commonly involved joint^[16].

In our patients, AO Type B was the most common (66.6%) and least in Type A (6.6%). Other studies like Motwani *et al.* too reported a similar observation^[15, 18, 19].

All 50 patients underwent ORIF. We fixed lateral malleoli fracture first with one third tubular plate or locking fibular plate followed by medial malleoli fixation with malleolar screws in 53.3% patients and tension band wiring in. The syndesmotic injury in 5 patients was fixed with a fully threaded screw. An excellent outcome was seen in two patients, and a good outcome was seen in other three patients. These procedures were done by standard operative techniques as followed by orthopedic surgeons worldwide. According to Hughes, fixation of the lateral malleolus first, often results in minimal post-operative immobilization and rapid improvement in functions^[20].

Time taken for union depends on various factors and has been around 10.4 weeks as reported by Motwani *et al.*^[15] 13 weeks has been reported by Kulloli *et al.*^[16]. Mean time for the union was 10.6 weeks in our study population with a range of 8-14 weeks, which was similar to the study by Motwani *et al.*^[15].

Any successful surgery is measured by the functional outcome. Baird and Jackson grading system to describe the outcome is a well-accepted, adopted method and we categorized the outcome in our patients using this grading system. Greater proportion of our patients had good to excellent (76.3%) outcome compared to reports by Cotton (70.0%),^[21] Beris *et al.* (74.3%)^[7] And Burwell and Charnley,^[12] but lesser than that by de Souza *et al.* (90.0%)^[13] and Maruthi *et al.* (90.0%)^[17]. We reported fair outcome in patients. Poor outcome was reported in considerably lesser percentage (5.8%) in our patients which was similar to the observations of de Souza *et al.* (4.0%)^[13], Burwell and Charnley (6.0%);^[12]. Fair to poor results in our patients can be attributed to wound infection and nonunion of the medial malleolus. Restricted activity level and range of movement without radiological evidence of arthritis were noted in four patients.

In our study the well documented complications were superficial and deep infections, scar tenderness, non-union which have been reported as complications of open reduction by various other studies^[15, 16]. Infections were managed by standard orthopedic protocol which included antibiotics and debridement. Complications that we observed are part of any surgical intervention and we managed successfully without much discomfort to the patients. Only two patients underwent reoperation for nonunion.

Even though the duration of immobilization is debatable, few support early mobilization, while emphasize on immobilization of 4 weeks is for good long-term outcome. We advised partial weight bearing with an observance of early signs of union radiologically and with complete signs of union, full weight bearing was advised. In those with syndesmotic injury, partial weight bearing was delayed till 6-8 weeks. By delaying immediate mobilization, our patients avoided having instability of the joints (ankle and subtalar joint) as the soft tissues around the injured joint had sufficient time to heal. Ankle exercises were started later which may have been a reason for the good outcome.

Conclusion

In our study, we followed 50 patients with unstable bimalleolar fractures who were treated with open reduction and internal fixation. We found that ORIF yielded good results in terms of anatomical reduction, stability and post-operative functional outcome. Fixation of medial malleoli with malleolar screws or tension band wiring (TBW) showed similar results and according to our study one is not superior to the other. After 12 months of follow up most patients experienced excellent and good outcomes with only a few having certain restrictions of functional activities. Hence as per our study we can safely conclude that open reduction and internal fixation should be the treatment of choice for all unstable ankle fractures.

References

1. Lash N, Horne G, Fielden J, Devane P. Ankle Fractures: Functional and Lifestyle Outcomes at 2 Years. *ANZ Journal of Surgery*. 2002; 72:724-730.
2. Court-Brown CM, Caesar B. Epidemiology of Adult Fractures: A Review. *Injury*. 2006; 37:691-697.
3. Court-Brown CM, McBirmie J, Wilson G. Adult Ankle Fractures-An Increasing Problem? *Acta Orthopaedica Scandinavica*. 1998; 69:43-47.

4. Daly PJ, Fitzgerald Jr, RH, Melton LJ, Ilstrup DM. Epidemiology of Ankle Fractures in Rochester, Minnesota. *Acta Orthopaedica Scandinavica*. 1987; 58:539-544.
5. Jensen SL, Andresen BK, Mencke S, Nielsen PT. Epidemiology of Ankle Fractures: A Prospective Population-Based Study of 212 Cases in Aalborg, Denmark. *Acta Orthopaedica Scandinavica*. 1998; 69:48-50.
6. Carragee EJ, Csongradi JJ, Bleck EE. Early complications in the operative treatment of ankle fractures. *J Bone Joint Surg Br* 1991; 73:79-82.
7. Beris AE, Kabbani KT, Xenakis TA, Mitsionis G, Soucacos PK, Soucacos PN. Surgical treatment of malleolar fractures. A review of 144 patients. *Clin Orthop Relat Res* 1997; 341:90-8.
8. Ramsey PL, Hamilton W. Changes in Tibiotalar area of Contact caused by Lateral Talar shift. *J. Bone Joint Surg*. 1976; 58A:356-357.
9. Weber MJ. Ankle fractures and dislocations. In: Chapman MW, Madison M, editors. *Operative Orthopaedics*. 2nd ed., Ch. 50. Philadelphia, PA: JB. Lippincott Company. 1993; 3:731-48.
10. Muller ME, Nazarian S, Koch P, Schatzker J. Tibia/fibula. In: *The Comprehensive Classification of Fractures of Long Bones*. Berlin, Germany: Springer-Verlag, 1990, 148-91.
11. Baird RA, Jackson ST. Fractures of the distal part of the fibula with associated disruption of the deltoid ligament. Treatment without repair of the deltoid ligament. *J Bone Joint Surg Am*. 1987; 69(9):1346-52.
12. Burwell HN, Charnley AD. The treatment of displaced fractures at the ankle by rigid internal fixation and early joint movement. *J Bone Joint Surg Br*. 1965; 47(4):634-60.
13. De Souza LJ, Gustilo RB, Meyer TJ. Results of operative treatment of displaced external rotation-abduction fractures of ankle. *J Bone Joint Surg Am*. 1985; 67(7):1066-74.
14. Cimino W, Ichtertz D, Slabaugh P. Early mobilization of ankle fractures after open reduction and internal fixation. *Clin Orthop Relat Res*. 1991; 267:152-6.
15. Motwani GN, Shah HD, Chavli VH, Daveshwar RN, Parmar H, Suthar PP. Results of open reduction and internal fixation in closed bimalleolar Pott's fracture of ankle in adults. *Int J Med Sci Public Health*. 2015; 4(7):893-900.
16. Kulloli SS, Magdum PB, Naik NP. Evaluation of management of malleolar fractures of ankle joint. *IOSR J Dent Med Sci*. 2012; 3:27-31.
17. V, Venugopal N, Nanjundappa HC, Siddalingaswamy MK. Bimalleolar fracture of ankle joint managed by tension band wiring technique: A prospective study. *Sch J Appl Med Sci*. 2014; 2(1):428-32.
18. Van Laarhoven CJ, Meeuwis JD, van der Werken C. Postoperative treatment of internally fixed ankle fractures: A prospective randomised study. *J Bone Joint Surg Br* 1996; 78(3):395-9.
19. Makwana NK, Bhowal B, Harper WM, Hui AW. Conservative versus operative treatment of displaced ankle fractures in patients over 55 years of age. A prospective, randomized study. *J Bone Joint Surg Br*. 2001; 83(4):525-9.
20. Hughes J. The medial malleolus in ankle fractures. *Orthop Clin North Am*. 1980; 11(3):649-60.
21. Cotton FJ. *Fractures and Joint Dislocations*. Philadelphia, PA: WB Saunders, 1910, 549.