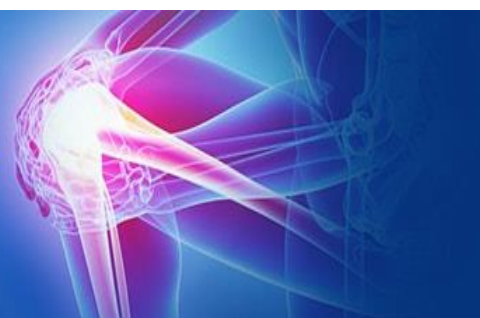



ISSN (P): 2521-3466  
ISSN (E): 2521-3474  
© Clinical Orthopaedics  
www.orthoresearchjournal.com  
2019; 3(1): 119-121  
Received: 05-11-2018  
Accepted: 08-12-2018

**Dr. BLS Kumar Babu**  
Associate Professor, Department  
of Orthopaedics, Narayan  
medical college, Nellore,  
Andhra Pradesh, India

**Dr. K Venkata Siva Dinesh**  
Post Graduate, Department of  
Orthopaedics, Narayan medical  
college, Nellore, Andhra Pradesh,  
India

**Dr. Biju Ravindran**  
Professor & HOD, Department  
of Orthopaedics, Narayan  
medical college, Nellore, Andhra  
Pradesh, India

**Correspondence**  
**Dr. BLS Kumar Babu**  
Associate Professor, Department  
of Orthopaedics, Narayan  
medical college, Nellore,  
Andhra Pradesh, India

## Role of vacuum assisted closure in the management of infected wound in Orthopaedics

Dr. BLS Kumar Babu, Dr. K Venkata Siva Dinesh and Dr. Biju Ravindran

DOI: <https://doi.org/10.33545/orthor.2019.v3.i1c.22>

### Abstract

**Background and Objective:** Wounds are a major source of morbidity, lead to considerable disability, and are associated with increased mortality; therefore, they have a significant impact on public health and the expenditure of healthcare resources. Vacuum-assisted closure (VAC) uses negative pressure to assist wound healing. Negative pressure drains fluid from the wound, thus removing the substrate for growth of microorganisms. Negative pressure may also accelerate granulation tissue formation and promote angiogenesis. The mechanical stimulation of cells by tensile forces may also play a role by increasing cellular proliferation and protein synthesis. Negative pressure wound therapy (NPWT) involves the use of a negative pressure therapy or suction device to aspirate and remove fluids, debris, and infectious materials from the wound bed to promote the formation of granulation tissue.

**Materials and Methods:** A total of 30 post-operative infected wound cases presented in between December 2016 to August 2018 were taken for study. Each case was examined clinically in systematic manner as per the proforma drafted. VAC dressing was done and all cases were followed up to discharge and subsequently for a follow up on 10<sup>th</sup> day.

**Results:** In our clinical study of 30 cases managed by VAC dressing, 30% of the cases were of post-operative infected wounds of radius & ulna, 13.3% humerus, 23.3% femur, 23.3% tibia, 3.3% spine, 3.3% calcaneum, 3.3% metatarsals. By the completion of VAC therapy none of the cases required a revision surgery or implant removal. There is a progression of healthy healing in all the cases (100%). Commonest organisms isolated were Staphylococcus, Pseudomonas and Proteus.

**Interpretation and Conclusion:** In our study VAC therapy enhanced granulation tissue formation leading to better wound healing, and faster recovery. VAC is thus a promising new technology in the field of wound healing with multiple applications in a variety of wounds and can be used in both acute and chronic wounds, salvage procedures or as an adjuvant therapy to improve the results of various surgical procedures.

**Keywords:** Negative pressure wound therapy, VAC, wound healing

### Introduction

Vacuum-assisted closure (VAC) is a new technique in the challenging field of management of contaminated, acute and chronic wounds [1]. Vacuum assisted closure (also called vacuum therapy, vacuum sealing or topical negative pressure therapy) is a sophisticated development of a standard surgical procedure, and involves the use of vacuum to remove blood or serous fluid from a wound or operation site. Negative pressure wound therapy (NPWT) also called vacuum-assisted wound closure and refers to wound dressing systems that continuously or intermittently apply sub-atmospheric pressure to the surface of a wound [2]. The application of controlled levels of negative pressure has been shown to accelerate debridement and promote healing in many different types of wounds. The optimum level of negative pressure appears to be around 120 mmHg below ambient and it is believed that negative pressure assists with removal of interstitial fluid, decreasing localised edema and increasing blood flow [3, 4]. This in turn decreases tissue bacterial levels. Despite the significant costs involved, the technique is said to compare favourably in financial terms with conventional treatments in the management of difficult wounds. In essence, the technique is very simple. It involves application of sterile, open-pore foam dressing directly on the wound. The wound is then sealed with an occlusive drape in order to create a closed, controlled environment. A fenestrated vacuum tube is connected to a vacuum source; fluid is drawn from the wound through the foam into a

Reservoir for subsequent disposal. Negative pressure is applied at 125-150 mm/Hg, resulting in a decrease in the local interstitial pressure, and effluent from the wound is drawn out into the collection device. Initially, the vacuum pressure is applied continuously. As the amount of drainage decreases, the vacuum may be subsequently being applied on an intermittent basis [5, 6]. The vacuum dressing is usually changed at approximately 48-hour interval [7, 8]. Wound progress is recorded using parameters in the wound scoring system. The objectivity of assessments used to generate the wound score make this scoring system ideal for evaluating treatment and outcome of wounds.

### Materials and Methods

Thirty patients were evaluated between December 2016 to August 2018 with post-operative infected wounds. Mean age was 52.7 years (range 32–78 years). In which 17 patients were male and 13 were female. All the cases were followed up to discharge and subsequently for a follow up on 10<sup>th</sup> day. The patients enrolled in this study were underwent following investigations: Complete Haemogram, Random blood glucose, renal function tests, CRP, X- Ray of the affected limb, Culture and sensitivity of the pus/ discharge from the ulcer.

### Procedure

After the confirmation of diagnosis, wound debridement should be done. Regular dressing should be done once in 2 day basis. The wound dressing utilized was medium density polyvinyl alcohol (PVC) sponge [9]. Sponge was provisionally fixed to the wound with a piece of streidrape. The wound is sealed with adhesive steridrape and care is taken that the drape extends at least 5cms beyond the wound edge in all directions. The area where the tube enters should be sealed properly as it prone to leaks. A perforated tube supplied with suction drain is passed through the sponge so that it lies in the middle of the sponge. The tube should not come in contact with the wound or the drape on the surface in order to give best results. The distal end of the drain is collected to the vacuum suction device that provides a negative suction of 125- 150 mmHg. Intermittent negative pressure is applied and turned on for 30 minutes and off for 30 minutes. Due to the application of suction the foam collapses into the wound and the negative pressure absorbs the fluid through the wound [10, 11]. Irrespective of the wound condition, dressing change should be done once in 48hrs. The evidence of wound healing is confirmed by the amount of granulation tissue, culture and sensitivity, CRP and clinical findings [12]. Before the placement of VAC, the initial size of the wound was measured by placing a steridrape over the wound and marking the margins of wound with marker. Later measurement of wound was calculated by considering the maximum length and breadth. The size of the wound before VAC therapy was compared with the size after the VAC. The same procedure was followed after every VAC dressing. Once wound starts healing and shows good granulation tissue, split skin grafting or secondary suturing of the wound was carried out. Cases were followed for 10days after the discharge.

### Follow up

All cases were followed up to discharge and subsequently for a follow up on 10<sup>th</sup> day. Wound healing was excellent in 64% of cases (19) and good in 36% (11) cases.

### Results

The present study consists of total 30 patients with post-operative infected wounds comprises of upper limb (13 cases), lower limb (16 cases) and spine (1 case) in the age group of 32-78 years, while 7% patients were between age group 30-39, 4% patients were between 40-49, 7% were between age group of 50-59 years and 9% were more than 60 years of age. The youngest patient was 30 years and oldest patient was 78 years. The average age of patient was 52 years. In this study majority were male 17 (70%) patients and 13 (30%) female patients. In this study, VAC dressing was applied for 4 days (5 cases, 16.6%), 6 days (10 cases, 33.3%), 8 days (7 cases, 23.3%), 10 days (3 cases, 10%). The number of VAC dressings required for wound closure was less than 4 in 76.6% (15) of cases and more than 4 dressings in 23.4% (7) cases. The mean wound size before the application of VAC therapy was 56% which was reduced to a mean of 44% by end of VAC therapy. Wound closure was achieved by secondary suturing in 57% (17) of the cases and by split skin grafting in 43% (13) of the cases. Wound healing was excellent in 64% of cases (19) and good in 36% (11) cases.

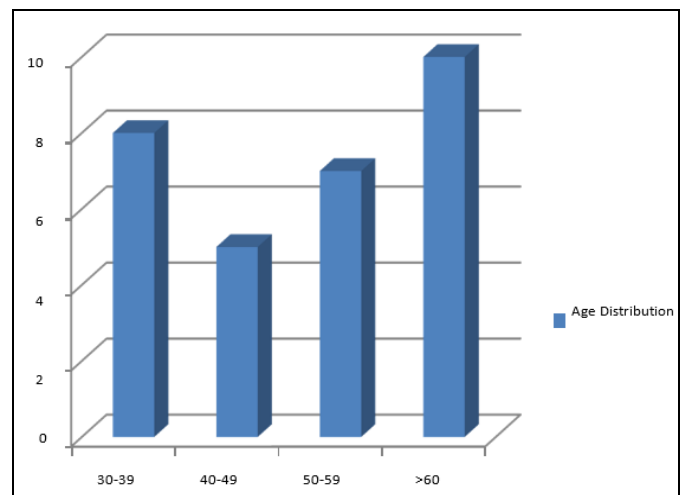


Fig 1: Age distribution

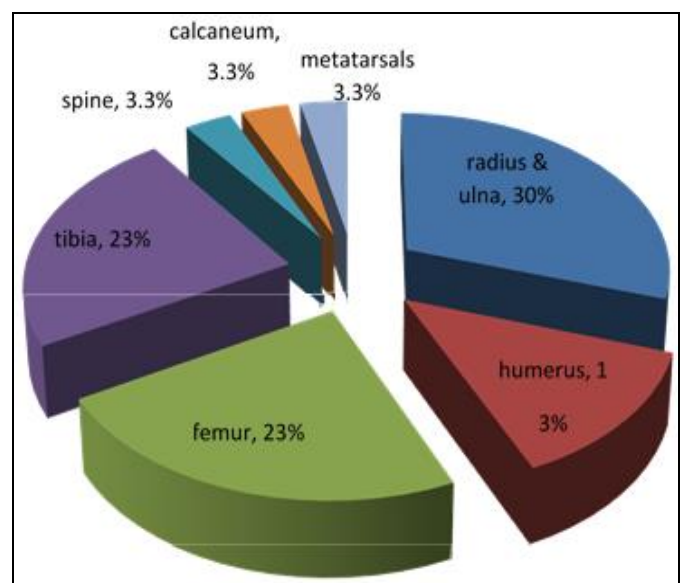


Fig 2: Distribution of Cases

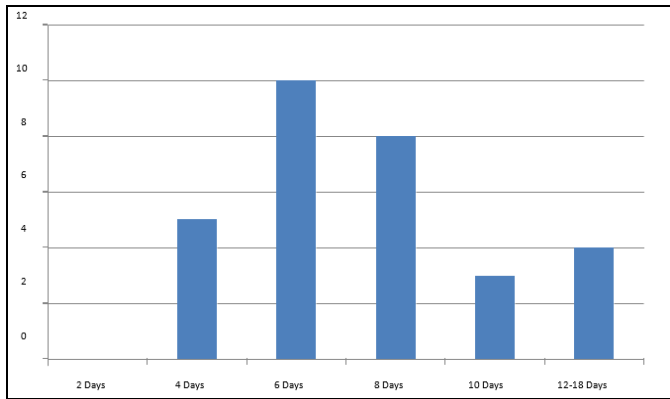


Fig 3: Total duration of VAC therapy

### Discussion

In Orthopaedics, after the implant surgery the surgical site infection is a disaster for both the patient and the surgeon. This leads to prolonged hospital stay, increased use of antibiotics, repeated debridement's, prolonged rehabilitation and may results in morbidity and mortality [13, 14]. Initially Negative pressure wound dressing was introduced for the management of sub-acute and chronic wounds. As the results were so encouraging, its application in the management of wounds was rapidly increased. Present, VAC therapy is used on almost every wounds [15].

In the current study, we have 30 patients with post-operative infected wounds, who were treated with Negative pressure wound therapy and all patients were followed up to discharge and on 10<sup>th</sup> day.

The results in current study were compared with that of Burkhard Lehner *et al.* [16], Jens Klen *et al.* [17], Hyun Joo Lee *et al.* [18].

In the study of Burkhard Lehner *et al.* [16] the mean dressings were 3.5 ranging from 1-8 dressings, and the mean duration of the treatment with VAC dressing was 16.3 days ranging from 9-46 days, with a mean hospital stay of 39.5 days ranging from 12-97 days.

The wound size in this study is closely comparable to the study of Hyun Joo Lee *et al.* [18] where the wound size prior to VAC therapy was 56.4 cm<sup>2</sup> which is reduced to 42.9 cm<sup>2</sup> by the completion of treatment.

The functional results of the present study were comparable with that of the above mentioned studies with 64% had excellent results, 36% had good results with no poor results in 5% patients.

### Conclusion

VAC therapy has been proved as a reliable method for treating a variety of post-operative infected wounds. It accelerates the wound healing by lowering the bacterial count and increasing the rate of granulation tissue formation. It can be used as a definitive treatment for non-surgical and surgical wounds or as a temporary dressing to prepare wounds optimally prior to closure. Because of its success it is even used in a multitude of clinical settings, including the treatment of traumatic wounds, infected wounds, surgical wounds, venous stasis wounds, pressure ulcers and diabetic foot ulcers. VAC is playing an ever expanding role in wound care and it is well tolerated device with few complications and contra indications.

### References

1. Hunter JE, Teot L, Horch R *et al.* Evidence based medicine: vacuum assisted closure in wound care management. *Int.*

*Wound J.* 2007; 4(3):256-69.

2. Moues CM, Vos MC, Bemd GJ van den *et al.* bacterial load in relation to vacuum assisted closure wound therapy: a prospective randomised trail. *Wound Repair Regen.* 2004; 12:11-17.
3. Lazarus GS, Cooper DM, Knighton DR *et al.* Definitions and guidelines for assessment of wounds and evaluation of healing. *Arch Dermatol.* 1994; 130(4):489-93.
4. Jerome D. Advances in neggative pressure wound therapy: the VAC instill. *J Wound Ostomy Continence Nurs.* 2007; 34(2):191-94.
5. Orgill DP, Bayer LR. Update on negative pressure wound therapy. *Plastreconstr Surg.* 2011; 127(1):105S-115S.
6. Weed T, Ratliff C, Drake DB. Quantifying bacterial bioburden during negative pressure wound therapy: does the wound VAC enhance bacterial clearance? *Ann Plast Surg.* Discussion. 2004; 52:276-9, 279-80.
7. Ranjeet N, Dy AU. Jr. Modified negative pressure wound therapy (modified NPWT): An experience of 128 cases. *Nepal Journal of medical Sciences.* 2012; 1(2):108-14.
8. Leong M, Phillips LG, Wound Healing, Townsend CM, Beauchamp RD, Evers BM *et al.* Sabiston Textbook of Surgery. 19<sup>th</sup> ed. Philadelphia; Elsevier, 2012, 151-77.
9. Barbul A, Efron DT. Wound healing. *BrunicardiFC. Schwartz Principles of Surgery.* 9<sup>th</sup> ed. New York. McGraw Hill, 2010, 209-33.
10. Dedmond BT, Kortesis B, Pungner K *et al.* Subatmospheric pressure dressings in the temporary treatment of soft tissue injuries associated with type III open tibial shaft fractures in children. *J Pediatr Ortho p.* 2006; 26:728-32.
11. Borgquist Ola. Ingemansson, Richard; Malmsjo, Malin; wound edge microvascular blood flow during negative pressure wound therapy: Examining the effects of pressures from -10 to -175 mmHg; *plastic &reconstructive surgery.* 2010; 125(2):502-509.
12. Wackenfors A, Sjogren J, Gustafsson R, Algotsson L, Ingemansson R, Malmsjo M. Effects of vacuum- assisted closure therapy on inguinal wound edge microvascular blood flow. *Wound Repair Regen.* 2004; 12:600-6.
13. Erba P *et al.* Angiogenesis in wound treated by micro deformational wound therapy. *Ann Surg.* 2011; 253(2):402-409.
14. Brandi C, Grimaldi L, Nisi G *et al.* Treatment with vacuum-assisted closure and cryo-preserved homologous de-epidermalised dermis of complex traumas to the lower limbs with loss of substance, bones and tendons exposure. *J plast Reconstr Anesthet Surg.* 2008; 61(12):1507-11.
15. Delaat EH. Van Den faster wound healing with topical negative pressure therapy in difficult to heal wounds: a prospective randomized control. *Ann Plast Surg.* 2011; 67(6):626-31.
16. Led trail Boogaard MH, Spaauwen PH, van Kuppevelt DH, van Goor H, Schoonhoven L. Burkhard Lehner *et al.* First experiences with negative pressure wound therapy and instillation in the treatment of infected orthopaedic implants: a clinical observational study. *International Orthopaedics (SCIOT).* 2011; 35:1415-1420.
17. Hyun-Joo Lee, Joon Woo Kim<sup>1</sup>, Chang Wug Oh, Woo Kie Min, Oog Jin Shon, Jong Keon Oh *et al.* Negative pressure wound therapy for soft tissue injuries around the foot and ankle. *Journal of Orthopaedic Surgery and Research.* 2009; 4:14.
18. Jens Kelm, Eduard Schmitt, Konstantinos Anagnostakos. Vacuum-assisted closure in the treatment of early hip joint infections. *Int. J Med Sci.* 2009; 6(5):241-246.