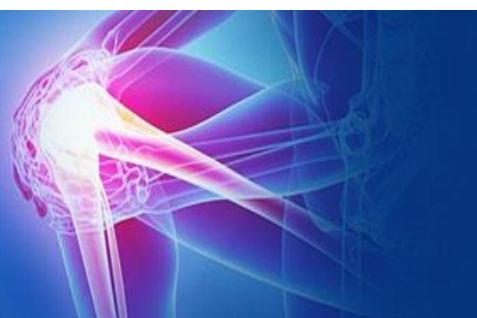



ISSN (P): 2521-3466
ISSN (E): 2521-3474
© Clinical Orthopaedics
www.orthoresearchjournal.com
2018; 2(3): 21-23
Received: 08-03-2018
Accepted: 18-05-2018

Dr. Shivakumar Kerakkanavar
Associate Professor, Department
of Orthopaedics Rajarajeshwari
Medical College Bangalore,
Karnataka, India

Dr. Ullas Mahesh
Assistant Professor, Department
of Orthopaedics Rajarajeshwari
Medical College Bangalore,
Karnataka, India

Dr. Anil Patil
Assistant Professor, Department
of Orthopaedics Rajarajeshwari
Medical College Bangalore,
Karnataka, India

Dr. Pramod Kumar
Assistant Professor
Department of Orthopaedics
Rajarajeshwari Medical College
Bangalore, Karnataka, India

Correspondence
Dr. Ullas Mahesh
Assistant Professor, Department
of Orthopaedics Rajarajeshwari
Medical College Bangalore,
Karnataka, India

Study of functional outcome after arthroscopic repair in recurrent traumatic anterior dislocation of shoulder

Shivakumar Kerakkanavar, Dr. Ullas Mahesh, Dr. Anil Patil and Dr. Pramod Kumar

Abstract

Introduction: Shoulder is a ball and socket type of joint, having wide range of motion with relative deficient support. Traumatic damage leads to laxity in the soft-tissue and bony restraints; thus, recurrent subluxation and dislocation ensue.

Discussion: Arthroscopic Bankart repair has many advantages compared to the open technique. It offers a minimally invasive approach with less surgical trauma and blood loss. Postoperative recovery and rehabilitation is faster. Postoperative range of motion is also not sacrificed for the sake of stability.

Conclusion: Our patients expressed a high degree of satisfaction with arthroscopic Bankart repair. Satisfactory range of motion, especially external rotation that allows proper functioning during sports and activities of daily living, is high on the priority list for these patients.

Keywords: Arthroscopic, Bankart repair, Instability

Introduction

Shoulder is a ball and socket type of joint, having wide range of motion with relative deficient support. Because of this the bony ball of the shoulder joint is driven or pulled out of the socket easily also known as a glenohumeral dislocation. Shoulder is a most common joint dislocated in the body. Normal shoulders have a certain degree of laxity due to minimal bony restraint of the joint, which in turn allows the widest range of motion than any other joint in the body. The result is a tremendous need for competent soft-tissue balance and control. Traumatic damage leads to laxity in the soft-tissue and bony restraints; thus, recurrent subluxation and dislocation ensue.

Each time shoulder slips out of place, it takes less and less force to drive it out. Eventually, many people feel instability in day today activities. Instability is the ongoing sensation of the shoulder continuing to slip out of socket. After that initial injury, gradually patient experiences "dead-arm" syndrome. Dead-arm syndrome indicates pathologic anterior instability and occurs when the arm is in an abducted, externally rotated position. Alternatively, some people will only feel that uneasiness in certain positions, like with their arm overhead; and they will avoid that position to avoid the feeling that their shoulder will dislocate. People under 30 years old are very likely to go on to have recurrent, repeated dislocations. The younger, even greater the likelihood. Despite the low chance of developing instability after the initial dislocation for older people, this same group, unfortunately, will commonly tear their rotator cuff at the same time they dislocate their shoulder.

AIMS & Objectives

1. To evaluate patients having anterior shoulder instability clinically, radiologically and by arthroscopy.
2. To evaluate the outcome of open bankarts repair after arthroscopic shoulder stabilization.
3. To achieve full shoulder range of movement, maximize upper extremity strength, maximize neuromuscular control and initiate functional training.

Materials and Methods

From 2 years, 37 patients underwent arthroscopic Bankart repair for anterior glenohumeral instability by a single surgeon at our institution. Three patients underwent bilateral bankart repairs. Hence, there were a total of 40 shoulders operated on. The patients having minimum 2 episodes of dislocation in previous one year offered surgical arthroscopic treatment.

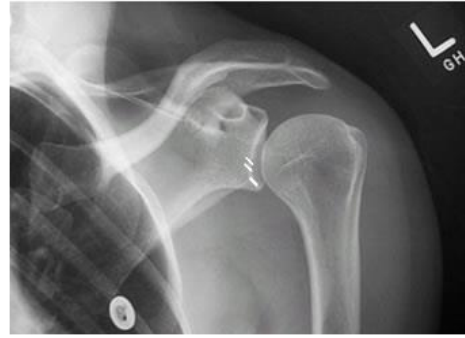Inclusion Criteria

1. Recurrent anterior glenohumeral subluxation or dislocation after the initial episode of traumatic anterior shoulder dislocation,
2. Bankart lesion confirmed by arthroscopic examination.

Exclusion Criteria

1. Posterior instability,
2. Multidirectional instability,
3. Hill-Sachs lesions more than 25% of the humeral head and bony Bankart lesion more than 25%,
4. Previous shoulder surgeries and
5. Patients with mental illness.

Out of 37 patients 17 patients came with acute dislocation, 9 were reduced under sedation, remaining 8 patients required general anesthesia for shoulder reduction. After shoulder reduction, universal shoulder immobilizer advised until surgery. These patients were counseled for diagnostic shoulder arthroscopy and sos bankart repair.



Results

There were 37 patients, 30 were male patients out of which 3 patients were having bilateral instability and remaining 7 were female therefore forming total 40 shoulder instability cases. 24 cases were right shoulders and 16 were left shoulders. The mean age at the time of surgery was 26.75 (range 18–39) years. 22 out. The aetiology of traumatic dislocation was sports in 57% of cases (Fig. 1). The mean number of dislocations before surgery was 5.6 times. The mean interval from the initial dislocation and surgery was 4.02 years. The mean duration of surgery was 86.68 minutes. The mean duration of follow-up was 12 months. The operative findings are summarised in Discussion. Excluding recurrent instability, there were no intraoperative complications related to the arthroscopic procedure with regard to nerve injuries, compartment syndrome, or infection. No neurological compromise was detected in all patients at the latest follow-up.

The mean postoperative shoulder scores were significantly improved at the time of the final follow-up. The total SST score improved from a mean and standard deviation (SD) of 5.27 ± 3.82 (range 0–11) preoperatively to 11.22 ± 1.68 (range 6–12) postoperatively ($p < 0.05$). The total UCLA score improved from a mean and SD of 20.15 ± 4.03 (range 12–28) preoperatively to 32.07 ± 4.82 (range 14–35) postoperatively ($p < 0.05$). According to the UCLA scoring system, 37 shoulders had excellent or good scores (92.5%), one had a fair score (2.5%) and two had poor scores (5%). All patients demonstrated a good range of motion, including external rotation postoperatively. The mean and SD of degree of external rotation was $81.38^\circ \pm 4.93^\circ$. Two patients, one of whom had both shoulders operated on, had recurrent instability postoperatively. The failure rate was 7.5% (three of 40 shoulders). We were unable to identify the reasons for failure in these two patients.

At final follow-up, 85% of cases returned to sports. Most of them returned to their prior sport at the same level of competition. The remainder had not resumed their sports activities because of either recurrent instability or phobia of recurrence. The patients rated their level of satisfaction with the use of the UCLA shoulder score. Preoperatively, no patient rated that he was satisfied; postoperatively, the mean and SD score of satisfaction was 4.63 ± 1.33 with range 0–5 ($p < 0.05$).

Discussion

Arthroscopic Bankart repair has many advantages compared to the open technique. It offers a minimally invasive approach with less surgical trauma and blood loss. Postoperative recovery and rehabilitation is faster. Postoperative range of motion is also not sacrificed for the sake of stability. Patients are able to have a good range of motion functionally, especially external rotation which allows them to return to their sports or high-demand jobs. 150 With modern techniques of arthroscopic Bankart repair continuing to evolve and improve, results of this technique are fast catching up with that of the open technique. The

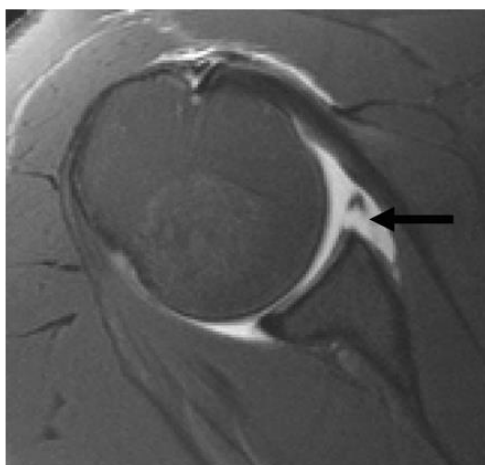
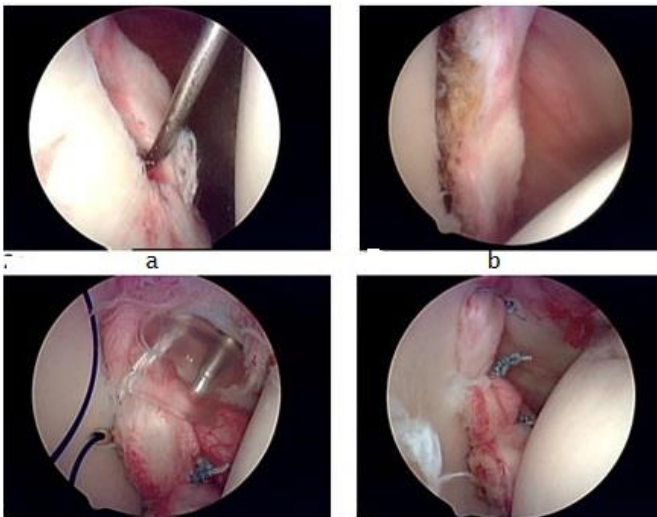


Fig 1: MRI axial section showing Bankart lesion

introduction of bioabsorbable suture anchors simplifies any revision surgery and reduces concerns about infected implants and anchor migration leading to articular cartilage damage. During surgery, either two or three titanium suture anchors are inserted, depending on the size of the Bankart lesion. When the Bankart lesion is small, two instead of three suture anchors suffice. Patients who had only two suture anchors did not have a higher rate of recurrence. They have been shown to be adequate in such situations, unlike some studies which insist on the use of three anchors for all patients. 92 Our patients with anteroinferior capsular laxity were of mild or moderate degree. Although studies have shown that the presence of capsular laxity may affect the outcome of arthroscopic stabilisation, 150 we do not consider Bankart lesions associated with capsular laxity a contraindication to arthroscopic surgery. On the contrary, capsular plication can be done arthroscopically to address the issue of anteroinferior capsular laxity and this significantly augments the stability achieved with Bankart repair. All our patients are young, physically active males age ranging from 18-39 years with mean age 27 year, who engage in vigorous sports or high-demand jobs. But most of the studies, 1, 10 including Hovelius L, Augustini BG, Fredin H, et al have studied and concluded that typical patient with a high risk of developing recurrent instability is a man, either in his teenage years or early twenties. In our study the first episode of acute shoulder dislocation is invariably painful and traumatic (sports injury, road traffic accident, fall and assault) in 90% of cases and remaining 10 % of cases it is due to epilepsy. Subsequently, it is found that they sustain recurrent shoulder dislocation with increasing ease, even during performing tasks of daily activities, i.e. reaching for overhead objects, stretching, sleeping. The recurrence sustained varies from multiple subluxations to frank dislocations. This proves to be a significant morbidity for many of them whose sporting activities or occupations are seriously affected. Carew-McColl M, 6 Segal D *et al.* 8 have documented similar incidence and course of the disease.

In study by James E. Voos, MD, Ryan W¹⁵² The average time between initial instability event and surgery was 3.9 years. But in our study it is very close to this i.e 4 years. In our study 37 (92.5%) patients showed positive for apprehension test and 38 (95%) were positive for Release test. This is correlating with Anthony Tzannes and George A.C. Murrell⁹⁷ and Adam *et al.* On doing investigation in the form of X-ray (anterior posterior view and axillary lateral view) and MRI, X-ray demonstrated findings suggestive of anterior shoulder instability in 4 (10%) patients, and MRI showed lesions suggesting anterior instability in 23 (57 %) shoulders whereas Michel *Et al.*¹⁵⁵ concluded that overall accuracy of MRI in anterior shoulder instability is 79% Baker CL, Uribe JW, Whitman C,⁵⁶ Taylor DC, Arciero RA⁵⁷ have studied that The Bankart lesion, with avulsion of the anterior capsulolabral complex inferior to the equator of the glenoid, is essential lesion of anterior traumatic dislocation of the shoulder. This lesion is almost invariably present in our patients with traumatic instability, on arthroscopic evaluation.

In our study there were 34(80%) patients had Hillsachs lesion but Yiannakopoulos CK *et al.* 156 documented the incidence of Bankarts lesion up to 93 % of in anterior shoulder instability patients. A bony Bankart lesion, or avulsion of the anterior glenoid rim, has been associated with recurrent shoulder instability and has been noted to occur in 5% to 56% of patients. 157 Most frequently, these fractures occur in the anteroinferior aspect of the glenoid rim in our study there were 13 (32%) patients had bony bankart lesion. There were no intra-operative complications we encountered although arthroscopic

neurovascular injury¹⁴⁰⁻¹⁴¹ adhesive capsulitis¹⁴² and synovial fistula¹⁴³ have all been encountered.

We also did not encounter pull-out of suture anchors after repair as documented by Koss S¹³⁹ in their 2 to 5 year follow up study of bankart repair with suture anchors.

Our patients expressed a high degree of satisfaction with arthroscopic Bankart repair. Satisfactory range of motion, especially external rotation that allows proper functioning during sports and activities of daily living, is high on the priority list for these patients. A good range of motion is considered more important than just stability alone. Several other studies published also reported a good range of motion achieved after arthroscopic repair, and were even better than those achieved after open repair. The failure rate in our study was 7. 5% there were total 3 patients experienced recurrence of anterior instability, 2 were had <39 Row & Zarins score and 1 had 45 score but started sporting early causing repeat trauma to shoulder. These statistics were similar to other published studies. Gartsman *et al.* 150 reported a failure rate of 7.5%. Similarly, Ide *et al.* 158 reported a 7% failure rate after performing arthroscopic Bankart repair in a young, athletic group of patients. Our results also compare favourably to those of open Bankart repairs. This is in line with recent studies comparing open and arthroscopic Bankart repairs. 105, 147, 159

Arthroscopic Bankart repair is a reliable method to treat anterior glenohumeral instability. This method is able to yield a good clinical outcome in terms of excellent postoperative shoulder motion and low recurrence rate.

Summary and Conclusion

In an attempt to summarize this study which has been a thorough Arthroscopic Evaluation and Management of Anterior Shoulder Instability. Arthroscopic Bankarts repair with titanium suture anchor is better procedure in terms of patient compliance, recurrence.

On comparing X ray and MRI, diagnostic arthroscopy has high sensitivity and specificity in identifying pathologic lesions involved in anterior shoulder instability. Intraoperative, there is least probability of complications like axillary nerve injury, blood loss and infection.

Our patients expressed a high degree of satisfaction with arthroscopic Bankart repair. Satisfactory range of motion, especially external rotation that allows proper functioning during sports and activities of daily living, is high on the priority list for these patients.

The failure rate in our study was 7.5%. In conclusion, arthroscopic Bankart repair is a reliable method to treat anterior glenohumeral instability. This method is able to yield a good clinical outcome in terms of excellent postoperative shoulder motion and low recurrence rate.

Reference

1. Rowe CR. Prognosis in dislocations of the shoulder. *J Bone Joint Surg [Am]* 1956; 38A(5):957-977.
2. Garth WP, Allman FL, Armstrong WS. Occult anterior subluxations of the shoulder in noncontact sports. *Am J Sports Med.* 1987; 15:579-585.
3. Neer C. II. Involuntary inferior and multidirectional instability of the shoulder etiology, recognition and treatment. *AAOS Instr Cour Lect.* 1985; 34:232-238.
4. Protzman RR. Anterior instability of the shoulder. *J Bone Joint Surg.* 1980; 62-A:909-918.
5. Rowe CR, Zarins B. Recurrent transient subluxation of the shoulder. *J Bone Joint Surg [Am].* 1981; 63:863-872.