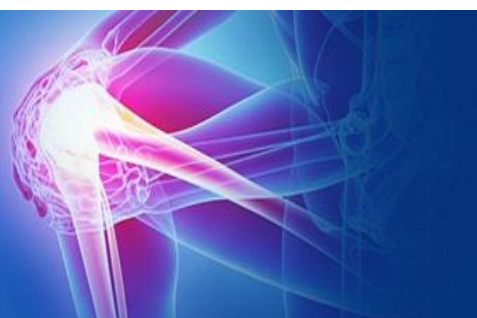



ISSN (P): 2521-3466
ISSN (E): 2521-3474
© Clinical Orthopaedics
www.orthoresearchjournal.com
2018; 2(1): 06-10
Received: 12-11-2017
Accepted: 15-12-2017

Dr. Raja Rathnam Korani
Civil Surgeon Specialist, District
Head Quarters Hospital, Tandur,
Vikarabad, Telangana, India

Diaphyseal humeral fractures: A prospective study on the functional outcome of surgical treatment by open reduction and internal plate fixation technique

Dr. Raja Rathnam Korani

Abstract

The present study was conducted in the Department of Orthopaedics, Osmania Medical College, Hyderabad, Telangana, India. The study series comprised of 12 adult patients with acute diaphyseal humeral fractures treated surgically by open reduction and plate fixation technique following Henry's anterior approach. The basic aim was to get rigid union of the fracture and full normal range of movements to perform normal every day activities. The series consisted of 10 male and 2 female cases with an average age of 40 yrs (25-66 yrs). Out of 12 cases, 1 (8.3%) had post-traumatic radial nerve palsy with wrist drop. 11 cases underwent surgery within the first week after admission, and all the patients were followed up post-operatively for 1 – 6 months. The functional outcome results were recorded using Constant and Murley score along with other parameters like union rates and complications. The functional outcome results were excellent/ good in 12(%) patients with active joint mobility. Complication of radial nerve palsy was observed in 1(8.3%) patient post-operatively however, it improved after conservative treatment with neurotrophic drugs and normal function was restored in 6 weeks after surgery. No long-term radial nerve paralysis occurred. No patient developed non-union after the open reduction and internal fixation and no complications were observed in this study. The present study results indicate that open reduction and plate fixation technique offers a safe and reliable method of fixing fractures of upper humeral shaft in adults. This method provides early fracture union, high union rates and low rate of complications, with excellent / good functional results.

Keywords: Humeral diaphyseal fractures, dynamic compression plate, open reduction, plate fixation.

Introduction

Fractures of shaft humerus are those fractures which lie distal to the surgical neck of the humerus and proximal to the supra-condylar ridge distally. These are commonly encountered injuries by orthopaedic surgeons, with an overall incidence of nearly 1-2% of all fractures of the human body and 14% of all fractures occurring in humerus.

Due to rapid increase in population, number of vehicles, industrialisation and mechanisation of human life, the humerus is fractured by muscular action probably more frequently than any other long bone, hence the incidence of fracture of the humerus is immensely increased. These occur in all the age groups with equal incidence in both the genders, while in the elderly, higher incidences are seen among the females.

Fractures of the shaft of the humerus are usually easy to treat, no matter whether they are spiral, oblique, transverse or comminuted because the blood supply is so vigorous that the union is rapid within about 6 weeks^[1].

It was many years ago that the fractures of the shaft of humerus were high on the list of injuries associated with delayed union and non-union; reversing this tendency with improved methods of closed treatment. Numerous methods are available today to allow selection of the treatment of choice. The shaft of the humerus fracture has a wide range of therapeutic options. The type and level of the fracture, patient's age and ability to cooperate, the degree of fracture displacement and presence of associated injuries are the factors that influence the choice of treatment.

This fracture can be treated either conservatively using functional braces / plaster support or surgically^[2]. Most non-operative treatments such as traction by hanging casts, sling and swathe, velpeau or thoracic-brachial cast, and plaster splints are generally successful in obtaining union. Sarmiento *et al.*^[3] evidenced the benefits of conservative treatment with

Correspondence

Dr. Raja Rathnam Korani
Civil Surgeon Specialist, District
Head Quarters Hospital, Tandur,
Vikarabad, Telangana, India

Functional bracing leading to acceptable outcomes and with less morbidity. All types of conservative or nonsurgical treatments have advantages as well as disadvantages. The demerits include prolonged limb immobilization, need constant co-operation, compliance and follow ups [4]. However, it cannot be recommended in cases like unstable fractures (spiral / long oblique), comminuted, segmental, pathological and fractures with delayed union or nonunion. Fractures of such type require surgical treatment [1].

For most open injuries, fractures with vascular injuries, ipsilateral upper extremity segmental fractures, bilateral upper extremity fractures, radial nerve palsy, segmental or pathologic fractures, polytrauma patients, surgical stabilization is recognized as the choice of treatment [5]. Intramedullary fixation of rods and nails and compression plating are the two most common fixation methods with higher rate of complications (shoulder pain, nonunion, and reoperation) in the former with no significant differences in functional outcome [6, 7].

The compression plating method has been demonstrated to offer the best treatment for humeral shaft fractures that require surgical intervention [7]. In recent times, surgery is warranted in some cases for fulfillment of the demands of modern patients like early relief from pain, faster union and quicker return to function.

Acute fractures of the humerus have a good healing tendency with non-operative treatment; thus, functional bracing is still the treatment of choice in many trauma centers. In patients, when operative treatment is needed, plate and screws osteosynthesis has been the treatment of choice [8].

Holstein and Lewis [9] were strongly against closed reduction of fractures of the distal one-third of the humerus, with demonstrable radial nerve paralysis. So they recommend primary open reduction and internal fixation through antero-lateral approach as the treatment of choice for this injury [9]. Plates are easy to apply and have an important place in the treatment. In most of the cases union occurs readily and simple plating is usually adequate. Nevertheless, there is probably some advantage in using a plate of dynamic compression.

The compression plating is regarded as gold standard of surgical treatment [10], yielding in high union rates, less complications and early return to function [11]. It can be used effectively even in fractures with proximal and distal extensions. Standard treatment for most of the humeral shaft fractures is non-operative functional bracing; however, certain clinical scenarios necessitate operative intervention.

Therefore, the present study was aimed to evaluate the results of diaphyseal fractures of humerus operated by open reduction internal fixation with plating technique, with focus over their functional outcome results and complications. The functional outcome results were evaluated in terms of range of mobility and subjective complaints.

Material and Methods

The present study was conducted in the Department of Orthopaedics, Osmania Medical College, Hyderabad, Telangana, India. The patients with an acute humeral shaft fracture in adults admitted and treated in the Orthopaedic Ward of Osmania General Hospital, Hyderabad, Telangana, India, were included in this study. During the study period, a total of n = 12 cases of fracture shaft of humerus were studied.

These n = 12 subjects were studied by taking detailed history, clinical examination to find out the nature of the fracture and followed by a routine examination consisting of an antero-posterior and a lateral radiograph of the affected arm to confirm

the diagnosis. The patients were admitted, investigated and treated by open reduction and plate fixation method.

The inclusion criteria in this study, was patients with a fracture shaft of humerus, patients who gave their consent to undergo the procedure. The exclusion criteria included elderly patients, patients with associated fractures, head injury, pathological or open fractures, patients with neurovascular deficiency and patients medically unfit for surgery.

Ethical Committee approval was taken from the Institutional Ethical Committee Board. Thorough clinical history was taken from each patient and / or attendants to know the mode of injury and the severity of trauma as well as radiographic data. All patients were examined thoroughly for their general condition, and associated injuries were noted. All the findings were duly recorded in the patient proforma. The written informed consent for surgery was obtained from the patients and they were operated after a pre-anesthetic checkup.

Preoperative radiographs of humerus were taken in antero-posterior and lateral views with shoulder and elbow joints included for confirmation of the diagnosis and also to know the type of the fracture.

Case description

In all patients, primary stabilisation of the fractures was done by U-slab. Almost all patients were operated within a week after injury except in one patient with closed simple short oblique fracture of shaft of left humerus with left radial palsy.

The present study series comprised of n = 12 subjects with acute humeral shaft fractures. The cases were adults with age ranging from 25 to 66 yrs with average age being 40 yrs. The majority of the patients n = 10 (83.33%) were males and n = 2 (16.67%) were females (Table 1), in the ratio of 5:1. Right side humerus was involved in n = 9 (75%) and left in n = 3 (25%) patients. The most common mode of injury was fall from height except 2 cases were road traffic accident (RTA).

The incidence of site of fracture showed n = 5 (41.67%) cases had fracture at middle 1/3rd level, n = 1 (8.33%) had fracture at upper middle 3rd level, n=6(50%) had fracture at lower middle 3rd level (Table 3).

Operative Technique

All n = 12 adult patients with traumatic fractures of humeral shaft were treated surgically by open reduction and plating technique. Most of the fractures were treated with in a week after trauma except with radial nerve palsy.

The patients were subjected to surgery by plating technique following standard Henry's antero-lateral approach. Surgery was done three days following admission after obtaining fitness for surgery. The patients were placed in supine position on fracture table with a pack below the scapula for anterolateral plating. All the procedures were carried out under general anaesthesia.

The limb was thoroughly cleaned with savlon, spirit and draping was done. Through six-inch skin incision (Henry's approach), the deep fascia was cut the muscle biceps and brachioradialis were retracted. The radial nerve was isolated, tied and retracted. The fracture site was exposed and the edges were freshened. Reduction was obtained with bone holding forceps. A six-holed heavy duty plate was fixed with six screws, haemostasis was secured. A Redivac suction drain was kept and ASD and pressure bandage was applied.

In one patient with closed simple short oblique fracture shaft of left humerus at the junction of mid and lower third with post-traumatic radial nerve palsy. The incision was placed between triceps and brachioradialis, the fracture site was exposed. This

patient was subjected to surgery by plating technique following Henry's postero-lateral approach. The butterfly fragment was fixed with a six holed plate and screws. The wound was closed in layers. X-ray imaging was used to verify proper plate placement.

Post-operative care

The patients recovered from anaesthesia were kept in the post-operative ward for 24 to 48 hrs. The patient was put on antibiotics and analgesics for one week. The limb was immobilized for initial 48 hrs. Removal of drain in cases of plating was done 48 hrs after surgery. The patients were encouraged to make simple active movements of the elbow and shoulder, while avoiding loading them. The sutures were removed on the 10th day, following which physiotherapy in form of biceps and triceps strengthening exercises, later full range of mobility exercises were allowed. The wound healed well and satisfactorily. The patient was discharged 2 weeks later.

Follow up

Follow up was made two and six weeks after the operation, and then every 1 month subsequently up to 6 months and were assessed clinically for pain and range of mobility and radiologically for bone union. After consolidation had been demonstrated, the patient was advised to make movements with

full load-bearing, and return visits were made every 3 months. The clinical criteria for healing of the fracture included absence of pain and tenderness at fracture site with free shoulder and elbow activity. Radiological criteria were callus formation and disappearance of the fracture line on follow ups. Functional outcome results assessment of the patient was done on the criteria of clinical radiological union, range of mobility at elbow and shoulder, subjective complaints like pain in the shoulder / elbow [12]. They were graded as excellent, moderate or poor.

Results and Discussion

In this study, a total of n = 12 cases of diaphyseal fractures of the humerus, treated surgically by open reduction and plating technique, out of which ordinary stainless steel plates were used for 11 patients and a dynamic compression plate for 1 case.

Out of the n = 12 cases in this study, n = 10 (83.33%) were male subjects and n = 2 (16.67%) were female (Table 1). The youngest patient was aged 25 yrs and the oldest was 66 yrs (Table 2) of age, mean age was 40 years. The incidence of injury in the right side was in n = 9 (75%) cases and left side in n = 3 (35%) cases.

The type of fracture was transverse in n = 4 (33.33%) cases, oblique in 4 (33.33%), spiral in n = 2 (16.67%) and comminuted in n = 2 (16.67%) cases (Table 1).

Table 1: Incidence of gender, side and type of fracture in the present study subjects

Subjects	Gender		Side		Type of fracture			
	Male	Female	Right	Left	Transverse	Oblique	Spiral	Comminuted
No. of cases	10	2	9	3	4	4	2	2
Percentage (%)	83.3	16.6	75	25	33.33	33.33	16.6	16.6

Table 2: Incidence of age in the present study subjects

Age group (years)	No. of cases	Percentage (%)
21 – 30	5	41.6
31 – 40	4	33.33
41 – 50	1	8.3
51 – 60	0	0
61 – 70	2	16.6

In n = 5 (41.67%) cases the fracture was situated at the junction of the mid 1/3rd of the shaft of the humerus. n = 1 (8.33%) case had fracture situated at the junction of the upper and mid 1/3rd of the shaft of the humerus and n = 6 (50%) cases were situated at the junction of the mid and lower third of the humerus (Table 3).

Table 3: Site of the fracture in the present study subjects

Subjects	Total No. of cases studied	Upper 1/3	Mid 1/3	Lower 1/3	Upper mid 3 rd	Lower mid 3 rd
No. of subjects	12	0	5	0	1	6
Percentage (%)	100	0	41.67	0	8.33	50.0

Out of n = 12 cases, n = 1 (8.33%) case had post-traumatic radial nerve palsy with wrist drop. 11 cases underwent surgery within the first week after admission and n = 1 patient was operated after 1 week.

In this study, the complication of radial nerve palsy was observed only in n = 1 (8.33%) patient (Table 4) post-operatively, similar to the findings of 6-15% in various earlier study reports [13 - 15]. It improved after conservative treatment

with neurotrophic drugs for about 6 weeks. No long-term radial nerve paralysis occurred.

Sutures were removed on the 10th day. In all the cases, the wound healed well with no infection. The patients were discharged with advice to perform active shoulder and elbow joint movements and finger movements. They were advised not to lift weights with the affected limb. The patients were followed post-operatively for 1 – 6 months. Late complications like stiffness of elbow and shoulder joints, myositis ossifians, non-union, mal-union, refracture were not observed in our series (Figures 1–4).

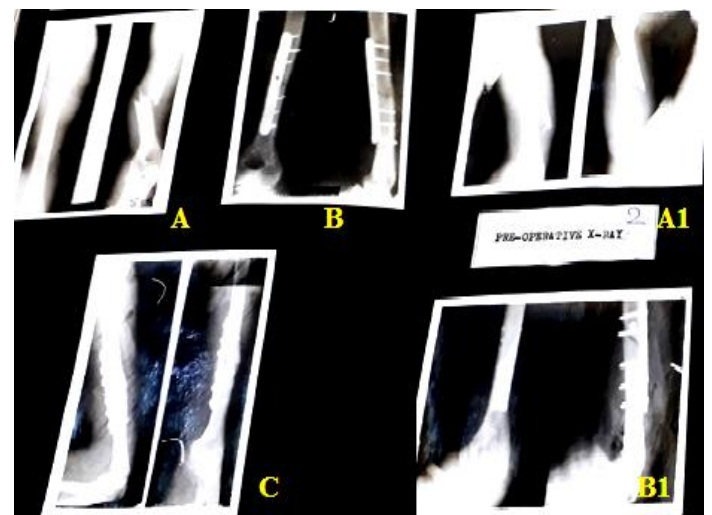


Fig 1: Diaphyseal fractures radiographs: A, A1- pre-operative, B, B1- post-operative, C- union after plate fixation

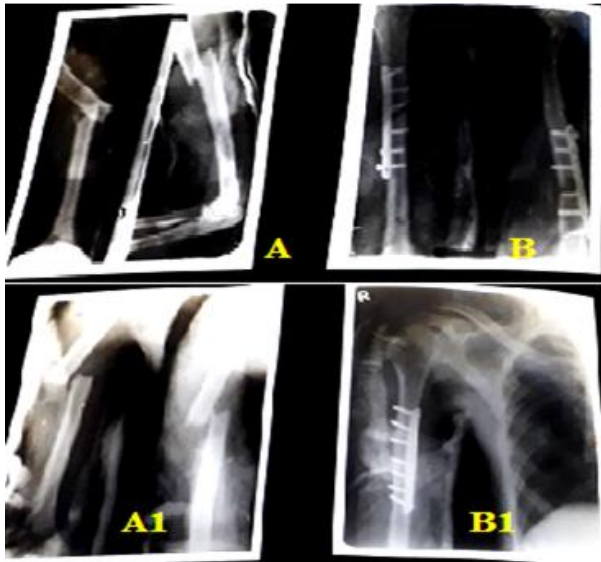


Fig 2: Radiographs: A, A1- pre-operative, B, B1- post-operative

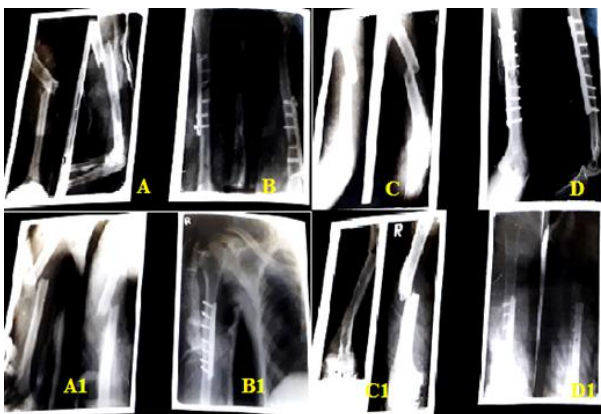


Fig 3: Radiographs: A, A1, C, C1- pre-operative, B, B1, D, D1- post-operative

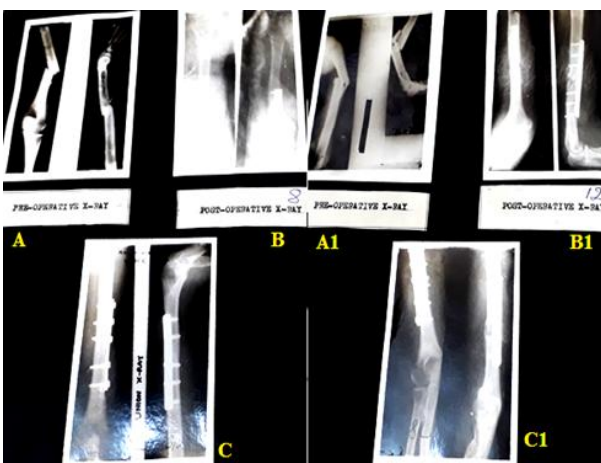


Fig 4: Radiographs: A, A1- pre-operative, B, B1- post-operative, C, C1- union

Both intra-medullary nailing and plating are best method for surgical fixation of shaft humerus fractures, yielding good results in terms of functional outcomes and union rates in both the methods. However, the best method for surgical management has not been established. Chapman *et al.* [16], in a study series of 84 humerus fractures treated either with plating or intra-medullary nailing, concluded both as predictable methods for fracture stabilization and ultimate healing.

Traditionally, the compression plating method is regarded as gold standard of surgical treatment [6, 7, 10, 16], yielding high union rates, less complications and early return to activities [11]. But on the other side, it is a longer duration surgery, associated with high infection rate and radial nerve palsy [18, 19]. The anterolateral approach is a classic and widely accepted approach for mid shaft humeral fracture fixation which allows excellent exposure and fixation. n = 1 (8.33%) case of radial nerve palsy occurred in the anterolateral approach surgery. Normal function was restored in 6 weeks after surgery (Table 4). No patient developed non-union after the ORIF. No complications were observed in this study. In n = 10 (83.33%) cases, full range of motion (ROM) of the shoulder and elbow was restored postoperatively within 4 weeks. In n = 2 (16.67%) patients with radial nerve palsy, ROM was restored after 6 weeks (Table 4).

Table 4: Radial Nerve Palsy in the present study subjects

Subjects	Radial Nerve Palsy		No. recovered and percentage (%)	Duration of recovery
	Pre-operative	Post-operative		
No. of cases	1	1	2	
Percentage (%)	8.3	8.3	16.6	6 weeks

In this study, the functional outcome assessment was done at the time of review taking both shoulder and elbow joints into consideration. In this series, n = 12 cases, shoulder and elbow function was excellent/ good in all n = 12 (100%) patients with active joint mobility. In all cases the functional outcome was good. Restriction of joint mobility was not seen in the patients as they followed physiotherapy strictly.

Advantages

- This type of treatment had the following advantages:
- Immediate immobilization of the fracture site.
- Rapid union of fracture of fracture site because of rigid immobilization
- Quick recovery of post traumatic complications like radial nerve palsy.
- Relatively fewer post-operative complications like radial nerve palsy.
- Short hospital stay.

Conclusion

Open reduction and plating was the treatment of choice in simple diaphyseal fractures of humerus with or without radial nerve palsy. In the present study, the sample size was small and so, to draw a definite conclusion a study with a larger sample size and longer duration of follow up is needed.

References

1. Klenerman L. Fractures of the shaft of the humerus. Journal of Bone and Joint Surgery, British Volume. 1966; 48(1): 105-111.
2. Sharma V, Awasthi B, Mehta SM, Yadav RS, Babhulkar S. Evaluation of results of different treatment modalities in management of diaphyseal fractures of humerus. Ind J of Clin Pract. 2014; 24(11):1068-1074.
3. Sarmiento A, Zagorski JB, Zych GA, Latta LL, Capps CA. Functional bracing for the treatment of fractures of the humeral diaphysis. J Bone Joint Surg Am. 2000; 82(4):478486.
4. Clement ND. Management of humeral shaft fractures; non-operative versus operative. Arch Trauma Res. 2015;

- 4(2):e28013.
5. Gregory PR, Sanders RW. Compression plating versus intramedullary fixation of humeral shaft fractures. *J Am Acad Orthop Surg.* 1997; 5(4):215-223.
 6. McCormack R, Brien D, Buckley R, McKee M, Powell J, Schemitsch E. Fixation of fractures of the shaft of the humerus by dynamic compression plate or intramedullary nail: a prospective, randomised trial. *J Bone Joint Surg Br.* 2000; 82(3):336-339.
 7. Niall DM, O'Mahony J, McElwain JP. Plating of humeral shaft fractures--has the pendulum swung back? *Injury.* 2004; 35(6):580-586.
 8. Heim D, Herkert F, Hess P, Regazzoni P. Surgical treatment of humeral shaft fractures--the Basel experience. *J Trauma.* 1993; 35:226-232.
 9. Holstein A, Lewis GB. Fractures of the Humerus with Radial-Nerve Paralysis. *J Bone and Joint Surg.* 1963; 45(A): 1382-1388.
 10. Mauch J, Renner N, Rikli D. Intramedullary nailing of humeral shaft fractures—initial experiences with an unreamed humerus nail. *Swiss surg.* 2000; 6(6):299-303.
 11. Tingstad EM, Wolinsky PR, Shyr Y, Johnson KD. Effect of immediate weightbearing on plated fractures of the humeral shaft. *J Trauma and Acute Care Surg.* 2000; 49(2):278-280.
 12. Constant CR, Murley AG. A clinical method of functional assessment of the shoulder. *Clin ortho and related res.* 1987; (214):160-164.
 13. Garcia A, Maeck BH. Radial nerve injuries in fractures of the shaft of the humerus. *The Amer J Surg.* 1960; 99(5):625-627.
 14. Kettelkamp DB, Alexander H. Clinical review of radial nerve injury. *J Trauma and Acute Care Surg.* 1967; 7(3):424-432.
 15. Christensen NO. Kuntscher Intramedullary Reaming and Nail Fixation for Nonunion of the Humerus. *Clin ortho and related res.* 1976; 116:222-226.
 16. Chapman JR, Henley MB, Agel J, Benca PJ. Randomized prospective study of humeral shaft fracture fixation: intramedullary nails versus plates. *J orthop Trauma.* 2000; 14(3):162-166.
 17. Lin J. Treatment of humeral shaft fractures with humeral locked nail and comparison with plate fixation. *J Trauma-Injury Infect Critical Care.* 1998; 44(5):859-864.
 18. Watanabe RS. Intramedullary fixation of complicated fractures of the humeral shaft. *Clin ortho and related res.* 1993; 292:255-263.
 19. Hall RF, Pankovich AM. Ender nailing of acute fractures of the humerus. A study of closed fixation by intramedullary nails without reaming. *J Bone Joint Surg Am.* 1987; 69(4): 558-567.