

ISSN (P): 2521-3466
 ISSN (E): 2521-3474
 © Clinical Orthopaedics
 www.orthoresearchjournal.com
 2017; 1(2): 43-49
 Received: 12-05-2017
 Accepted: 13-06-2017

Dr. Pathik Vala
 MS Ortho DNB Ortho. Assistant
 Professor, C.U. Shah Medical
 College, Surendranagar, Gujarat,
 India

Dr. Ajay Devda
 MS Ortho. Consultant. Mavjat
 hospital, Palanpur, Gujarat, India

Dr. Darshil Parikh
 Resident doctor, Department of
 Orthopaedics, C.U. Shah medical
 College, Surendranagar, Gujarat,
 India

Dr. Akshay Chavda
 MS Ortho, Yogini trust, Vadodara,
 Gujarat, India

Evaluation of results of surgical management of closed intra-articular fractures of distal end *Humerus*

Dr. Pathik Vala, Dr. Ajay Devda, Dr. Darshil Parikh and Dr. Akshay Chavda

Abstract

Introduction: The management of distal humeral fractures has evolved over the last few years. In intra articular fracture of the lower end Humerus the primary goal is to achieve a stable and mobile elbow. Until now, disagreement has existed on how to treat these fractures in elderly patients. Recommendations range from conservative treatment to primary total elbow replacement. So far, reports in the literature on whether or not open reduction and internal fixation in these patients is justified are very rare.

Materials and methods: Fifty four patients (Average age 45 years) from Jan 20013 To Dec 2014 were included in this series. There were 38 males and 16 females. Mechanism of injury was fall with back of elbow striking the ground (70%) and Road traffic accident (30%). The author has used AO classification⁵ for categorizing the fractures accordingly, 10 fractures were of B2, 14 were B3, 12 were C1 type and 10 belonged to C2 and 8 belonged to C3 Type.

Results and discussion: The average follow up was 16 months with a minimum of one year. 14 cases had loss of extension measuring 30⁰ and less. Only 12 cases had no loss of extension. Flexion of elbow more than 1200 got recovered in 28 cases. 10 patients had pain in elbow on prolonged activity and changes in weather condition. The final evaluation showed 70 % Excellent and good results, 24% had Fair results and 6% had poor results. When “K” wire alone were used fixation was not stable enough and required longer external immobilization. And delay in start of physiotherapy with consequent loss of movements. Olecranon osteotomy gives better visualization. and reduction of fracture fragments and their articular surface.

Conclusion: Rigid Anatomical Fixation & Early Mobilisation is the Key. High complications in Elderly Osteoporotic patients. Younger the patient Better the results. Communion of Fragments show increased Difficulty in Fixation, & results in loss of movements also.

Keywords: surgical management, Mechanism, surgical management

Introduction

The management of distal humeral fractures has evolved over the last few years. Worldwide application of the AO principles of plate and screw fixation during the late 1980s and early 1990s remained the only breakthrough for quite some time [1]. Recent major advancements in the management of these injuries include the widespread availability of computed tomography (CT) scans with three-dimensional reconstruction, recognition of the more complex articular shear fractures [2], understanding the benefits of the parallel-plate technique [3], the availability of precontoured periarticular plates, and the selective use of total elbow arthroplasty [4].

Opportunity for improvement remains, as reflected by the interest in distal humeral hemiarthroplasty for the treatment of these injuries and the controversy regarding the ideal management of the ulnar nerve as a part of this surgery and how to best manage structural bone loss. Unfortunately, insufficient internal fixation with Kirschner wires continues to be performed by some surgeons, greatly compromising patient outcome.

In intra articular fracture of the lower end Humerus the primary goal is to achieve a stable and mobile elbow. An incidence of 5.7 per 100,000 per year, found in a United Kingdom study among those 12 years and older, was considered to be 5%–10% of the incidence in children². The frequency varied by gender and age with a higher incidence seen among males in the 12–19 year age groups while a higher incidence was seen in middle aged and elderly females. Fractures of the distal humerus account for 2% of fractures in adults.

Fractures of the distal humerus are often the result of a fall (low-energy injury) or a direct blow onto the back of the upper arm when the elbow is held in a flexed position (high-energy injury). Fractures due to falls are most common in the elderly while those resulting from

Correspondence

Dr. Ajay Devda
 MS Ortho. Consultant. Mavjat
 hospital, Palanpur, Gujarat, India

trauma are more common in the younger population. The choice of intervention for patients with distal humeral fractures remains unclear and may in part depend on patient age, bone quality, and fracture classification.

Swelling that may accompany distal humeral fractures may influence the timing of surgical intervention. Arthroplasty and plating may hold promise in more complex fractures, but there are few comparative studies.

Fractures of the distal humerus are difficult to treat. In elderly patients, diminished bone mineral quality and increased trauma-associated joint destruction may make stable joint reconstruction even more problematic. Furthermore, comorbidities and poor tolerance of joint immobilization might be additional factors which influence elbow function negatively.

Until now, disagreement has existed on how to treat these fractures in elderly patients. Recommendations range from conservative treatment to primary total elbow replacement. So far, reports in the literature on whether or not open reduction and internal fixation in these patients is justified are very rare.

Materials and methods

Fifty four patients (Average age 45 years) from Jan 2009 To Dec 2011 were included in this series. There were 38 males and 16 females. Mechanism of injury was fall with back of elbow striking the ground (70%) and Road traffic accident (30%). The right elbow was commonly affected. Most patients reported with in 1st week of injury. 4 cases reported after 3 months, and another reported after 5 months of injury with non- union. 1 Case reported after 1 year of injury with non-union.

The author has used AO classification⁵ for categorizing the fractures accordingly, 10 fractures were of B2, 14 were B3, 12 were C1 type and 10 belonged to C2 and 8 belonged to C3 Type. No cases was operated on the day of injury as an Emergency procedure. Most cases were operated in first week

after injury because of late arrival to the hospital. The interval between injury and Operation of various cases is shown in Table I.

Exclusion Criteria in our Series

- Fractures in Children & adolescents upto age of 18 years.
- Side- sweep Injuries.
- Open Injuries of Elbow
- Cases treated by Ring Or External Fixator

All the cases were done by trans olecranon Approach to maintain uniformity, & to obtain the single handedness of the operating Surgeon. The Ulnar Nerve was dissected & was not transposed anteriorly, but protected by a fascial sling posteriorly before closure of the wound.

Procedure

There are various approaches to the distal end of Humerus, but in our series we have preferred to have a trans olecranon approach compulsorily even if the fracture is B2 type so as to have a good look into the articular surfaces & not to miss any small fractures not seen on traction xrays.

A variety of approaches have been described for reduction and fixation of distal humeral fractures. Most commonly, a posterior approach with an olecranon osteotomy has been used, but concerns about healing and symptomatic implants have led to more frequent use of a triceps-reflecting (Bryan-Morrey or triceps-reflecting anconeus pedicle approach, as advocated by Bryan and Morrey and O'Driscoll, or a triceps-splitting (Campbell approach, as advocated by McKee *et al.* The best fracture exposure is provided by an olecranon osteotomy approach. As more familiarity is gained with fracture patterns and reduction techniques, a triceps-reflecting or triceps-splitting approach may be selected to reduce complications.

Table 1: Surgical Approaches Used for Treatment of Fractures of the Distal Humerus

	Surgical Approach	Indications	Contraindications	Advantages	Disadvantages
Posterior	Olecranon	ORIF for	TER	Good access	Nonunion
	osteotomy	fractures		to posterior	and failure
		involving		articular	of fixation
		columns		surfaces for	Of

Surgical Approach	Indications	Contraindications	Advantages
	and		Reconstruction
	articular		
	surface		
Triceps-splitting	ORIF/TER	Previous	Avoids
	for	Olecranon	Complications
	fractures	osteotomy	Associated
	involving	Approach	With
	columns	Patients at	Olecranon
	and	Increased	Osteotomy
	articular	risk for	
	surface	Healing	

		Problems	
Triceps-reflecting	Fractures requiring	ORIF	Avoids Complications
	TER	Previous	associated
		Olecranon	with
		osteotomy	olecranon
		Approach	osteotomy
		Patients at risk	
		for healing	
		Problems	
Triceps-detaching	ORIF/TER for fractures involving columns and	Previous Olecranon osteotomy	Avoids Complications Associated
		Approach	With
		Patients at risk	Olecranon Osteotomy
		for healing	
	articular		
		Problems	
	surface		
Medial	Medial		

Surgical Approach	Indications	Contraindications	Advantages	Disadvantages
	epicondylar fractures			inaccessible
	Medial column fractures			
Kocher	Lateral column fractures	Suspected more complex articular surface fracture	Radial nerve protected	Medial column inaccessible
	Lateral epicondylar fractures			
	Capitellar fractures			
Lateral Koeber				Risk of injury to radial nerve
				Medial column inaccessible
Jupiter	Complex articular surface fractures	Significant involvement of the Columns		Medial column inaccessible

Position the patient in the lateral decubitus position. A prone or supine position also can be used. An advantage of the supine position is improved anterior exposure of the joint, which is helpful with very low fractures and fractures with anterior comminution. Fixation of the fracture with extension into the shaft can be difficult to reduce with the patient supine. Prepare and drape the entire forequarter to allow placement of a sterile tourniquet on the proximal arm.

Make a midline incision, with or without a curve over the tip of the olecranon, and develop full-thickness flaps medially and laterally.

Dissect the ulnar nerve free from the medial edge of the triceps and from the medial epicondyle. Preserve the vascular structures that supply the ulnar nerve. Laterally, dissect the triceps off the lateral intermuscular septum. Incise the interval between the triceps and anconeus muscles to expose the joint. Alternatively, preserve the anconeus innervation by using the interval between the anconeus and the extensor carpi radialis brevis and elevating the anconeus with the triceps. Ensure that

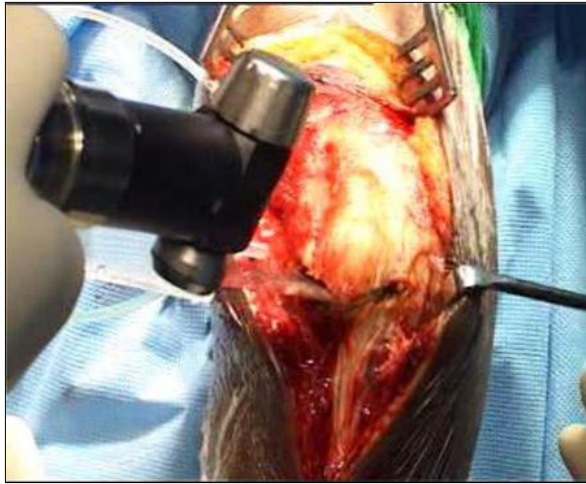the medial and lateral olecranon articular surface can be seen. Predrill the holes for olecranon fixation before making the osteotomy. Make a distally oriented chevron osteotomy with an oscillating saw directed toward the sulcus of the articular surface of the olecranon. Use an *osteotome* to complete the osteotomy carefully. If the osteotomy is forcefully wedged open with the osteotome, a large cartilaginous flap can be created inadvertently. Raise the triceps with the proximal olecranon, and direct the triceps musculature off the humerus, preserving the *periosteum*. Use threaded Kirschner wires as joysticks to manipulate the medial and lateral condyles. If the articular fracture is simple, reduce the fracture with the joysticks and a Weber clamp, and insert Kirschner wires for provisional fixation. Every screw should pass through a plate. Each screw should engage a fragment on the opposite side that is also fixed to a plate. As many screws as possible should be placed in the distal fragments. Each screw should be as long as possible. Each screw should engage as many articular fragments as possible. Plates should be applied such that

compression is achieved at the supracondylar level for both columns. Plates used must be strong enough and stiff enough to resist breaking or bending before union occurs at the supracondylar level.

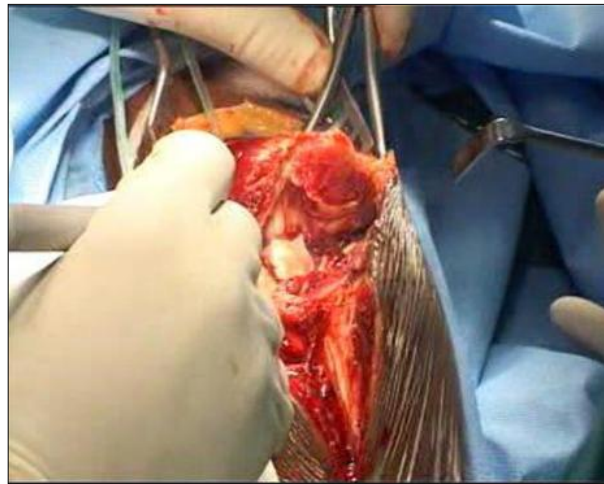
Operative Technique: The patients were operated under general anaesthesia. Bicondylar B2, B3 & C type fractures were operated in lateral position, keeping the elbow up using

posterior approach and “V” Chevron osteotomy of the Olecranon was done. Implants used were for internal fixation were 1 ‘K’ wires, Malleolar/ Cancellous/ Cortical screws 3.5mm, 5-7 hole 3.5 mm DCP, Reconstruction Plates and LC Plates.

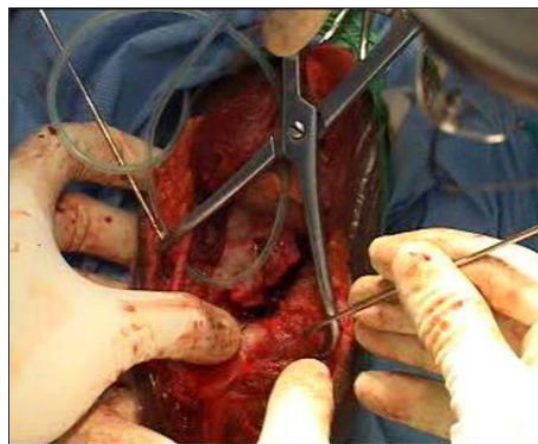
Bone grafting was done in 2 cases, 1 of nonunion and 1 fracture with lots of comminution of bone which presented late after 3 weeks.



Olecranon Osteotomy



Triceps Aponeurosis Being Lifted Along with Part Of Olecranon to expose the lower end Humerus.

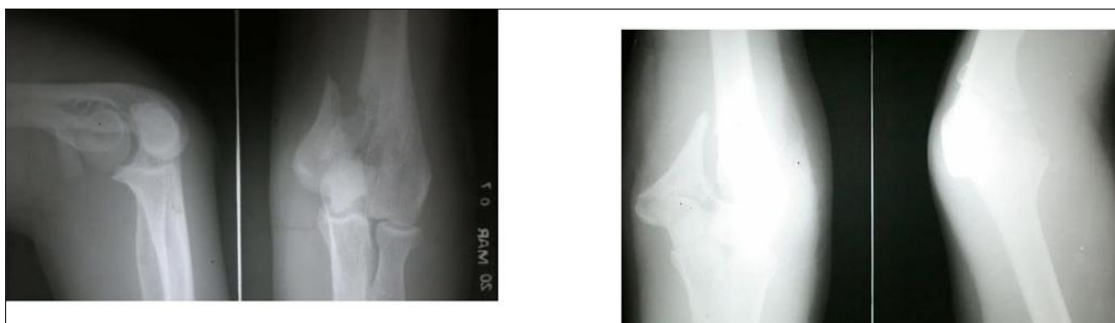

Reduction Achieved with Temporary K-wires using them as Joy Stick.

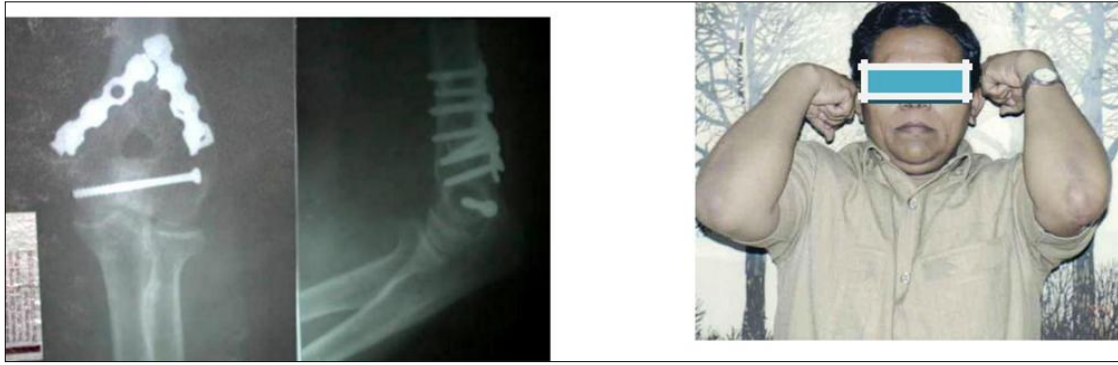Postoperative Care: A light posterior POP splint from post axillary fold to the Knuckles. Depending upon pain tolerance and wound healing the posterior splint was removed and gentle active and active assisted exercises were carried out within the pain threshold almost after 1 week initially on the Elbow CPM later on under expert guidance of a Physiotherapist with

active & Passive Exercises. The splint was reapplied after exercises. The splint immobilisation was kept for two to three weeks.

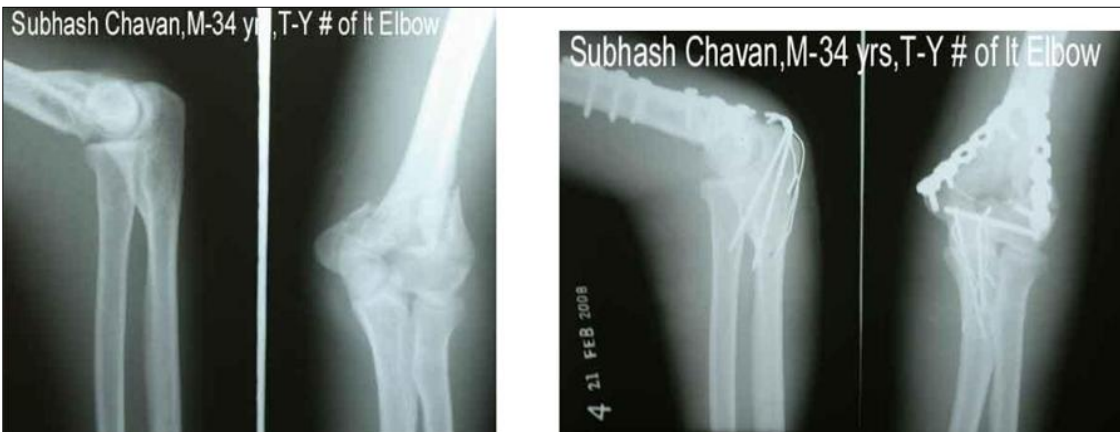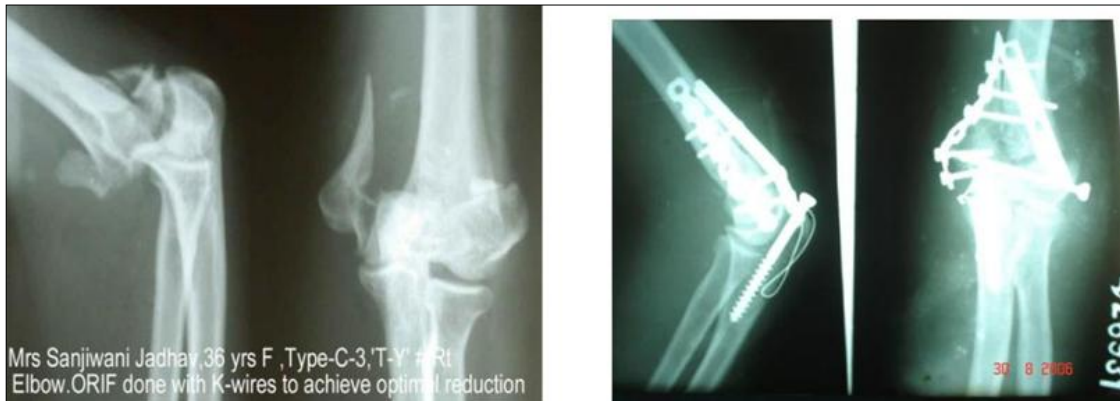Clinical Illustrations



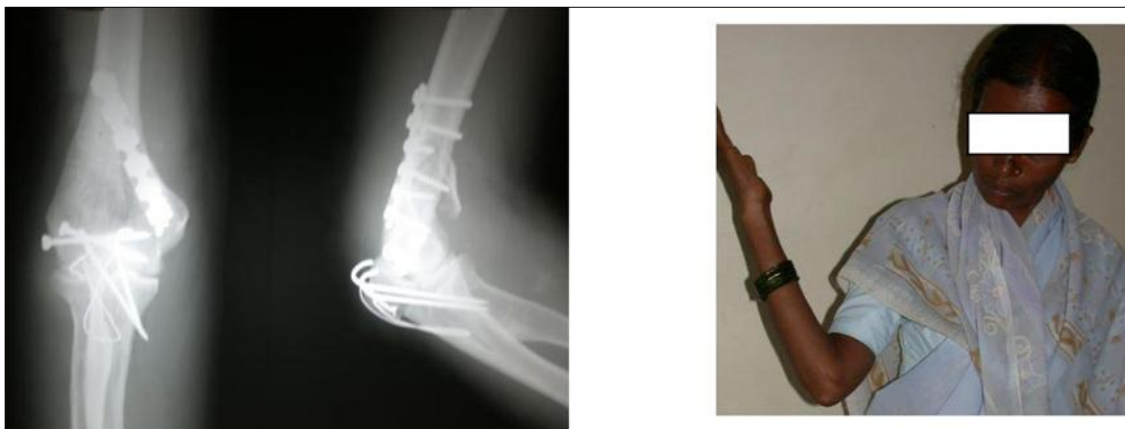Case 1



Case 2



Case 3



Case 4

Follow-Up

The patients were examined both clinically and radiologically every 2 weeks for first 3 months and then every month for next 4 months or so on for 1 year subsequently. A minimum follow

up of one year was taken. The elbow and forearm movements were measured with standard Goniometer. The results were Graded according to Jupiter *et al* criteria [7].

Results

Results	ROM in Loss of Extension	Degrees Flexion	Pain	Disability
Excellent	<15 ⁰	>130 ⁰	None	None
Good	<30 ⁰	>120 ⁰	Slight	Minimal
Fair	<40 ⁰	>90 ⁰	With activity	Moderate
Poor	<40 ⁰	>90 ⁰	Variable	Severe

This rating methodology was selected as it combines elbow motion with the patient's subjective symptoms of pain and disability.

Results

The average follow up was 16 months with a minimum of one year. 14 cases had loss of extension measuring 30⁰ and less. Only 12 cases had no loss of extension. Flexion of elbow more than 1200 got recovered in 28 cases. 10 patients had pain in elbow on prolonged activity and changes in weather condition. The final evaluation showed 70 % Excellent and good results, 24% had Fair results and 6% had poor results.

One of the most common complication of operative treatment was transient Ulnar Nerve palsy seen in 4 cases. All recovered well with by 4 weeks. Superficial infection was seen in 3 cases. The wounds healed with regular dressings but immobilization was prolonged, leading to stiffness of elbow.

"K"wire loosening was a very common feature 10%, breakage of TBWire was seen in 6 cases. In these cases union was seen and implant removal was done. Loosening of implants and breakage was seen in 8 cases with non-union 4 cases. Implant removal was done in all cases of Implant failure with some times re-fixation and bone grafting in cases of non-union.

Complications

Post Traumatic Stiffness, ROM ...Flexion Less Than 90 Degrees, & Loss of Extension More Than 20 degrees...4 cases.

K-wire Breakages & Back firing... 6-cases.

Superficial Infection... 3 cases

Osteotomy delayed Union (10 weeks). 1 case.

Transient Ulnar Neuro praxia ...4 cases.

Heterotrophic Ossification1 case.

Discussion

One of the prime indications of open reduction and sound osteo synthesis are the intra articular fractures of the distal Humerus. Non operative management of these fractures has not given good results. In the present study we have not included open fractures and side swipe injuries of the Elbow. The pattern of fracture visible on radiograph was not necessarily same as that on operation. Additional communiton of fragment was seen on surgery commonly. The "Classification variable" has not demonstrated any substantial correlation and had no adverse influence in this study but long term results suggest that C1, C2 & C3 type of fractures have more pain & stiffness.

"K" wire was used as an adjunct to plate / Screw Fixation especially in fractures with extensive communiton, where plate and screws cannot satisfactorily fix the fragments. Most of our Fair and poor results cases had "K" wire fixation of both pillars or plate fixation in one pillar and "K" wire in the other. The author does not recommend K-wire Fixation at all. The interval between surgery and Mobilisation is shown in Table II. When "K" wire alone were used fixation was not stable enough and required longer external immobilization. And delay in start of physiotherapy with consequent loss of

movements. Olecranon osteotomy gives better visualization. And reduction of fracture fragments and their articular surface. No case of nonunion of "V" osteotomy was seen in this series. We did primary bone grafting in 2 cases to prevent articular surface being stenotic, while fixing the condyles with malleolar screw.

Good movements were achieved in cases where physiotherapy was started early. This was possible when congruous articular surfaces and stable fixation was achieved. Range of movements between 30 to 120 was found to be useful Functional range of Elbow movement.

Most of the elbow function was seen to be acquired at four months after surgery and no improvement was seen after six months. Extension at elbow is more difficult to achieve than flexion. This view was also expressed by Risenborough and Radin [7].

No obvious correlation of interval between injury and operation was found with regard to outcome of results. Satisfactory results were seen in cases of non-union. Therefore there is no need for emergency surgery which can be delayed for a couple days except in case of vascular injury. This should be carried out as planned surgery as it is formidable procedure and much scope for learning and improvement in execution exists. Excellent to good results were seen in 70%. Similar study conducted by Jupiter *et al* showed 69% excellent to good results. Holdsworth *et al* showed 76% excellent to good results using similar criteria. In this series poor results are attributed to extensive communiton of fragments, inability to achieve congruous joint surface, prolonged immobilization, anterior bony ledge and inclusion of cases of nonunion.

It was also noted that clinical function did not match with the follow up radiographs. Open reduction and stable osteosynthesis achieving a congruous joint surface facilitates early elbow mobilization and consequent excellent to good functional results in majority of these fractures. We have obtained excellent results after osteo synthesis and bone grafting in an old nonunion in a type C condylar fracture. We, therefore, feel that instead of jumping to arthroplastic procedures, one should aim to achieve solid union and near normal joint surface and functional elbow improvement is bound to follow.

Conclusions

Type B 2 to C 3 usually Rx by ORIF by Trans olecranon Fixation. Rigid Anatomical Fixation & Early Mobilisation is the Key. High complications in Elderly Osteoporotic patients. Younger the patient Better the results. Communiton of Fragments show increased Difficulty in Fixation, & results in loss of movements also.

References

- Melton LJ, 3rd, Amadio PC, Crowson CS *et al*. Long-term trends in the incidence of distal forearm fractures. *Osteoporos Int*. 1998; 8:341-8.
- Robinson CM, Hill RM, Jacobs N *et al*. Adult distal humeral metaphyseal fractures: epidemiology and results of treatment. *J Orthop Trauma*. 2003; 17:38-47.

3. Carson S, Woolridge DP, Colletti J *et al.* Pediatric upper extremity injuries. *Pediatr Clin North Am.* 2006; 53:41-67.
4. Davis RT, Gorczyca JT, Pugh K. Supracondylar humerus fractures in children. Comparison of operative treatment methods. *Clin Orthop Relat Res.* 2000, 49-55.
5. Khan MS, Sultan S, Ali MA *et al.* Comparison of percutaneous pinning with casting in supracondylar humeral fractures in children. *J Ayub Med Coll Abbottabad.* 2005; 17:33-6.
6. Ruedi T, Murphy WM. *AO Principles of Fracture Management.* Thieme: Stuttgart-New York, 2000, 1.
7. Chen RS, Liu CB, Lin XS *et al.* Supracondylar extension fracture of the humerus in children. Manipulative reduction, immobilisation and fixation using a U-shaped plaster slab with the elbow in full extension. *J Bone Joint Surg Br.* 2001; 83:883-7.