

ISSN (P): 2521-3466
ISSN (E): 2521-3474
© Clinical Orthopaedics
www.orthoresearchjournal.com
2017; 1(2): 01-04
Received: 01-05-2017
Accepted: 02-06-2017

Dr. Harsh Vardhan
MS (Orth), MS (Anat) Tutor
Department of Anatomy MGM
Medical College, Jamshedpur, East
Singhbhum, Jharkhand, India

Dr. GS Baraik
MBBS, MS (Orthopaedics)
Associate Professor Orthopaedics
MGMMCH Jamshedpur, East
Singhbhum, Jharkhand, India

Randher
Statistician, MGM Medical College
Jamshedpur Department of PSM,
Jharkhand, India

Dr. Rituraj
MBBS, MS (General Surgery),
MGMMCH, Jamshedpur,
Jharkhand, India

Dr. Rashmi Kumari
MBBS, Intern MGMMCH,
Jamshedpur, Jharkhand, India

Outcome of hyaluronic acid injection in treatment of symptomatic osteoarthritis of the knee

Dr. Harsh Vardhan, Dr. GS Baraik, Randher, Dr. Rituraj and Dr. Rashmi Kumari

Abstract

Osteoarthritis is a common pathological condition affecting knee joint. Long term use of analgesics in osteoarthritis is not acceptable by many patients. The purpose of this study is to find out the efficacy of three doses of intra articular Hyaluronic acid injection in treatment of Osteoarthritis of knee which is an easy procedure and can be carried out on an OPD basis. 37 Patients (54 Knees) with duration of symptoms more than 12 months were included in the study. Patients with associated Diabetes Mellitus, local infection, ligament injury, Crystalline arthropathy were excluded. Pre and post procedure VAS score was assessed. Patients were followed up 1 week, 2 weeks, 3 weeks, 3 months, 6 months after the injection. At 1st week 24.3%, at 2nd weeks 51.3%, at 3rd weeks 86.4% and at 3rd months and 6th months 94.5% patients had significant reduction in pain and improvement in VAS score.

Keywords: Visual Analogue Score, OPD:- Out patient Department, OA:-Osteoarthritis

Introduction

Osteoarthritis is a chronic joint disorder in which there is progressive softening and disintegration of articular cartilage accompanied by new growth of cartilage and bone at the joint margin and capsular fibrosis [1]. It is ubiquitous in all population and has significant individual, social and economic impact worldwide [2]. The largest risk factor associated with osteoarthritis is age and it has been reported by world Health Organization that 10% of world population over the age of 60 suffers from osteoarthritis. Disability as a result of Osteoarthritis is also well recognized and it has been observed that Osteoarthritis is second only to ischaemic heart disease as a cause of work related disability in males over 50 years of age [2]. Knee is the commonest large joint to be affected by Osteoarthritis. In many of the cases no obvious cause can be found which is known as primary osteoarthritis. Sometime factors such as injury to the articular surface, torn meniscus and ligament instability also leads to secondary osteoarthritis. Primary pathology is the area of cartilage distuction in the area of maximum loading mainly medial joint compartment [1]. Pain is the leading symptom which is worse after use. Stiffness is felt after sitting for any length of time. On examination there may be varus deformity. The quadriceps muscle is usually wasted. X ray features of OA of knee narrowing of joint space, sclerosis of sub chondral bone under area of cartilage loss, subchondral cysts close to articular surface and osteophytes at the margin of the joint [1]. Severe bone destruction is seen in the late stage. Complications associated with osteoarthritis of knee can be marked effusion of joint and herniation of posterior joint capsule (Baker's cyst), loose body in the joint due to fragmentation of cartilage and bone in the joint, which occasionally can produce locking. Hyaluronan is a component of synovial fluid, responsible for its viscoelasticity [2]. In OA catalytic enzymes reduce the concentration and molecular weight of the hylan polymers. Thus, Viscosupplementation with synthetic long chain hyaluronan preparations has been developed as intraarticular therapy of OA. Given as a weekly dose of injection for 3 weeks. The purpose of this study is to find out the efficacy of three doses of intra articular Hyaluronic acid injection in treatment of Osteoarthritis of knee which is an easy procedure and can be carried out on an OPD basis.

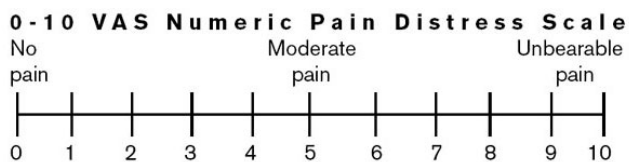
Methods

Interventional prospective study was carried out at my private clinic and MGM Medical College Hospital Jamshedpur over a period of 7 months from Aug 2016 to Feb 2016 on 37

Correspondence

Dr. Harsh Vardhan
MS (Orth), MS (Anat) Tutor
Department of Anatomy MGM
Medical College, Jamshedpur, East
Singhbhum, Jharkhand, India

Patients of age more than 50 years from both sex 13 males and 24 females. A detail performa was filled up with identification of the patient including address, a complete history with special attention to onset of pain, aggravating and relieving factors. History of stiffness lasting not more than 30 minutes and crepitus on motion. A plain x ray of the knee joint including anteroposterior (AP) and lateral view. Was taken to confirm the diagnosis. Position of the patient during injection was supine under all aseptic condition part preparation was done using betadine solution. Injection was given with 2ml prefilled syringe containing hyalan. Each ml contain 8 mg of Hyalan. One injection was given per week for three weeks. With the knee extended superolateral edge of patella was the site of injection with the needle aimed under patella [2]. Patients were advised no excessive weight bearing, physical activities for one to two days following injection. The patient was followed up at one week, two weeks, three weeks after injection. At each visit VAS was assessed to evaluate the status of the pain and the result was compared with preprocedure results. The selected data was analyzed using SPSS Software (Statistical package for Social Sciences). P value <0.05 was considered significant.

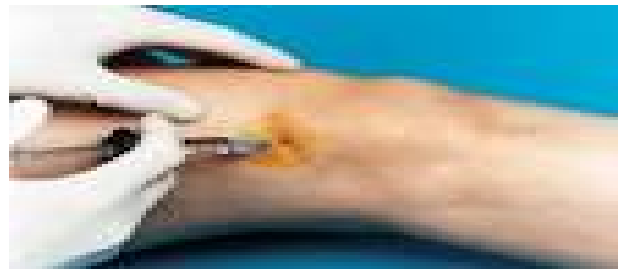

Patient was asked to describe his pain in each follow up. He/she was asked to give their pain a score between one to ten. 0-1- no pain, 2-4- mild pain, 5-7- moderate pain, more than 7 severe pain.

Table 1: VAS Comparison at different follow up (f/up)

	MEAN	Mean improvement in VAS Scale	N	Std Deviation	Std error Mean	P Value
VAS- Pre procedure	7.45	2.5405	37	0.68	0.11	
At 1 week f/up	5.27	4.7568	37	1.61	0.22	<0.0001
VAS-pre procedure	7.45	2.5405	37	0.68	0.11	
At 2 weeks f/up	4.24	5.7297	37	2.05	0.33	<0.0001
VAS-Pre procedure	7.45	2.5405	37	0.68	0.11	
At 3 weeks f/up	3.21	6.7838	37	1.9	0.310	<0.0001
VAS-Pre procedure	7.45	2.5405	37	0.68	0.11	
At 3 months f/up	1.59	8.4054	37	2.02	0.330	<0.0001
VAS-Pre procedure	7.45	2.5405	37	0.68	0.11	
At 6 months f/up	1.64	8.3784	37	1.86	0.304	<0.0001

The mean VAS score was 7.45 pre procedure and at one week follow up it was 5.27, At 2nd week it was 4.24 and at 3rd week it was 3.21. At 3rd months it was significantly lower than preprocedure score and was 1.59. It was still lower at 6 month but was slightly more than 3rd month and it was 1.64. There is gradual improvement in patient's condition as VAS Score decreases from 7.5 to 1.59 at 3rd month follow up. Although the VAS Score increases slightly from 3rd to 6th month (1.64) but the condition of patient was significantly better. At 1st week follow up 9(24.3%) patients had significant pain relief, 12(33%) at 2 weeks follow up, 19(51%) at 3 weeks, 32(86.4%) at 3 months and 35(94.5%) at 6 months follow up shows significant pain relief respectively.



Performing injection with prefilled syringe of hyaluronic acid through superolateral angle of patella as the site of injection.

Observation and result

During the study period a total forty patients with diagnosis of osteoarthritis were included in the study. 3 patients did not meet the requirement of six months follow up so they were excluded from study. For the final evaluation only thirty seven patients were available. The age of the patients ranges from 50 years to 84 years. The mean age was 64.9 years with standard deviation 8.6. Out of 37 patients 13(35.2%) were male and 24(64.8%) were female. Height of the patients ranged from 150cm to 168 cm with mean height of 161cm. Weight of the patient ranged from 55kg to 78kg with mean weight of 69.2 kg. Duration of symptoms ranged from 12 months to 48 months with mean duration 33.7 months. Out of 37 patients 33 patients were under active group and 4 patients were having sedentary life style. The disease was bilateral in 17 (45%) patients and unilateral in 20 patients with 11(29.7%) on left side and 9(24.3%) on right side. Out of 37 patients 21(57%) had grade II, 11(30%) had grade III and 7(13%) had grade I Osteoarthritis of knee.

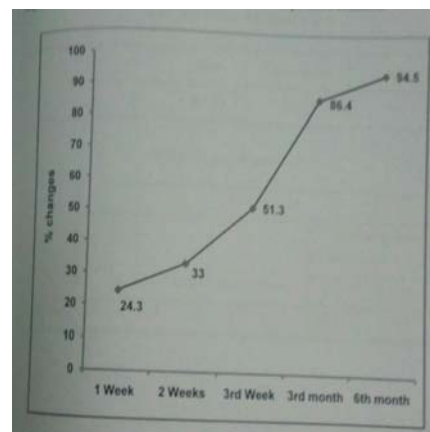


Fig 2: Percentage change in VAS Score at different follow up.

Discussion

Knee osteoarthritis is a common but often difficult problem to manage in primary care. Traditional management consists of lifestyle modification, physical therapy and pharmacological therapy including analgesics and anti-inflammatory drug is often ineffective and leaves residual symptoms. Viscosupplementation is newly available option for patients with symptomatic osteoarthritis of knee that involves a series of intraarticular injections of hyaluronic acid. The exact mechanism is not known but increase in viscoelasticity of synovial fluid appears to play a role. The exact indications for viscosupplementation are still evolving but it currently can be considered for use in patients who have significant residual symptoms despite traditional nonpharmacological and pharmacological treatments. In addition patients who are intolerant to traditional treatment (gastrointestinal problems) can be considered for these injections. Physician with the ability to perform intraarticular injections should consider them as option in patients with symptomatic osteoarthritis of knee.

Conclusion

Although the impact of medication was not similar on all the patients undergone treatment. The medication has good impact on the patients. In the first three months improvement in patient's condition was satisfactory. Between third and sixth months improvement was less than expectation but improvement in patient's condition was satisfactory. Therefore it can be considered as good alternative for the treatment of symptomatic osteoarthritis of knee in those patients who are refractory or intolerant to conservative treatment with NSAIDs.

References

- Abate M, Pulcini D, Di Iorio A, Schiavone C. Viscosupplementation with intraarticular hyaluronic acid for treatment of osteoarthritis in the elderly. *Curr Pharm Des*, 2010; 16(6):631-640.
- Abate M, Pelotti P, De Amicis D, Di Iorio A, Galletti S, Salini V. Viscosupplementation with hyaluronic acid in hip osteoarthritis (a review). *Ups J Med Sci*, 2008; 113(3):261-277.
- Aggarwal A, Sempowski IP. Hyaluronic acid injections for knee osteoarthritis. Systematic review of the literature. *Can Fam Physician*, 2004; 50:249-256.
- Altman R, Alarcon G, Appelrouth D, Bloch D, Borenstein D, Brandt K *et al*. The American College of Rheumatology criteria for the classification and reporting of osteoarthritis of the hip. *Arthritis Rheum*, 1991; 34(5):505-514.
- Andrews JR. Diagnosis and treatment of chronic painful shoulder: review of nonsurgical interventions. *Arthroscopy*, 2005; 21(3):333-347.
- Atchia I, Kane D, Reed MR, Isaacs JD, Birrell F. Efficacy of a single ultrasound-guided injection for the treatment of hip osteoarthritis. *Ann Rheum Dis*, 2011; 70(1):110-116.
- Bagga H, Burkhardt D, Sambrook P, March L. Longterm effects of intraarticular hyaluronan on synovial fluid in osteoarthritis of the knee. *J Rheumatol*, 2006; 33(5):946-950.
- Bannuru RR, Natov NS, Obadan IE, Price LL, Schmid CH, McAlindon TE. Therapeutic trajectory of hyaluronic acid versus corticosteroids in the treatment of knee osteoarthritis: a systematic review and meta-analysis. *Arthritis Rheum*, 2009; 61(12):1704-1711.
- Bellamy N, Campbell J, Robinson V, Gee T, Bourne R, Wells G. Viscosupplementation for the treatment of osteoarthritis of the knee. *Cochrane Database of Systematic Reviews*, 2006; 19:2.
- Berg P, Olsson U. Intra-articular injection of non-animal stabilised hyaluronic acid (NASHA) for osteoarthritis of the hip: a pilot study. *Clin Exp Rheumatol*, 2004; 22(3):300-306.
- Blaine T, Moskowitz R, Udell J, Skyhar M, Levin R, Friedlander J *et al*. Treatment of persistent shoulder pain with sodium hyaluronate: a randomized, controlled trial. A multicenter study. *J Bone Joint Surg Am*, 2008; 90(5):970-979.
- Brocq O, Tran G, Breuil V, Grisot C, Flory P, Euller-Ziegler L. Hip osteoarthritis: short-term efficacy and safety of viscosupplementation by hylan G-F 20. An open-label study in 22 patients. *Joint Bone Spine*, 2002; 69(4):388-391.
- Brzusek D, Petron D. Treating knee osteoarthritis with intra-articular hyaluronans. *Curr Med Res Opin*, 2008; 24(12):3307-3322.
- Caglar-Yagci H, Unsal S, Yagci I, Dulgeroglu D, Ozel S. Safety and efficacy of ultrasound-guided intra-articular hylan G-F 20 injection in osteoarthritis of the hip: a pilot study. *Rheumatol Int*, 2005; 25(5):341-344.
- Calis M, Demir H, Ulker S, Kirnap M, Duygulu F, Calis HT. Is intraarticular sodium hyaluronate injection an alternative treatment in patients with adhesive capsulitis? *Rheumatol Int*, 2006; 26(6):536-540.
- Calvillo O, Skaribas I, Turnipseed J. Anatomy and pathophysiology of the sacroiliac joint. *Curr Rev Pain*, 2000; 4(5):356-361.
- Carpenter B, Motley T. The role of viscosupplementation in the ankle using hylan G – F 20. *Journal of Foot & Ankle Surgery*, 2008; 47(5):377-384.
- Chazerain P, Rolland D, Cordonnier C, Ziza JM. Septic hip arthritis after multiple injections into the joint of hyaluronate and glucocorticoid. *Rev Rhum Engl Ed*, 1999; 66(7-9):436.
- Cleary M, Keating C, Poynton AR. Viscosupplementation in lumbar facet joint arthropathy: a pilot study. *J Spinal Disord Tech*. 2008; 21(1):29-32.
- Coaccioli S, Pinoca F, Puxeddu A. Short term efficacy of intra-articular injection of hyaluronic acid in osteoarthritis of the first carpometacarpal joint in a preliminary open pilot study. *Clin Ter*, 2006; 157(4):321-325.
- Cohen MM, Altman RD, Hollstrom R, Hollstrom C, Sun C, Gipson B. Safety and efficacy of intra – articular sodium hyaluronate (Hyalgan) in a randomized, double – blind study for osteoarthritis of the ankle. *Foot and Ankle International*, 2008; 29(7):657-663.
- Colen S, van den Bekerom MP, Bellemans J, Mulier M. Comparison of intraarticular injections of hyaluronic acid and corticosteroid in the treatment of osteoarthritis of the hip in comparison with intra-articular injections of bupivacaine. Design of a prospective, randomized, controlled study with blinding of the patients and outcome assessors. *BMC Musculoskelet Disord*, 2010; 11:264.
- Conrozier T, Bertin P, Mathieu P, Charlot J, Bailleul F, Treves R *et al*. Intra-articular injections of hylan G-F 20 in patients with symptomatic hip osteoarthritis: an open-label, multicentre, pilot study. *Clin Exp Rheumatol*, 2003; 21(5):605-610.
- Cunnington J, Marshall N, Hide G, Bracewell C, Isaacs J, Platt P *et al*. A randomized, double – blind, controlled

- study of ultrasound – guided corticosteroid injection into the joint of patients with inflammatory arthritis. *Arthritis Rheum*, 2010; 62(7):1862-1869.
25. Curran MP. Hyaluronic acid (Supartz®): a review of its use in osteoarthritis of the knee. *Drugs Aging*, 2010; 27(11):925-941.
 26. Dagenais S. Intra-articular hyaluronic acid (viscosupplementation) for knee osteoarthritis. *Issues Emerg Health Technol*, 2006; 94:1-4.
 27. Divine JG, Zazulak BT, Hewett TE. Viscosupplementation for knee osteoarthritis: a systematic review. *Clin Orthop Relat Res*, 2007; 455:113-122.
 28. Di Sante L, Cacchio A, Scettri P, Paoloni M, Ioppolo F, Santilli V. Ultrasoundguided procedure for the treatment of trapeziometacarpal osteoarthritis. *Clin Rheumatol*, 2011, 22.
 29. Egsmose C, Lund B, Bach AR. Hip joint distension in osteoarthrosis. A tripleblind controlled study comparing the effect of intra-articular indoprofen with placebo. *Scand J Rheumatol*, 1984; 13(3):238-242.