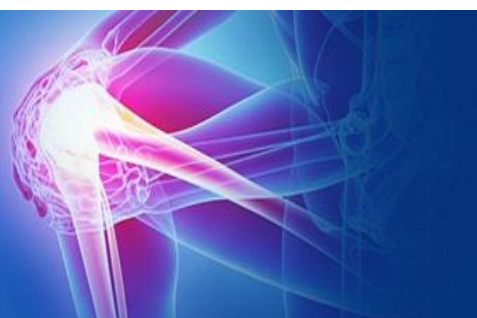



ISSN (P): 2521-3466
ISSN (E): 2521-3474
© Clinical Orthopaedics
www.orthoresearchjournal.com
2018; 2(3): 28-32
Received: 21-05-2018
Accepted: 24-06-2018

Sumit Kumar
Junior Resident, Department of
Orthopaedics, Shri Mahant
Indresh Hospital, Dehradun,
Uttarakhand, India

Mohit Dhingra
MS Orthopaedics Associate
Professor, Department of
Orthopaedics, Shri Mahant
Indresh Hospital, Dehradun,
Uttarakhand, India

Pankaj Sharma
Assistant Professor, Department
of Orthopedics, Shri Mahant
Indresh Hospital, Dehradun,
Uttarakhand, India

Navneet Badoni
MS Orthopaedics Professor,
Department of Orthopaedics,
Shri Mahant Indresh Hospital,
Dehradun, Uttarakhand, India

Puneet Gupta
Head of Department,
Department of Orthopaedics,
Shri Mahant Indresh Hospital,
Dehradun, Uttarakhand, India

Mohd Bilal kaleem
Junior Resident, Department of
Orthopaedics, Shri Mahant
Indresh Hospital, Dehradun,
Uttarakhand, India,

Correspondence
Mohit Dhingra
MS Orthopaedics Associate
Professor, Department of
Orthopaedics, Shri Mahant
Indresh Hospital, Dehradun,
Uttarakhand, India

Management of periprosthetic femoral fracture after hip replacement (Vancouver b1): treating successfully using internal fixation

Sumit Kumar, Mohit Dhingra, Pankaj Sharma, Navneet Badoni, Puneet Gupta and Mohd Bilal kaleem

Abstract

Periprosthetic femoral fractures associated with hip arthroplasty pose a significant challenge to the orthopedic surgeon and are difficult to treat.

The incidence of periprosthetic fracture is increasing steadily due to increase in

1. Number of cases
2. Incidence of replacement surgeries

Periprosthetic fractures after hip arthroplasty pose a significant challenge to the orthopedic surgeon as the treatment still remains controversial.

The difficulty in treatment is due to

1. Age of the patient as most of the patients are of elderly age group.
2. Absence of bone stock
3. Presence of cement which hampers biological healing
4. Presence of implant which pose difficulty in putting another implant and fixing these fractures.

Most common classification used for these fractures is Vancouver classification which takes into consideration the quality of bone, stability of implant and site of fracture and are challenging task for surgeon to treat, as the treatment remains controversial, difficult fracture fixation and biological healing is compromised.

Here we have included only Vancouver B 1 fractures in our study.

These fracture are becoming important now a days because of increase number of replacemnt surgeries occuring world-wide.

Keywords: Periprosthetic fractures, Vancouver classification, hip arthroplasty, internal fixation.

Abbreviations: HHS, Harris Hip Score; THR, total hip replacement.

Introduction

Periprosthetic femoral fracture in association with total hip arthroplasty (THA) was first reported in 1954.1 since then, the incidence has steadily increased as the indications for THA have broadened and the life expectancy of the population has increased. 2-5 The current overall incidence of periprosthetic femur fracture is approximately 4.1%, with higher rates for uncemented and revision THA. 2 It defines the site of the fracture, the quality of the stem fixation, and the quality of the bone itself. When the fracture occurs around a well-fixed prosthesis (Vancouver type B1 fractures) osteosynthesis is recommended. 6 This is usually performed using osteosynthesis plating systems. In recent years, the preference has been for locking plates. 7

Classification

The widely accepted classification system for postoperative periprosthetic fractures of the femur, developed by Duncan and Masri in 1995, which takes into consolidation at the location of the fracture, stability of the prosthesis, and quality of bone stock [12]. Commonly called the Vancouver classification, it has proved to be quite practical due to its reliability, high validity, and its established treatment algorithm [9-12]. Fractures are categorized by three types based on level.

- 1) Type A fractures are located at the proximal metaphysis, and are further subdivided based on involvement of the greater trochanter (AG) and lesser trochanter (AL).

- 2) Type B fractures include those around or just below the stem. These also are sub-classified:
 - (i) Type B1 fractures occur around a well-fixed stem,
 - (ii) Type B2 fractures occur around a loose prosthesis but with good bone stock
 - (iii) Type B3 fractures are seen in cases with a loose stem and poor bone stock or significant comminution.
- 3) Type C fractures occur well below the stem. Other classifications used historically in the literature include the Bethea (fracture pattern), Johansson (fracture location), Mont and Mar (fracture location and pattern), and Beals and Tower (fracture location/prosthetic interphase disruption) systems, among others [13, 14-16].

While the Vancouver system is quite effective in most cases, its major fault lies in its total reliance on preoperative radiographic evaluation of stem stability to distinguish type B1 and type B2 fractures. In principle, type B1 fractures are assumed to be the result of traumatic injuries in relatively normal bone, although some osteoporosis may still be present. On the contrary, type B2 and B3 fractures are byproducts of pathological interfaces between the bone-cement-prosthesis or

bone-prosthesis. It is critical that type B2 and B3 fractures be identified so that the pathologic prostheses may be addressed. Unfortunately, not all of these pathologic fractures can be recognized based upon radiographic loosening of the femoral stem, and this may result in incorrect classification. For example, as high as 20% of loose stems are missed on preoperative X-ray evaluation, and many surgeons fail to adequately test stability in the operating room. Also, a well-fixed stem does not always indicate a clear lack of pathology, and the fracture event could accelerate impending mechanical failure [17, 18].

The Coventry classification, developed by Ninan *et al.* in 2007, stratifies fractures into “happy hips” or “unhappy hips” based upon multiple criteria to evaluate for signs suggestive of femoral stem pathology, not just radiograph alone. “Unhappy hips” include previously established loosening in patients already scheduled for revision surgery, worsening hip pain or dysfunction, fracture with minimal trauma, or clear signs of loosening on radiograph [19]. Just like type B1 and B2 fractures, “happy hips” can be managed with fracture fixation, whereas “unhappy hips” require revision. Using multiple modalities to assess the status of the femoral component should reduce the likelihood that a loose femoral prosthesis is left in place.

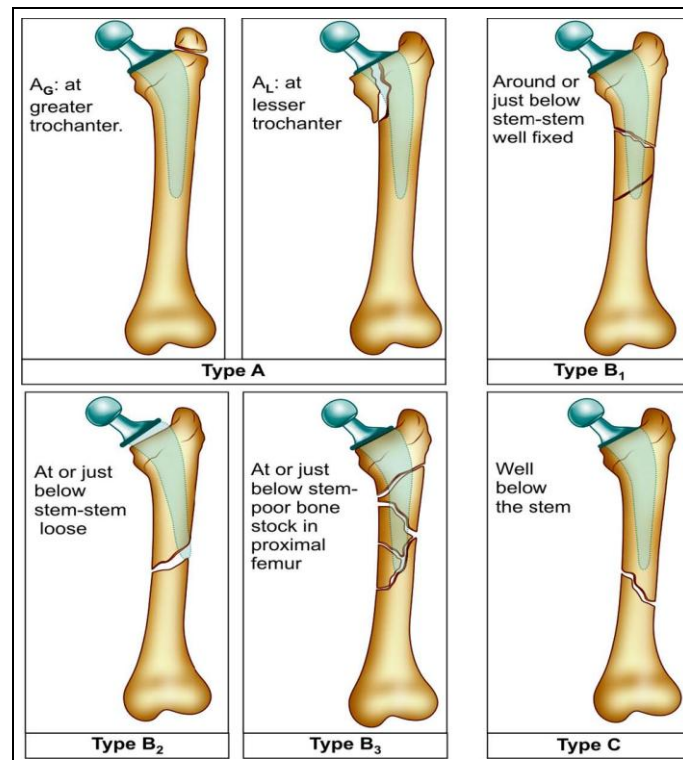


Fig 1: The Vancouver classification of periprosthetic femur fractures around total hip arthroplasty. The classification is based on the location of the fracture, stability of the femoral implant, and quality of the surrounding bone stock.

Materials and methods

In our study we included patients classified in Vancouver classification (B1) and only the postoperative fractures were included (intraoperative fractures were excluded). It is also the only classification system for periprosthetic fracture to be assessed for reliability and validity [8].

We carried out this study in our institution (Shri Mahant Indresh Hospital, Dehradun, Uttarakhand, India), included only patients treated between January 2016 to August 2017 and were diagnosed by analyzing their records through discharges and diagnosis made.

Final clinical outcomes were evaluated through Harris hip score. Only patient classified as Vancouver B1 were included in the study.

Diagnosis of the patient was made briefly by:

- 1) 1) Brief history of the patient
- 2) 2) Nature of pain after injury or was that pain present before injury or not, as pain before injury explain about loosening of prosthesis
- 3) 3) Signs of infection were ruled out before surgery
- 4) All inflammatory markers as (CRP, ESR, TLC, DLC).
- 5) Mode of trauma was minor trauma (i.e slip and fall). Digital radiographs were taken out to see the extent of fracture.

Results

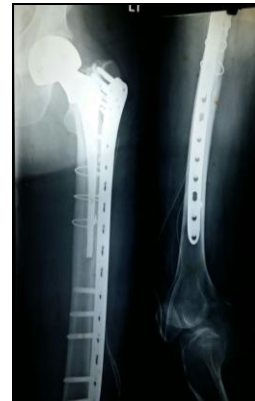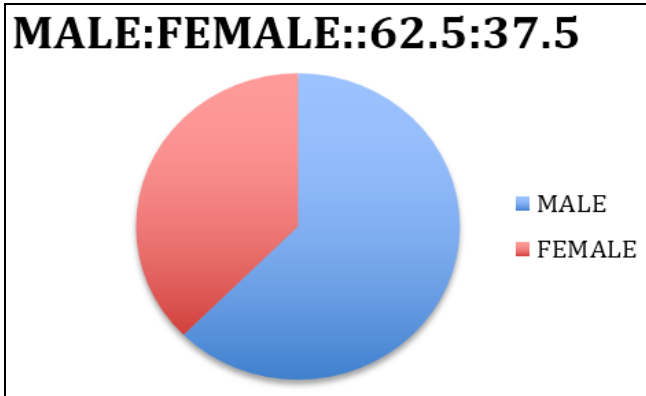
8 patients 5 male and 3 female, classified as Vancouver type B1 fracture were treated. Surgery was done with open

reduction and internal fixation through lateral approach (3 patient with cortical strut graft based on quality of bone), quality of the bone observed intraoperatively. All patients were treated with dynamic compression locking plate and 3 patients

were treated with stainless steel cerclage wires, as some fracture without cerclage wire were inadequate.

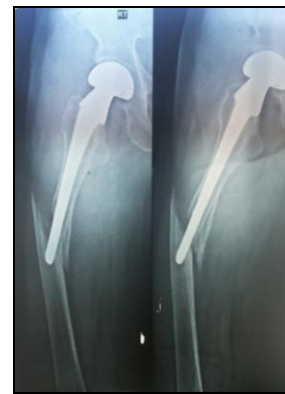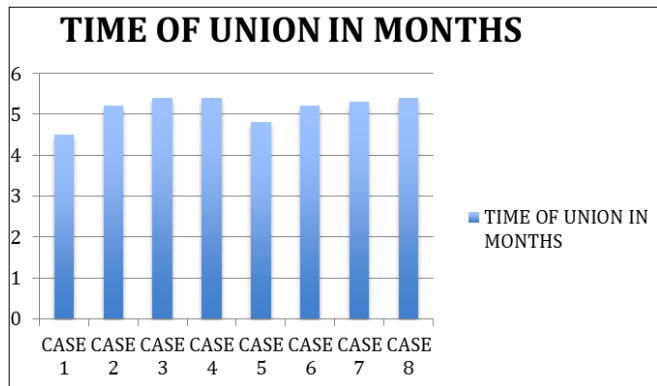
Treatment and outcome

Case no	Age	Sex	Vancouver classification	Time of union in months	Mean Harris score	Strut graft used	Death > 6 months	Complication (malunion, nonunion, heterotrophic ossification, failure fixation)	Comorbidity
1	65	male	B1	4.5	78.4	NO	NO	NIL	Diabetes mellitus
2	70	female	B1	5.2	76.1	YES	NO	NIL	Nil
3	72	male	B1	5.4	77.4	NO	NO	NIL	Hypertensive
4	74	male	B1	5.4	72.2	YES	NO	NIL	Nil
5	69	female	B1	4.8	77.4	YES	NO	NIL	Diabetes mellitus
6	79	male	B1	5.2	77.4	NO	NO	NIL	NIL
7	81	female	B1	5.3	74.2	NO	NO	NIL	NIL
8	76	male	B1	5.4	75.2	NO	NO	NIL	NIL



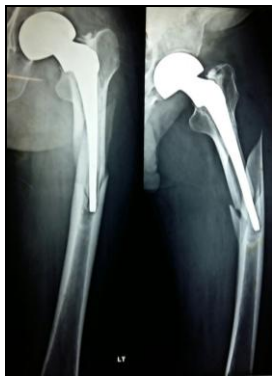B

B) Fracture treatment with ORIF and locking compression plate with unicortical proximal and bicortical distal screw with cerclage



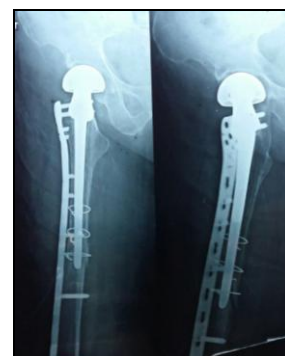C

C) Radiograph of Vancouver type B1 fracture, fracture at the level of tip of stem with a stable implant



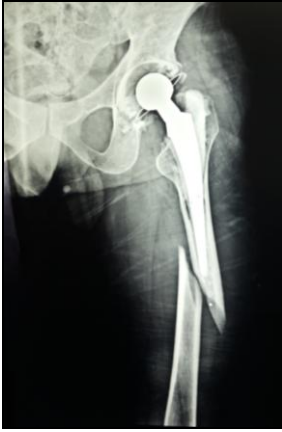A

A) Radiograph of Vancouver type B1 fracture, fracture at the level of tip of stem with a stable implant



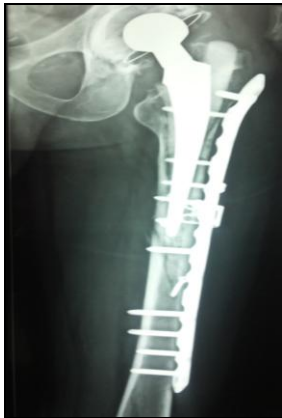D

D) Fracture treatment with ORIF and locking compression plate with unicortical proximal and bicortical distal screw with cerclage



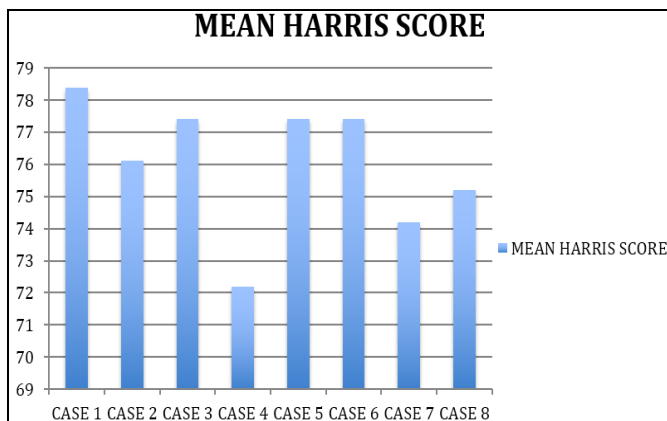
E

E) Radiograph of Vancouver type B1 fracture, fracture at the level of tip of stem with a stable implant



F

F) Fracture treatment with ORIF and locking compression plate with unicortical proximal and bicortical distal screw and lag screw



Discussion

Management of periprosthetic fractures are difficult in treating and really a challenging task for surgeon to deal with, as mainly in elderly bones are osteoporotic, absence of bone stock, presence of bone cement, and implant itself and fragile and difficult to treat. Management of periprosthetic fracture depends on fracture classification, as described by Vancouver and different type have different management. Here in our study we are emphasizing on type B1 vancouver fracture by osteosynthesis by using open reduction and internal fixation by locking compression plate, cerclage in some cases and using strut graft.

Strut grafts have an advantage of being a biological and osteoconductive osteosynthesis technique, providing reduced

stress shielding due to similar modulus of elasticity as the native bone, and augmenting bone stock and strength after union [20, 21, 22-24] Placing two strut grafts with three fixation points above and below the fracture have been shown to yield good outcomes [25, 26].

Biomechanical studies by Dennis and associates demonstrated that plates with proximal uni-cortical screws or unicortical screws and cerclage, as well as distal bicortical screws, achieved a significantly more stable osteosynthesis than plates with cerclage alone, plates with just proximal cerclage and distal bicortical screws (Ogden construct) or two strut grafts with cerclage alone [27].

In our study we give the best alternative for the treatment for management of periprosthetic B1 vancouver fracture by low complication rates and good union rates.

Conclusion

Expert skills are needed by the surgeon to deal with periprosthetic fractures. Mainstay for the treatment of Vancouver B1 fracture is open reduction and internal fixation. Locking compression plate with locking screws gives excellent result in osteoporotic bone. We recommend this technique for management of B1 fractures as results are excellent, predictable and reproducible, good healing and surgical results and easy to perform, with low technical results. Elderly patient are more beneficial as they are able to mobilize early and remain away from bed ridden comorbidities.

References

1. Horwitz IB, Lenobel MI. Artificial hip prosthesis in acute and nonunion fractures of the femoral neck: follow-up study of seventy cases. *J Am Med Assoc.* 1954; 155(6):564-567.
2. Berry DJ. Epidemiology: hip and knee. *Orthop Clin North Am.* 1999; 30(2):183-190.
3. Berry DJ. Periprosthetic fractures associated with osteolysis: a problem on the rise. *J Arthroplasty.* 2003; 18(31):107-111.
4. Lewallen DG, Berry DJ. Periprosthetic fracture of the femur after total hip arthroplasty. Treatment and results to date. *J Bone Joint Surg Am.* 1997; 79(12):1881-1890.
5. Lewallen DG, Berry DJ. Periprosthetic fracture of the femur after total hip arthroplasty: treatment and results to date. *Instr Course Lect.* 1998; 47:243-249.
6. Fink B, Fuerst M, Singer J. Periprosthetic fractures of the femur associated with hip arthroplasty. *Arch Orthop Trauma Surg.* 2005; 125:433-442.
7. Pike J, Davidson D, Garbuz D. Principles of treatment for periprosthetic femoral shaft fractures around well-fixed total hip arthroplasty. *J Am Acad Orthop Surg.* 2009; 17:677-688.
8. Brady OH, Garbuz DS, Masri BA, Duncan CP. The reliability and validity of the Vancouver classification of femoral fractures after hip replacement. *J Arthroplasty.* 2000; 15:59-62.
9. Brady OH, Garbuz DS, Masri BA. The reliability and validity of the Vancouver classification of femoral fractures after hip replacement. *J Arthroplasty.* 2000; 15:59-62.
10. Naqvi GA, Baig SA, Awan N. Interobserver and intraobserver reliability and validity of the Vancouver classification system of periprosthetic femoral fractures after hip arthroplasty. *J Arthroplasty.* 2012; 27:1047-50.
11. Rayan F, Dodd M, Haddad FS. European validation of the Vancouver classification of periprosthetic proximal femoral fractures. *J Bone Joint Surg Br.* 2008; 90:1576-9.

12. Duncan CP, Masri BA. Fractures of the femur after hip replacement. *Instr Course Lect.* 1995; 44:293-304.
13. Beals RK, Tower SS. Periprosthetic fractures of the femur. An analysis of 93 fractures. *Clin Orthop Relat Res.* 1996; (327):238-46.
14. Bethea JS 3rd, De Andrade JR, Fleming LL. Proximal femoral fractures following total hip arthroplasty. *Clin Orthop Relat Res.* 1982; (170):95-106.
15. Johansson JE, McBroom R, Barrington TW. Fracture of the ipsilateral femur in patients with total hip replacement. *J Bone Joint Surg Am.* 1981; 63:1435-42.
16. Mont MA, Maar DC. Fractures of the ipsilateral femur after hip arthroplasty. A statistical analysis of outcome based on 487 patients. *J Arthroplasty.* 1994; 9:511-9.
17. Katzer A, Ince A, Wodtke J. Component exchange in treatment of periprosthetic femoral fractures. *J Arthroplasty.* 2006; 21:572-9.
18. Grammatopoulos G, Pandit H, Kambouroglou G. A unique peri-prosthetic fracture pattern in well fixed femoral stems with polished, tapered, collarless design of total hip replacement. *Injury.* 2011; 42:1271-6.
19. Ninan TM, Costa ML, Krikler SJ. Classification of femoral periprosthetic fractures. *Injury.* 2007; 38:661-8.
20. Brady OH, Garbuz DS, Masri BA, Duncan CP. The treatment of periprosthetic fractures of the femur using cortical onlay allograft struts. *Orthop Clin North Am.* 1999; 30(2):249-57.
21. Parvizi J, Rapuri VR, Purtill JJ. Treatment protocol for proximal femoral periprosthetic fractures. *J Bone Joint Surg Am.* 2004; 86(2):8-16.
22. Haddad FS, Duncan CP, Berry DJ. Periprosthetic femoral fractures around well-fixed implants: use of cortical onlay allografts with or without a plate. *J Bone Joint Surg Am.* 2002; 84-A(6):945-50.
23. Mihalko WM, Beaudoin AJ, Cardea JA, Krause WR. Finite-element modelling of femoral shaft fracture fixation techniques post total hip arthroplasty. *J Biomech.* 1992; 25(5):469-76.
24. Wong P, Gross AE. The use of structural allografts for treating periprosthetic fractures about the hip and knee. *Orthop Clin North Am.* 1999; 30(2):259-64.
25. Wilson D, Frei H, Masri BA. A biomechanical study comparing cortical onlay allograft struts and plates in the treatment of periprosthetic femoral fractures. *Clin Biomech (Bristol, Avon).* 2005; 20(1):70-6.
26. Emerson RH Jr, Malinin TI, Cuellar AD. Cortical strut allografts in the reconstruction of the femur in revision total hip arthroplasty. A basic science and clinical study. *Clin Orthop Relat Res.* 1992; (285):35-44.
27. Dennis MG, Simon JA, Kummer FJ. Fixation of periprosthetic femoral shaft fractures occurring at the tip of the stem: a biomechanical study of 5 techniques. *J Arthroplasty.* 2000; 15(4):523-8.