



ISSN (P): 2521-3466
ISSN (E): 2521-3474
© Clinical Orthopaedics
www.orthoresearchjournal.com
2023; 7(3): 29-33
Received: 01-06-2023
Accepted: 05-07-2023

Dr. Suhail Shabnum Wani
PG Scholar, Orthopaedics,
Government Medical College,
Srinagar, Jammu and Kashmir,
India

Dr. Mir Sami Ullah
Senior Resident, Orthopaedics,
Government Medical College,
Srinagar, Jammu and Kashmir,
India

Dr. Shariq Hussain Malik
PG Scholar, Orthopaedics,
Government Medical College,
Srinagar, Jammu and Kashmir,
India

Corresponding Author:
Dr. Shariq Hussain Malik
PG Scholar, Orthopaedics,
Government Medical College,
Srinagar, Jammu and Kashmir,
India

Minimally invasive percutaneous plate osteosynthesis technique in proximal tibia fractures

Dr. Suhail Shabnum Wani, Dr. Mir Sami Ullah and Dr. Shariq Hussain Malik

DOI: <https://doi.org/10.33545/orthor.2023.v7.i3a.415>

Abstract

Treatment options in proximal tibia fractures vary from closed reduction, cast immobilization, nailing to open reduction and internal fixation with plating. We conducted a study on management of these fractures by using minimally invasive plate osteosynthesis (MIPO) technique. The aim of this study was to evaluate the efficacy of minimally invasive plate osteosynthesis (MIPO) technique in the management of proximal tibia fractures. This study was conducted in the Department of Orthopaedics of Govt. Medical College Srinagar. This was study a prospective study where 30 patients with proximal tibia fractures were enrolled. Mean age of patients was 47.23 years (range 20-70 years). The enrolled patients were evaluated from the emergency department. The mean operative time was 49.57 minutes. Mean time for radiological union was 15.6 weeks. Superficial wound infection was found in 5(16.67%) patients, which resolved with daily dressings and antibiotics. Delayed union occurred in 3(10%) of patients and nonunion in 1(3.33%) patients. Wound necrosis found in 2(4%) patients. Minimally invasive plate osteosynthesis (MIPO) technique in the treatment of proximal tibia fractures gives stable as well as optimal internal fixation and complete recovery of limb function at an early stage with minimal risk of complications.

Keywords: Proximal tibia fractures, minimally invasive surgical procedure, plate, osteosynthesis

Introduction

Fractures of the proximal tibia are serious injuries and presents a treatment challenge as the damage in such fractures is usually extensive. Open fractures, compartment syndrome, and neurovascular injuries are commonly associated with such injuries ^[1, 2]. Proximal tibia fractures are the common fractures of the lower extremity resulting from high-energy trauma, such as motor vehicle accidents, fall from height, direct blow, and sports injury ^[3].

The aim of treatment in proximal tibial fractures is to obtain early union of fracture in the most acceptable anatomical position with early and maximum functional return of activity. There are number of treatment modalities available for proximal tibia fractures as closed reduction and cast application, closed reduction and external fixation, closed reduction and internal fixation, open reduction and internal fixation. Each method has its own advantages and disadvantages. Minimally invasive percutaneous plate fixation has gained wide acceptance for treating such fractures ^[4-11]. The theoretical advantages of MIPPO technique includes minimal additional damage to the soft tissues in the fracture area, preservation of blood supply to fracture fragments, thereby providing suitable conditions for indirect fracture healing with callus formation.

Material and Methods

This prospective study was conducted in the Department of Orthopaedics, Govt. Medical College Srinagar from February 2020 to January 2021. In this study we enrolled 30 patients with proximal tibia fractures. Mean age of patients was 47.23 years (range 20-70 years). There were 16 male patients and 14 female patients. The enrolled patients were evaluated from the emergency department. Patients selected for the study underwent pre-anaesthetic checkup and radiographs of the affected limb in AP and lateral views.

All enrolled patients fulfilled inclusion criteria that involved

- Patients with proximal tibia fractures and give written consent for the procedure.
- Minimum age 18 years and maximum age 70 years.
- Acute proximal tibia fractures with intra or extra particular type.
- Patients with proximal tibia fractures with no neuro deficit.
- Closed A0 type B or C proximal tibia fractures.
- The exclusion criteria was patients who don't give consent, fractures with Gustilo Anderson grade 2 or more, established compartment syndrome, with neuro deficit, and comorbidities like Diabetes, immuno suppression, RA and need of ligament reconstruction, closed AO A type.

Procedure

The patients were operated under spinal or regional anaesthesia. Antibiotic prophylaxis in the perioperative period was given in all cases 30 minutes before application of tourniquet. In all cases, surgery was performed in the supine position, but the position of the lower leg differed according to the fracture location. All surgeries were performed with the use of an image intensifier. A triangle support or bolster was used to provide knee flexion at 30 to 60 degree. This facilitated radiographic control in the lateral view and also prevented posterior sagging of fracture fragment, thus helped in fracture reduction. Fracture reduction was achieved manually on a fracture table. An incision 3 to 4 cm long was performed at the level of proximal metaphysis according to the location of fracture. In case of an Intra-articular fracture, the reduction and fixation of joint fragments were performed as a first stage. Then the

subcutaneous or sub muscular tunnel was prepared with the use of an elevator for subsequent plate insertion. The plate was bent with pliers according to the contour of bone. After insertion of the implant, the position of bone fragments and plate was checked with an image intensifier. After proper reduction plate was fixed proximally and distally with provisional k wires. After reduction of fracture and position of plate was found satisfactory under image intensifier in both AP and lateral views. Proximal fragment was fixed with locking cancellous screws through the main incision. Distal fragment was fixed with cortical and locking screws percutaneously.

The choice of side of plate insertion, medial or lateral, was based on fracture type and location as well as on soft tissue condition. After fracture fixation was completed and final radiological evaluation of all components of fixation performed, the wounds were closed. Intravenous antibiotics were given in all cases for 3 days followed by orals after surgery.

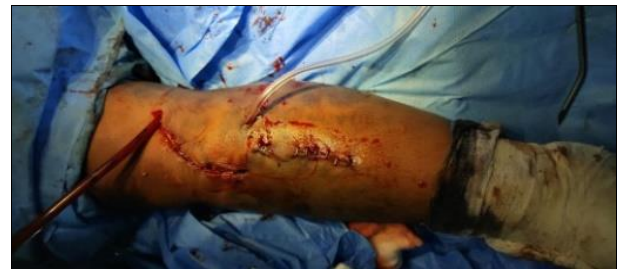

Fig 1: Active surgical drain

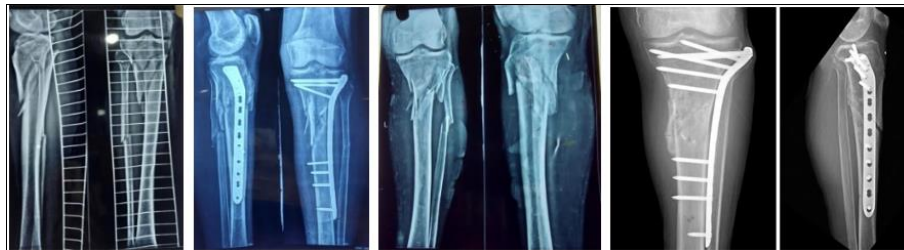

Fig 2: Some pre and post-operative radiographs

Post-operative Care

Rehabilitation was started on the second postoperative day with quadriceps setting and continuous passive motion of the knee joints. Postoperative radiographs were done on day one. Wound was inspected on the second postoperative day and sutures were removed on the 14th postoperative day. At time of the patients were encouraged to perform straight leg-raising exercise and active flexion of their knees and ankles, from tolerable range of motion followed by gradual increase of range similar to unaffected limb.

Follow UP

Patients were advised to follow up regularly in OPD. Toe-touch weight bearing with crutches was started at approximately 4 weeks postoperatively, and limited weight bearing was allowed only after obtaining radiographic evidence of healing. During the first 6 weeks after the surgery, only partial weight bearing was allowed. Then weight bearing increased according to clinical and radiologic union acquired at follow-up visits scheduled at 6 to 8, 12 to 14, and 18 to 20 weeks after surgery and further with 6-week intervals if needed until fracture union. At each visit we determined the ROM of operated limb and

assessed axial and rotational malalignment. Any wound complications or other consequences were noted. AP and lateral views were obtained at each visit and healing was assessed with these radiographs. The fracture was considered united if three of four cortices showed bony bridging and full weight bearing was pain free. If fracture union was not achieved by the sixth month after surgery, the situation was graded as delayed union and by the ninth month as nonunion. We assessed deformities in sagittal and frontal planes and shortening on standard long-leg radiographs. The joint orientation angles were used to assess axial deviation in frontal and sagittal planes. The length was assessed both clinically and radiographically.

Knee and ankle ranges of motion, limb rotations and alignment, and any sign of implant-associated complication were checked at all follow-up visits. Final clinical outcome was evaluated.

Results

In our study, 30 patients with proximal tibia fractures were treated with closed reduction and internal fixation by using minimally invasive plate osteosynthesis (MIPO) technique. Mean age of patients was 47.23 years (range 20-70 years). There were 16(53.33%) male patients and 14(46.67%) female patients.

Left side proximal tibia fracture was in 11(36.67%) patients and right side in 19(63.33%) patients. Out of 50 patients 17 (56.67%) fractures were caused by road accidents, 10(33.33%) by fall, 2(6.67%) were sports injury and 1(3.33%) caused by other reasons. Mean time from trauma to surgery was 8 days and majority of patients were operated within the first week of

trauma. The mean operative time was 49.57 minutes. Mean time for radiological union was 15.6 weeks. Superficial wound infection was found in 5(16.67%) patients, which resolved with daily dressings and specific antibiotics. Delayed union occurred in 3(10%) of patients and nonunion in 1(3.33%) patients and in 2(6.67%) of patients with wound necrosis occurred (table 1).

Table 1: Demography of patients

		No. of patients	Percentage
Gender	Male	16	53.33%
	Female	14	46.67%
Mode of trauma	Road accidents	17	56.67%
	Fall	10	33.33%
	Sports injury	2	6.67%
	Others	1	3.33%
Side of trauma	Right	19	63.33%
	Left	11	36.67%
Complications	Superficial infection	5	16.67%
	Delayed union	3	10.00%
	Non-union	1	3.33%
	Wound necrosis	2	6.67%

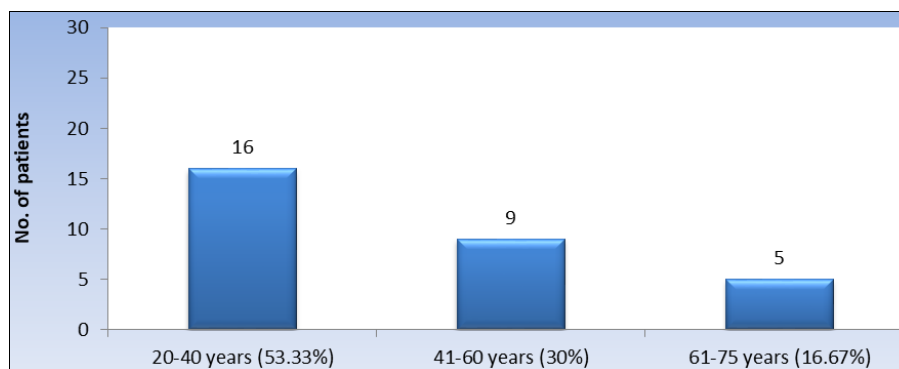


Fig 3: Distribution of patients on the basis of age group

This study shows that maximum patients 16(53.33%) belongs to age group of 20-40 years. The final assessment was done on the basis of bony and

functional results classified into four categories ranging from excellent to poor according to SJLAM criteria (1964) ^[12] table 2.

Table 2: Bony and functional results according to SJLAM criteria

Parameters	No. of patients	Percentage	6 weeks follow-up	12 weeks follow-up	Final follow-up
Excellent	21	70.00%	<ul style="list-style-type: none"> No pain Knee rom 80% X-ray- uniting 	<ul style="list-style-type: none"> No pain Knee rom 90% X-ray- uniting Full weight bearing 	<ul style="list-style-type: none"> No pain Knee rom 100% X-ray- united Full weight bearing
Good	6	20%	<ul style="list-style-type: none"> Pain Knee rom 60% X-ray- uniting 	<ul style="list-style-type: none"> Slight pain Knee rom 70% X-ray- uniting Full weight bearing 	<ul style="list-style-type: none"> No pain Knee rom 80% X-ray- united Full weight bearing
Fair	2	6.67%	<ul style="list-style-type: none"> Pain Knee rom 40% X-ray- uniting 	<ul style="list-style-type: none"> Pain Knee rom 50% X-ray- uniting 	<ul style="list-style-type: none"> Slight pain Knee rom 60% X-ray- united Full weight bearing
Poor	1	3.33%	<ul style="list-style-type: none"> Pain Knee rom 20% X-ray-no callus seen 	<ul style="list-style-type: none"> Pain Knee rom 20% X-ray-no callus seen 	<ul style="list-style-type: none"> Pain Knee rom 25% X-ray-no callus seen

In our study 21(70%) of patients had excellent results, 6(20%) patients had good results, 2(6.67%) patients had fair results and 1(3.33%) patients had poor results.

Discussion

Despite wide acceptance and assurance in possibilities of the

procedure, most reports are based on a small number of patients and the investigators report differing rates of wound complications, union time and function. Our aim was to estimate the rate of union, the rate of major and minor wound complications, occurrence of mal union, and level of function in proximal tibia fractures treated by minimally invasive plate

osteosynthesis (MIPO) technique. The limitations of this study was proximal tibia fractures with various degrees of soft tissue injuries, a large number of the patients (30) were included and restoration of weight bearing or resumption of working capacity in patients within one year after surgery.

Fractures of the proximal tibia are the results of high-energy injuries, and because of the lack of soft tissue coverage in this region, it is vulnerable. In such cases, the treatment of damaged soft tissues is of primary concern and disturbance of blood supply to the fracture site cannot be avoided, and thus, non-union and infection occur with high incidence. The rate of deep infection has been reported and most authors have reporting rates of 18% or more^[13, 14]. It is not always easy to reduce and adequately maintain fractures, especially fractures with articular involvement or comminuted proximal tibia fractures. Furthermore, mal-union, joint motion limitations, and patient inconvenience are main concerns.

Recently the use of intramedullary treatment for proximal tibia fractures was advocated^[15-17]. This minimally invasive technique can be performed without further stripping of the already damaged soft tissue envelope, and provides a load sharing device with superior stiffness. These characteristics may make locked plating as an attractive option for treating proximal tibia fractures. Along with the development of minimally invasive plate osteosynthesis (MIPO) the popularity of locking plates for the treatment of these complex fractures has significantly increased, presumably because they do not require large incisions or soft tissue stripping, and thus, minimize subsequent failures due to infection and non-union. Furthermore, locking plates do not disturb either endoseal or periosteal blood supplies to fracture sites, and thus, reduce the risks of resultant infection and non-union. The staged management of the proximal tibia fractures has been reported to provide a safe and useful strategy^[18, 19].

Rates of fracture union vary in the literature from 68.5%^[11] to 100%^[9]. Most authors report union in terms of 4 to 6 months after minimally invasive plate osteosynthesis (MIPO) technique in the treatment of proximal tibia fractures. Authors from Asia typically report shorter times to union, 4 to 4.5 months^[20, 21], than authors from Europe, 5 to 6 months^[5, 7, 9]. In our study fracture union was seen in 21(70%) of patients up to 6 months after surgery. Most current articles report about a lower level of these complications^[5-8, 20]. In this study, 4(13.33%) of patients had delayed union or nonunion, 3 patients among these 4 patients had severe injuries of soft tissues. When only fractures without major soft tissue injuries are taken into account, complications of delayed or nonunion was likely seen in patient. Minimization of the skin incision and further soft tissue injury within the fracture site should decrease the rate of wound complications. In our study, such complications were seen in 5 (16.67%) of patients, which is within the range reported in most studies. All wound infections in our series were late infection, which is consistent with data of Lau et al^[22]. Who revealed late infections in 15% of their cases? Like in the series of Lau et al., infection complications that were seen in our cases did not affect fracture healing and did not lead to chronic osteomyelitis. Most cited results are ROM in the adjacent joint and resumption of work and sport activity at follow up. Thus, Red fern et al^[9] reported that all their 20 patients had resumed their pre-injury level of activity. In our study out of 30 patients 28(93.33%) had completely resumed work activities.

Conclusion

Minimally invasive plate osteosynthesis (MIPO) technique in

the treatment of proximal tibia fractures gives stable as well as optimal internal fixation and complete recovery of limb function at an early stage. If soft tissue reconstruction can be performed adequately, MIPO may provide acceptable means of treating open fractures of the proximal tibia.

Conflict of Interest

None

Financial Support

No financial support was received for this study.

References

1. Starman JS, Castillo RC, Bosse MJ, MacKenzie EJ; LEAP Study Group. Proximal tibial metaphyseal fractures with severe soft tissue injury: Clinical and functional results at 2 years. *Clin Orthop Relat Res*. 2010;468(6):1669-75.
2. Tejwani NC, Achan P. Staged management of high-energy proximal tibia fractures. *Bull Hosp Jt Dis*. 2004;62(1-2):62-6.
3. Newman SD, Mauffrey CP, Krikler S. Distal metadiaphyseal tibial fractures. *Injury*. 2011;42:975-84.
4. Babst R, Khong K. Minimally invasive surgery. In: Ruedi TP, Buckley RE, Moran CG, eds. *AO Principles of Fracture Management*. Stuttgart, Germany; New York, NY, USA; c2007. p. 199-212.
5. Borg T, Larsson S, Lindsjo U. Percutaneous plating of distal tibia fractures. Preliminary results in 21 patients. *Injury*. 2004;35:608-614.
6. Collinge C, Sanders R, DiPasquale T. Treatment of complex tibial periarticular fractures using percutaneous technique. *Clin Orthop Relat Res*. 2000;375:69-77.
7. Hasenboehler E, Rikli D, Babst R. Locking compression plate with minimally invasive plate osteosynthesis in diaphyseal and distal tibial fracture: A retrospective study of 32 patients. *Injury*. 2007;38:365-370.
8. Maffulli N, Toms A, McMurtie A, Oliva F. Percutaneous plating of distal tibial fractures. *Int Orthop*. 2004;28:159-162.
9. Redfern DJ, Syed SU, Davies SJM. Fractures of the distal tibia: minimal invasive plate osteosynthesis. *Injury*. 2004;35:615-620.
10. Strecker W, Popp D, Keppler P. Torsional deformities following intramedullary nailing of femur and tibia. *Osteo Trauma Care*. 2004;12:215-218.
11. Williams T, Schenk W. Bridging-minimally invasive locking plate osteosynthesis (Bridging-MILPO): Technique description with prospective series of 20 tibial fractures. *Injury*. 2008;39:1198-1203.
12. Lam SJ. The place of delayed internal fixation in the treatment of fractures of the long bones. *J Bone Joint Surg*. 1964;46-B(2):393-7.
13. Young MJ, Barrack RL. Complications of internal fixation of tibial plateau fractures. *Orthop Rev*. 1994;23(2):149-54.
14. Bach AW, Hansen ST Jr. Plates versus external fixation in severe open tibial shaft fractures: a randomized trial. *Clin Orthop Relat Res*. 1989;(241):89-94.
15. Whittle AP, Russell TA, Taylor JC, Lavelle DG. Treatment of open fractures of the tibial shaft with the use of interlocking nailing without reaming. *J Bone Joint Surg Am*. 1992;74(8):1162-71.
16. Henley MB, Chapman JR, Agel J, Harvey EJ, Whorton AM, Swiontkowski MF. Treatment of type II, IIIA, and IIIB open fractures of the tibial shaft: a prospective comparison

- of unreamed interlocking intramedullary nails and half-pin external fixators. *J Orthop Trauma*. 1998;12(1):1-7.
17. Xue D, Zheng Q, Li H, Qian S, Zhang B, Pan Z. Reamed and unreamed intramedullary nailing for the treatment of open and closed tibial fractures: A subgroup analysis of randomised trials. *Int Orthop*. 2010;34(8):1307-13.
 18. Haidukewych GJ. Temporary external fixation for the management of complex intra-and periarticular fractures of the lower extremity. *J Orthop Trauma*. 2002;16(9):678-85.
 19. Ma CH, Wu CH, Yu SW, Yen CY, Tu YK. Staged external and internal less-invasive stabilisation system plating for open proximal tibial fractures. *Injury*. 2010;41(2):190-6.
 20. Gupta RK, Rohilla RK, Sangwan K, Singh V, Walia S. Locking plate fixation in distal metaphyseal tibial fractures: series of 79 patients. *Int Orthop*. 2010;34:1285-1290.
 21. Horan TC, Gaynes RP, Martone WJ, Jarvis WR, Emori TG. CDC definitions of nosocomial surgical site infections. A modification of CDC definitions of surgical wound infections. *Infect Control Hosp Epidemiol*. 1992;13:606-608.
 22. Lau TW, Leung F, Chan CF, Chow SP. Wound complication of minimally invasive plate osteosynthesis in distal tibia fractures. *Int Orthop*. 2008;32:697-703.

How to Cite This Article

Wani SS, Ullah MS, Malik SH. Minimally invasive percutaneous plate osteosynthesis technique in proximal tibia fractures. *National Journal of Clinical Orthopaedics*. 2023; 7(3): 29-33.

Creative Commons (CC) License

This is an open access journal, and articles are distributed under the terms of the Creative Commons Attribution-NonCommercial-ShareAlike 4.0 International (CC BY-NC-SA 4.0) License, which allows others to remix, tweak, and build upon the work non-commercially, as long as appropriate credit is given and the new creations are licensed under the identical terms.