



ISSN (P): 2521-3466
ISSN (E): 2521-3474
© Clinical Orthopaedics
www.orthoresearchjournal.com
2023; 7(1): 05-08
Received: 04-01-2023
Accepted: 11-02-2023

Dr. Parth P Thakor
Assistant Professor, Department
of Orthopaedics, Zydus Medical
College, Dahod, Gujarat, India

Dr. C Sai Sabharish Reddy
Assistant Professor, Department
of Orthopaedics, Zydus Medical
College, Dahod, Gujarat, India

Dr. Aditya K Agrawal
Professor, Department of
Orthopaedics, Dhiraj Hospital,
Smt BK Shah Medical Institute
& Research Centre, Sumandeep
Vidyapeeth Deemed to be
University, Waghodia,
Vadodara, Gujarat, India

Dr. Jeet Patel
Consultant Orthopaedic Surgeon,
Dahod, Gujarat, India

Dr. Sarvang M Desai
Professor & Head of
Department, Orthopaedics,
Dhiraj Hospital, Smt BK Shah
Medical Institute & Research
Centre, Sumandeep Vidyapeeth
Deemed to be University,
Waghodia, Vadodara, Gujarat,
India

Corresponding Author:
Dr. Parth P Thakor
Assistant Professor, Department
of Orthopaedics, Zydus Medical
College, Dahod, Gujarat, India

Extensor mechanism sparing para tricipital posterior approach to the distal humeral shaft fractures: An alternative approach for fracture treatment

Dr. Parth P Thakor, Dr. C Sai Sabharish Reddy, Dr. Aditya K Agrawal, Dr. Jeet Patel and Dr. Sarvang M Desai

DOI: <https://doi.org/10.33545/orthor.2023.v7.i2a.399>

Abstract

Introduction: Generally Anterolateral and posterior surgical approaches are most commonly used approaches for fractures of middle thirds and distal third of the humerus. In posterior approach, usually splitting of triceps is done for exploring humerus. We studied an alternative, triceps reflecting para tricipital approach which spares the extensor mechanism. We are using it for the lower third extra articular humerus fracture to achieve good exposure of humerus so as to avoid muscle splitting and gaining the early ROM range of motion^[1, 2].

Materials and Methods: We studied 15 skeletally mature distal humerus fractures at our center treated by Triceps sparing approach with minimum follow up for a period of 6 months. They were functionally assessed with MAYO score^[3], measurements of ROM and radiological union. Mean duration of follow up was 10 months with range from 6-14 months.

Results: The average Mayo score was 95 indicating an excellent performance with a mean functional ROM 132 degree with range from 120-140 degree. Only 1 patient had complication of infection which was not related to approach.

Conclusion: The triceps reflecting approach (TRA) is a valuable option for ORIF in distal shaft humerus fractures. The extensor mechanism-sparing Paratricipital approach is an invaluable approach for fixation of lower third fractures of the humerus without negative effects on triceps strength. The clinical outcome parameters of our series revealed excellent maintenance of strength compared to the contralateral side. This approach gives us liberty to mobilize elbow joint actively as well passively and also avoids complications related to triceps adhesions.

Keywords: MAYO score, ROM, posterior approach, triceps reflecting approach, distal shaft humerus fractures

Introduction

Humerus fractures account for 4% to 6% and 1% to 3% of all fractures respectively in both young and elderly patients^[4, 5]. Distal humerus in the adult comprise approximately one third of all humeral fractures^[6]. Generally Anterolateral and posterior surgical approaches are most commonly used approaches for fractures of middle thirds and distal third of the humerus. In posterior approach usually splitting of triceps is done for exploring humerus.

The radial nerve is identified medial to the long and lateral heads of the triceps, while it is approximately 2 centimeters proximal to the deep head of the triceps and leaves the posterior compartment through piercing the lateral intramuscular septum approximately 10 centimeters proximal to the radio-capitellar joint. Dissection and attainment of an adequate operative field in mid to distal humerus fracture is dangerous and limited due to the anatomical course of the radial nerve.

We studied an alternative, triceps reflecting approach. We are using it for the lower third of humerus to achieve good exposure of humerus so as to avoid muscle splitting and spares the extensor mechanism of elbow^[1, 2].

The aim of this study was to observe the clinical and functional outcome of extra-articular distal shaft humerus fractures treated with triceps reflecting approaches.

Materials and Method

The study was conducted at tertiary care rural hospital from June 2016 to July 2017. Closed distal shaft humerus fractures, presenting to our outpatient clinics as well as Emergency Room in patients more than 18 years were selected as inclusion criteria. All patients were subjected to radiographs of the injured humerus in antero-posterior view (AP) and lateral (Lat) view. Mode of injury, patient demographics and AO fracture classification were noted.

Surgical Approach

The patient was positioned in the lateral decubitus position on with side support on radiolucent simple table. A midline straight skin incision was made extending as per requirement from acromion process to the tip of the olecranon. The fascia overlying the triceps brachii was identified, split in the midline, and elevated with the dermis and subcutaneous tissue, creating two fascio-cutaneous flaps on the sides. Dissection was continued to the lateral triceps border with the posterior aspects of the intermuscular septae. In this way, the triceps muscle was separated from the posterior surface of the intermuscular septae. On the lateral side, the radial nerve and its concomitant vessels were identified passing from the posterior to the anterior compartment through the intermuscular septum if proximal dissection was needed. The postero-lateral humeral shaft was approached by elevating the triceps muscle from the posterior periosteum and by retracting it medially. Often, triceps muscle was elevated from lateral, posterior as well as medial aspect after identifying the ulnar nerve. This way entire fracture was expose and reduced with the help of clamps, Kirschner - wires and inter-fragmentary screws as required supplemented with placed plate-screws. A drain was placed under the triceps muscle and the subcutaneous tissue and skin were closed in layers. Gentle active motion of the elbow was encouraged post-operatively when pain and swelling had subsided^[9].

The functional outcome of patients was assessed using MAYO scoring system. Radiographs were taken in the post-operative period at 4 weeks, 8 weeks, 12 weeks, 6 months, 8 months, 10 months and 12 months duration were analyzed for signs of bony union or complications (non-union, avascular necrosis, implant failure, radial palsy etc.).

Results

15 patients with extra-articular distal humerus shaft fractures surgically treated using the extra-articular distal humeral locking plate approached by the triceps-reflecting posterolateral approach. The outcome was assessed using the MAYO score, range of motion at the elbow and the time to union. The average time to radiographic fracture union was 12 weeks.

The mean duration of follow-up was 12 months (range 6 to 14 months). Mean age of 43.23 years (range 25-70 years). 5 patients were female, and 10 were male, of which 3 female were young adults (<50 years) and 2 were in older age group (above 60 years) while all 10 males were young. Mean flexion of the elbow at final follow up in our study was 132 degree (range: 120 - 140) with mean flexion deficit compared to other uninjured side of 8 degrees. Mean extension in our study was up to 12 degrees, range 10-15 (normal 5 to -15 degree) with mean extension deficit of 3 degrees compared to other side. No iatrogenic nerve injury was encountered in our study. There was only one case with superficial infection that resolved with surgical drainage, debridement and systemic antibiotics for 3 weeks. Radiological as well as clinical union was achieved in all patients. The average time to union was 2.4 ± 1.6 months (range:

2 to 4). At the final follow-up, according to the Mayo Elbow Score⁹, 14 patients achieved an excellent result, 1 patient had fair result. The average score was 96.4 points (range: 70 to 100).

Discussion

The aim of this study was to observe the clinical and functional outcome of extra-articular distal humerus fractures treated with triceps sparing approaches.

Various surgical approaches to the distal humerus have been described over past decades. Each fracture needs its appropriate exposure and in cases of intra-articular involvement the exposure of the articular surface. Olecranon osteotomy, the triceps splitting, triceps sparing, and triceps lifting approaches being the most frequently performed approaches in the surgical treatment of distal humerus fractures, we will be giving an overview of the established approaches offering selected indications and an evaluation of the related published data. The various types of posterior approach for distal humerus are there but in this study, we have included only diaphyseal and lower third fractures, so will discuss only about triceps spitting and triceps sparing approaches

1. Triceps sparing approach

After a posterior midline incision, a window on the lateral side of the triceps is created by elevating it off the posterior border of the intermuscular septum and posterior humerus. The radial nerve is being identified and mobilized for its protection. Not detaching the triceps from its insertion, the extensor mechanism for the elbow is preserved. Indication is open reduction with internal fixation (ORIF). In extra-articular or simple articular fractures. Main advantage of triceps sparing approach is avoiding injury to triceps muscle and exposure of articular surface is wider than triceps splitting approach. The disadvantage is view of the distal articular surface is relatively impaired and that it requires a little longer incision for adequate exposure.

2. Triceps splitting approach

After a posterior median incision, an interval between the long and lateral heads of the triceps established. The medial head comes into view and a split along its muscle fibers perform the split is prolonged over the olecranon subperiosteally, while preserving the connection between the flexor carpi ulnaris and anconeus muscle. This approach has been well established in treatment of distal diaphyseal fractures and intraarticular fractures (AO type C)^[10].

The triceps split approach does not utilize a true Internervous or intermuscular plane and theoretically can lead to more fibrous tissue formation, but one study reported that triceps split approach does not appear to cause significant muscle dysfunction. Remis *et al.* directly compared a triceps sparing approach to a triceps splitting approach. They used triceps sparing approach described by Bryan and Morrey in nine of their patients with AO/OTA TYPE C distal humerus fractures and triceps splitting approach in 6 patients with AO/OTA TYPE C distal humerus fractures. They concluded that there was no difference in elbow ROM or triceps deficit^[9]. Emmanuel *et al.* compared the outcomes after triceps splitting versus triceps sparing approach in extra articular distal humerus fractures (AO/OTA TYPE A) and they reported better elbow ROM and triceps strength with triceps sparing approach as compared to triceps splitting approach^[10]. However, both these approaches had similar functions outcome as per DASH scores.

Similar study was done by Lukas *et al.*^[11] found mean flexion of injured limb was 138 as compared to 139 in normal

limb. Another study done by Jagdeep Singh *et al* on Functional Outcomes after Triceps Splitting versus Triceps Sparing Approach for Extra-Articular Distal Humerus Fractures. Their results were average flexion in triceps splitting 126.0 ± 10.0 as compared to triceps sparing 140.0 ± 4.0 and extension contracture was 24.0 ± 8.0 as compared to triceps sparing 5.0 ± 6.0 . DASH score of triceps splitting was 30.41 ± 14.36 as compared to triceps sparing 24.28 ± 10.14 .

Limitation of our study is small sample size and shorter follow up. Future studies are required to validate our results. Although surgical treatment has provided a more stable reduction and alignment and predictable return to function, but it has been associated with complications like iatrogenic radial nerve palsy, infection, non-union and Implant failure [7, 8], which in the present series we retrospectively analyzed and found minimal complications with this approach.

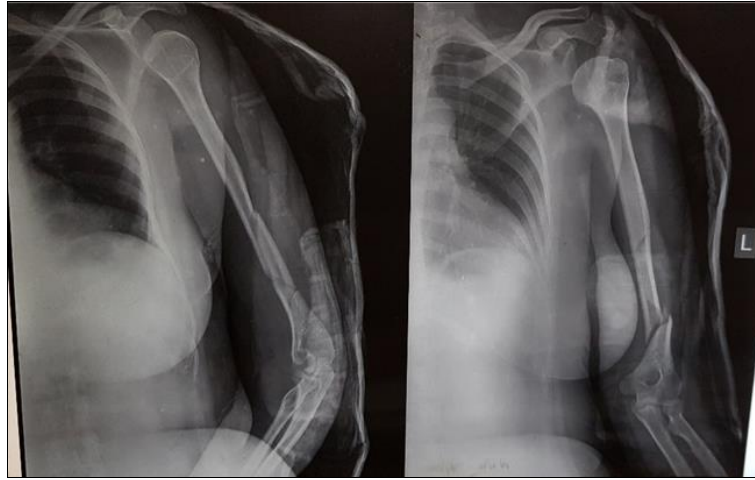


Fig 1: Pre-operative radiograph of 34 years gentleman with lower third shaft humerus fracture

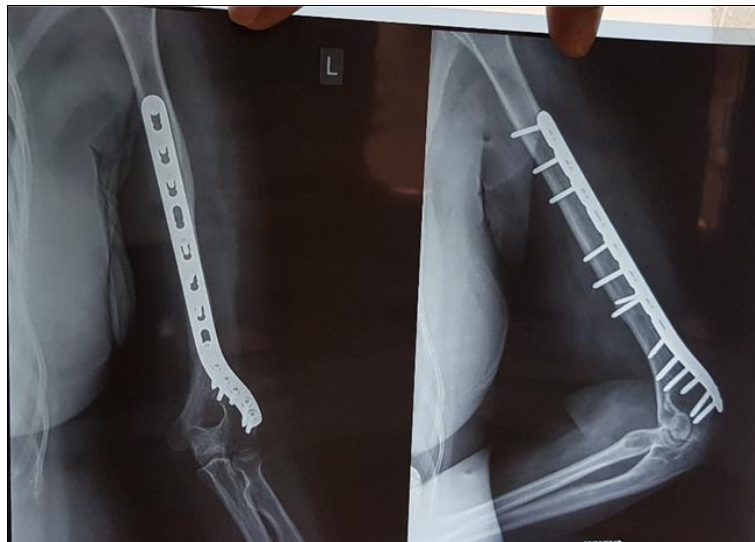


Fig 2: Post-operative radiograph of lower third humerus fracture fixed with extra articular distal humerus plate

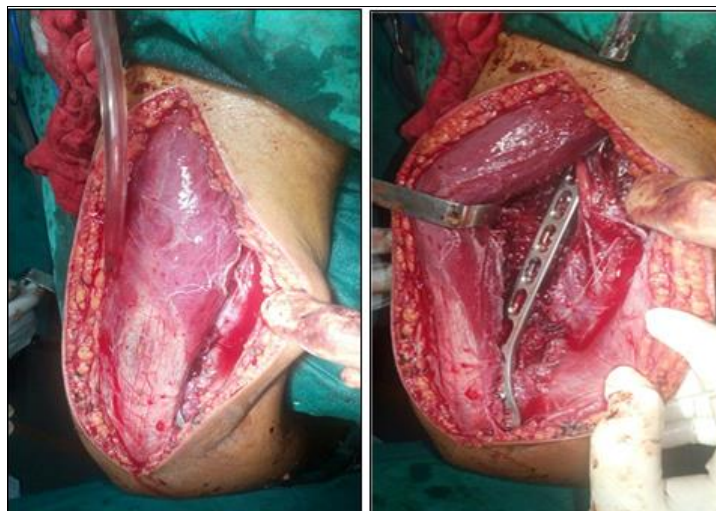
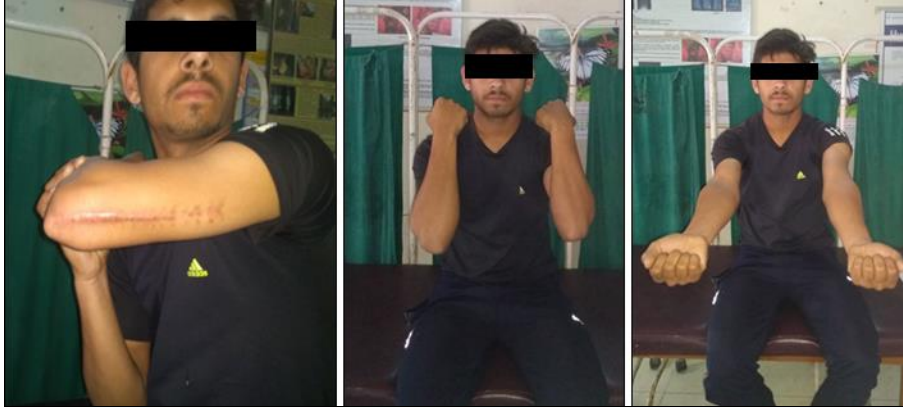

Fig 3: Intra-op pictures showing triceps reflecting approach with extra articular distal humerus plating**Fig 4:** Follow up at 12 months shows full range of movements of the elbow joint.**Conclusion**

The triceps reflecting approach (TRA) is a valuable option for ORIF in distal shaft humerus fractures. The clinical outcome parameters of our series revealed excellent maintenance of strength compared to the contralateral side. This approach gives us liberty to mobilize elbow joint actively as well passively and also avoids complications related to triceps adhesions.

Acknowledgement

Not available

Conflict of interest

None

Financial Disclosure

None

Institutional Ethics Committee Approval

Taken

References

1. Athwal GS, Rispoli DM, Steinmann SP. The anconeus flap transolecranon approach to the distal humerus. *J Orthop Trauma*. 2006;20(4):282-285.
2. Wilkinson JM, Stanley D. Posterior surgical approaches to the elbow: a comparative anatomic study [see comment]. *J Shoulder Elbow Surg*. 2001;10(4):380-382.
3. Umile Giuseppe Longo, Francesco Franceschi, Mattia Loppini, Nicola Maffulli, Vincenzo Denaro, Rating systems for evaluation of the elbow, *British Medical Bulletin*. 2008 Sept;87(1):131-161.
4. Ward EF, Savoie FH, Hughes JL. Fractures of the diaphyseal humerus. In: Browner BD, Jupiter JB, Levine AM, eds. *Skeletal trauma: fractures, dislocations, ligamentous injuries*. Philadelphia: Saunders, 1992, 1177-1200.
5. Schemitsch EH, Bhandari M, Talbot M. *Skeletal Trauma: Basic Science. Management and Reconstruction*. Philadelphia: Saunders; Fractures of the humeral shaft. 2008;2(4):1593-1594.
6. Anglen J. Distal humerus fractures [review]. *J Am Acad Orthop Surg*. 2005;13:291-297.
7. Shao YC, Harwood P, Grotz MR, Limb D, Giannoudis PV. References Radial nerve palsy associated with fractures of the shaft of the humerus: A systematic review. *J Bone Joint Surg Br*. 2005;87(12):1647-1652.
8. Holsetin A, Lewis GM. Fractures of the humerus with radial-nerve paralysis. *J Bone Joint Surg Am*. 1963;45(7):1382-1388.
9. Schildhauer TA, Nork SE, Mills WJ, Henley MB. *J Orthop Trauma*. 2003 May; 17(5):374-8.
10. Poon Peter, Young Simon, Foliaki Supileo, Eisenhauer David. Triceps Split and Snip approach to the elbow: Surgical technique and biomechanical evaluation. *ANZ Journal of surgery*. 2013 Oct;83(10):774-778. doi:10.1111/ans.12131.
11. Iselin LD, Mett T, Babst R, Jakob M, Rikli D. The triceps reflecting approach (Bryan-Morrey) for distal humerus fracture osteosynthesis. *BMC Musculoskelet Disord*. 2014;15:406. Published 2014 Dec 4. doi:10.1186/1471-2474-15-406
12. Singh J, Kalia A, Dahuja A, Bansal K. Functional Outcomes after Triceps Splitting versus Triceps Sparing Approach for Extra-Articular Distal Humerus Fractures. *Open Journal of Orthopedics*. 2018;8(3):85-94. <https://doi.org/10.4236/ojo.2018.83011>

How to Cite This Article

Thakor PP, Reddy CSS, Agrawal AK, Patel J, Desai SM. Extensor mechanism sparing Para tricipital posterior approach to the distal humeral shaft fractures: an alternative approach for fracture treatment. *National Journal of Clinical Orthopaedics* 2023; 7(1): 05-08.

Creative Commons (CC) License

This is an open access journal, and articles are distributed under the terms of the Creative Commons Attribution-NonCommercial-ShareAlike 4.0 International (CC BY-NC-SA 4.0) License, which allows others to remix, tweak, and build upon the work non-commercially, as long as appropriate credit is given and the new creations are licensed under the identical terms.