



ISSN (P): 2521-3466
 ISSN (E): 2521-3474
 © Clinical Orthopaedics
www.orthoresearchjournal.com
 2022; 6(2): 01-04
 Received: 01-02-2022
 Accepted: 03-03-2022

Dr. Muneeb Ul Islam
 PG Scholar, Department of
 Orthopedics, Govt. Medical
 College Srinagar, Jammu and
 Kashmir, India

Dr. Mudasir Nazir Bhat
 Senior Resident, Department of
 Orthopedics, Govt. Medical
 College Srinagar, Jammu and
 Kashmir, India

Dr. Basharat Mumin
 PG Scholar, Department of
 Radiodiagnosis, SKIMS, Soura,
 Srinagar, Jammu and Kashmir,
 India

Corresponding Author:
Dr. Muneeb Ul Islam
 PG Scholar, Department of
 Orthopedics, Govt. Medical
 College Srinagar, Jammu and
 Kashmir, India

Location of anterior cruciate ligament tears: A prospective study using magnetic resonance imaging

Dr. Muneeb Ul Islam, Dr. Mudasir Nazir Bhat and Dr. Basharat Mumin

DOI: <https://doi.org/10.33545/orthor.2022.v6.i2a.356>

Abstract

Introduction: Knee injuries associated with ligament injuries are common among population because of increasing indulgence in sports. Most common ligament injured is Anterior Cruciate Ligament. The incidence of ACL injury has increased in the general population with the rise of participation in sports. Approximately 70% of all ACL injuries occur by noncontact mechanisms. ACL deficiency causes knee instability so decreases the performance of sports person in sports. Patient needs clinical and diagnostic MRI to see the status of ACL and other structures in the knee and to ascertain what sort of treatment patient needs conservative or operative. Even though the arthroscopy is the gold standard for diagnosing ACL tears but a non-invasive and less expansive MRI is preferred.

Aims and Objectives: To find out location of ACL tear within the knee joint.

Materials and Methods: This prospective study was held from February 2021 to December 2021 in orthopedic department of Govt. Medical College Srinagar for diagnosing site of ACL tear in the knee joint using Magnetic Resonance Imaging modality. This study consisted of 50 patients both males and females. Patients with age group 20 to 45 years were included in the study with history of knee trauma associated with functional knee instability with positive Lachman test, pivot shift test and anterior drawer test. Patients with previous ACL surgery and fractures around the knee were excluded.

Results: In our study of 50 patients, 32(64%) patients were males and 18 patients (36%) were females. In 60% of patients had right side knee ACL tear. Majority of patients were in 25 -29 years of age group. Mean time from injury to MRI was 10+-7days (range 0-35days). Most common mechanism of ACL tear was sports injury in 30(60%) patients. Road Traffic Accident was in 15(30%) patients and others in 5(10%) patients. Majority of the ACL tears were intrasubstance tears with type III seen in 48% Of patients seen on MRI.

Conclusion: Main findings were that 44% of the ACL tear were located in proximal quarter of ACL with 20% tears type I and 22% tears type II. Majority of the tears were type three with 48% Incidence.

Keywords: Knee injury, ACL tear

Introduction

Knee injuries associated with ligament injuries are common among population because of increasing indulgence in sports. Most common ligament injured is Anterior Cruciate Ligament. The incidence of ACL injury has increased in the general population with the rise of participation in sports [1, 2, 3]. The spectrum of ACL injury includes partial sprain (grade 1 or 2) to complete disruption (grade 3). An estimated annual incidence of ACL rupture in the general population is 35 per 100000 people [4]. Approximately 70% of all ACL injuries occur by noncontact mechanisms [5]. The typical mechanism of ACL rupture sudden change in direction on the weight-bearing knee that results in twisting or a valgus strain of the knee [6]. It typically occurs in movements associated with deceleration, cutting maneuvers, or jump landings [7]. ACL deficiency causes knee stability so decreases the performance of sports person in sports. Patient needs clinical and diagnostic MRI to see the status of ACL and other structures in the knee and to ascertain what sort of treatment patient needs conservative or operative. The Anterior Drawer test, Lachman test, and pivot shift tests are most commonly used clinical tests to diagnose ACL tears. Even though the arthroscopy is the gold standard for diagnosing ACL tears but a noninvasive and less expansive MRI is preferred [8].

MRI is now first line investigation for suspected injuries. Increased soft tissue contrast, multiplanar slice capability, improved signal to noise ratio (SNR), higher resolution and no use

of radiation are its advantages [9, 10].

Most of ACL tears are complete around 80% with 90% of these tears intra substance in middle one third of ACL. Some 7% of ACL tears occur near femoral attachment and 3% near tibial attachment. Around 20% of ACL tears are incomplete with partial disruption of ACL fibers [11].

Materials and Methods

This is a prospective study held from February 2021 to December 2021 in orthopaedic department of govt medical college Srinagar for diagnosing site of ACL tear in the knee joint using Magnetic Resonance Imaging modality. This study consisted of 50 patients both males and females. Patients with age group 20 to 45 years were included in the study with history of knee trauma associated with functional knee instability with positive Lachman test, pivot shift test and anterior drawer test. Patients with previous ACL surgery and fractures around the knee were excluded.

MRI Analysis

Informed consents were taken for MRI. Patients were made to lie supine position with knee in a closely coupled HD transmit array coil. To visualize the ACL fully on sagittal images knee was externally rotated 15-20 degree. Knee was examined in three standard planes- sagittal, axial and coronal. T1 and T2 images with slice thickness of 3mm were taken. Images for ACL tear were studied in detail. ACL was studied from distal to proximal on sagittal planes to assess tear location. The coronal and sagittal planes were then assessed to confirm the tear location. In case of spiral tear of ACL was noted, the tear location was defined as the middle portion of the spiral part of ACL tear.

Classification of ACL tears

All ACL tears were classified according to sherman *et al.* [12] and ACL preservation treatment algorithm [13, 14]. Type I tear (proximal avulsion tear, located at >90% of distal-proximal length). Type II tear (proximal tear, located at 75%-90% of distal-proximal length). Type III tear (mid-substance tear, located at 25%-75% of distal-proximal length). Type IV tear (distal tear, located at 10%- 25% of distal-proximal length) or Type V tear (distal avulsion tear, located at <10% of distal -proximal length). Type I and Type V tears were further classified as soft tissue avulsion tears or bony avulsion tears. If anteromedial and posterolateral bundles were seen torn at different levels, the tear locations of both separate bundles were noted.

Results

In our study of 50 patients, 32(64%) patients were males and 18 patients (36%) were females. In 60% of patients had right side

knee ACL tear. Majority of patients were in 25 -29 years of age group. Mean time from injury to MRI was 10+-7 days (range 0-35days). Most common mechanism of ACL tear was sports injury in 30(60%) patients. Road Traffic Accident was in 15(30%) patients and others in 5(10%) patients.

Table 1: Gender distribution

Gender	No. of patients	Percentage
Male	32	64%
Female	18	36%
Total	50	100%

Majority of the patients are males 64%.

Table 2: Age distribution

Age in years	No. of patients	Percentage
20-24	14	28%
25-29	18	36%
30-34	10	20%
35-40	8	16%

Majority of patients fall in 25-29 year age group.

Table 3: Side distribution

Side involved	No. of patients	Percentage
Right side	30	60%
Left side	20	40%
Total	50	100%

Majority of patients had right knee involved.

Table 4: Mode of injury

Mode of injury	No. of patients	Percentage
Sports related injury	30	60%
Road traffic accident	15	30%
Others	5	10%
Total	50	100%

Most of the patients had sports related knee injury.

Table 5: Incidence of ACL Tear types

Tear type	Location ^a ,%	Incidence ^b ,%	No. of patients
Type I	>90	20	10
Type II	75-90	22	11
Type III	25-75	48	24
Type IV	10-25	4	2
Type V	<10	6	3
Bundles differed ^b	-	0	
Total	-	100	50

^a tear of acl location indicates the length of distal remnant as percentage of ligament length.

^b Anteromedial and posterolateral bundles were torn at different sites in these tear types.

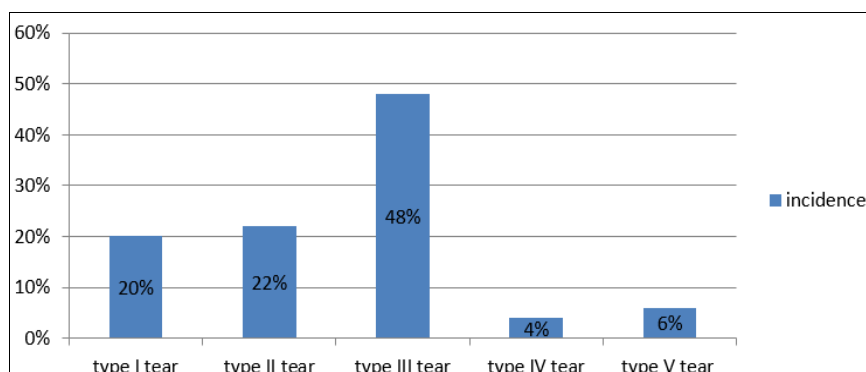


Fig 1: Incidence of ACL tears

Majority of patients have type three tear located at 25-75% length of ACL from distal to proximal.

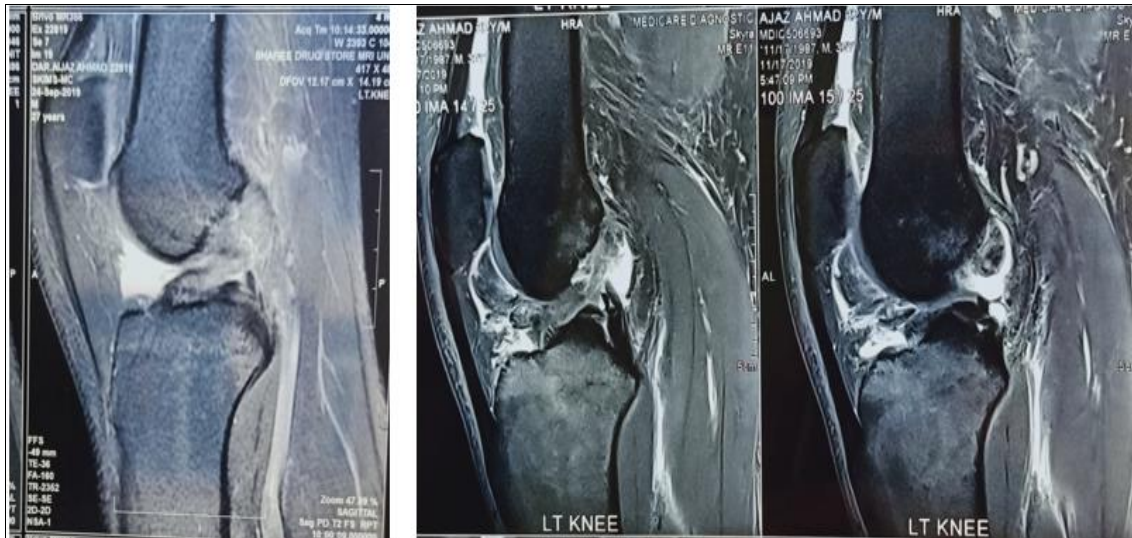

Fig 2: MRI showing intra substance tear type III.

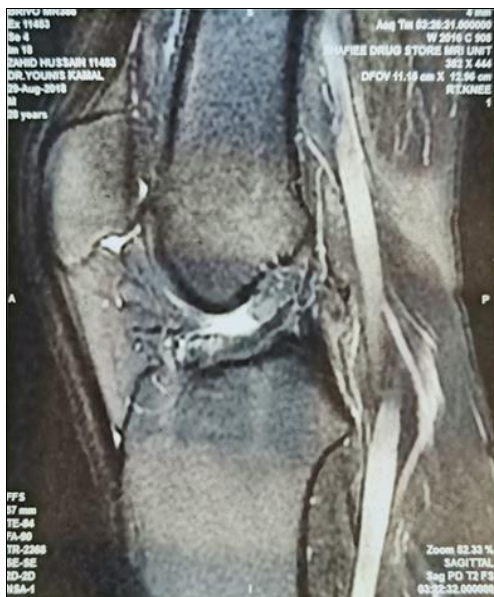

Fig 3: MRI showing type I tear.

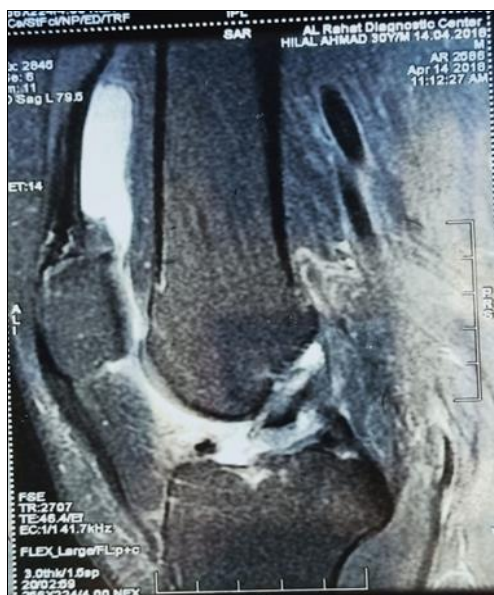

Fig 4: MRI showing tibial spine avulsion type V tear

Discussion

In this study different types of tears of ACL were identified on MRI. Majority of the patients had ACL tear due to sports injury in males. It was observed that 20% ACL tears were type I and type II tears were seen in 22%. In majority of patients of 48% had type III tears. Type IV and type V ACL tears were seen in 4% and 6% respectively. In this study we used the sherman classification system with 5 ACL tear locations on MRI. This improved the clinical application of classification system and hence interobserver agreement.

Frequently another method is used method to describe the location of ACL tear as the proximal, middle, or distal third. This classification however is not specific enough, as there is difficulty to differentiate between type I and type II tears. Furthermore as many tears occur around the proximal and distal third there is disagreement between observers to differentiate type I and type II tears. So we classify tears based on sherman classification as there is no confusion between the tears of proximal and middle third of ACL. Intraobserver reliability was good in this study however interobserver reliability was substantial. Disagreement mainly occurred between type II and type III tears. Sherman *et al.* [12] in their study noted that 13 out of 50 patients (26%) had type I tears, 15 out of 50 (30%) had type II tears, while 22 out of 50 (44%) had type III or IV tears, which is slightly higher in type I and type II and slightly less in type III tears than our study. Between 1986 and 1988 Grontvedt *et al.* [15] performed a randomized clinical trial in which 104 out of 147 patients (71%) had proximal third tears, which is significantly higher than findings in our study. This can be explained this way as most of the patients have a tear of ACL at the junction of the proximal third and middle third (22% according to the study of Sherman *et al.* [12]. In their study these patients might be classified as having a proximal third tear, whereas in our study they are categorised into middle-third tears.

Conclusion

The main findings were that 44% of the ACL tear were located in proximal quarter of ACL with 20% tears type I and 22% tears type II. Majority of the tears were type three with 48% incidence. Hence type three intra substance ACL tears are most commonly seen.

References

- 1 Ibrahim SAR, *et al.* Complications of ACL reconstruction. Kuwait Medical Journal. 2002;34(2):106-113.
- 2 Chen, Rosenberg T. ACL reconstruction with hamstring tendon, The Orthopedic Clinics of North America. 2003;34(1):9-18.
- 3 Kofp S, Forsythe B, Wong AK, Tashman S, Anderst W, Irrgang JJ, *et al.* Nonanatomic tunnel position in traditional transtibial single-bundle anterior cruciate ligament reconstruction evaluated by three-dimensional computed tomography, The Journal of Bone and Joint Surgery. American volume. 2010;92(6):1427-1431.
- 4 Gianotti SM, Marshall SW, Hume PA, Bunt L. Incidence of anterior cruciate ligament injury and other knee ligament injuries: A national population based study, Journal of Science and Medicine in Sport / Sports Medicine Australia. 2009;12(6):622-627.
- 5 Bien DP. Rationale and implementation of anterior cruciate ligament injury prevention warm-up programs in female athletes. J Strength Cond Res. 2011;25:271-285.
- 6 Perera NS, Joel J, Bunola J. Anterior cruciate ligament rupture: Delay to diagnosis, Injury. 2013;44(12):1862-186.
- 7 Bien DP. Rationale and implementation of anterior cruciate ligament injury prevention warm-up programs in female athletes. J Strength Cond Res. 2011;25:271-285.
- 8 Polly DW, Collaghan JJ, Sikes RA, McCabe JM, McMahon K, Savory CG. The accuracy of selective magnetic resonance imaging compared with the findings of arthroscopy of the knee. J Bone Joint Surg. 1988;70:192-8.
- 9 Mohankumar Rakesh, White Lawrence M, Naraghi Ali. Pitfalls pearls in MRI of the knee. Am J Roentgenol. 2014;203:516-30.
- 10 Oei EH, Nikken JJ, Verstijnen AC, Ginai AZ, Myriam HMG. MR imaging of the menisci and cruciate ligaments: A systematic review. Radiology. 2003;226(3):837-48.
- 11 Vahey TN, Broome DR, Kayes KJ, Shelbourne KD. Acute and chronic tears of the anterior cruciate ligament: differential features at MR imaging. Radiology. 1991;181:251-253.
- 12 Sherman MF, Lieber L, Bonamo JR, Podesta L, Reiter I. The long-term followup of primary anterior cruciate ligament repair. Defining a rationale for augmentation. Am J Sports Med. 1991;19:243-255.
- 13 Van der List JP, DiFelice GS. Preservation of the anterior cruciate ligament: A treatment algorithm based on tear location and tissue quality. Am J Orthop (Belle Mead NJ). 2016;45:e393-e405.
- 14 Van der List JP, DiFelice GS. Preservation of the anterior cruciate ligament: surgical techniques. Am J Orthop (Belle Mead NJ). 2016;45:E406-E414.
- 15 Grontvedt T, Engebretsen L, Benum P, Fasting O, Molster A, Strand T. A prospective, randomized study of three operations for acute rupture of the anterior cruciate ligament. Five-year follow-up of one hundred and thirty-one patients. J Bone Joint Surg Am. 1996;78:159-168.