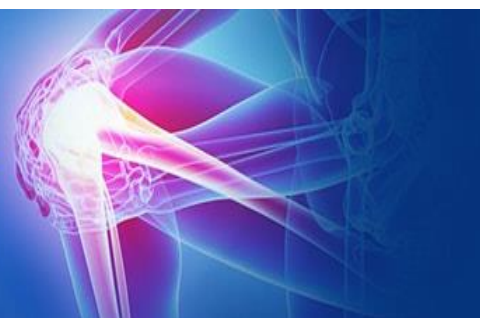



ISSN (P): 2521-3466
ISSN (E): 2521-3474
© Clinical Orthopaedics
www.orthoresearchjournal.com
2021; 5(3): 142-147
Received: 03-05-2021
Accepted: 04-06-2021

Dr. Neelanagowda V P Patil
Professor and HOD, Department
of Orthopaedics, MMCRI,
Mysore, Karnataka, India

Dr. E Saikrishana
Post Graduate, Department of
Orthopaedics, MMCRI, Mysuru,
Karnataka, India

Dr. Arun GR
Assistant Professor, Department
Of Orthopaedics, MMCRI,
Mysore, Karnataka, India

Technique of minimally invasive plating in mid clavicular fractures and its results

Dr. Neelanagowda VP Patil, Dr. E Saikrishana and Dr. Arun GR

DOI: <https://doi.org/10.33545/orthor.2021.v5.i3c.306>

Abstract

Aim: In this study we wanted to study the technique and pitfalls in minimally invasive plate osteosynthesis technique for displaced midshaft clavicular fractures (DMCFs) and assess its outcome.

Materials and Methods: The proposed study is a prospective non randomized control study on the management and treatment of clavicle fractures centered in K.R Hospital attached to the Government Medical College and research institute, Mysore during the term between January 2019 to December 2019. A Total of 31 Cases of Patients underwent internal fixation by MIPO using Pre-contoured locking compression plate. Patients were functionally assessed at the end of follow up period as per the CONSTANT MURLEY Shoulder outcome scoring system.

Results: Out of 31 patients, 87.1% of patients were below the age of 40 years in our study with Males (87.1%) and Females (12.9%). Most of the patients were operated within 3 days and Right sided fractures were more common than left sided (54.8% vs 45.2%). Average time of union was 13 weeks. Most of the cases did not have any complications except for hypertrophic scar in 2 patients, implant prominence in 3 patients, superficial infection in 1 patient.

Conclusion: Closed biological fixation using MIPO technique with locking Pre-contoured plate can preserve the blood supply of the fracture site and minimize soft-tissue related complications. Although it needs surgical expertise and proper technique for better results. MIPO technique with locking reconstruction plate is a feasible and worthwhile alternative for DMCFs.

Keywords: Minimally invasive plate osteosynthesis (MIPO), Displaced mid shaft clavicle fractures (DMCFs), Locking compression plate (LCP).

Introduction

Clavicle fractures are one of the most common injuries and more than two thirds of them occur in middle third of clavicle, accounting for 5% of all fractures and 44% of all shoulder fractures [1, 2, 3]. Most of the clavicular fractures occur in the midshaft and about half are displaced. Furthermore, it has been observed that there have been more complex patterns of injury with high velocity trauma [4, 5]. Clavicle midshaft fractures have classically been managed conservatively with figure of eight bandage and arm sling [6, 7].

However, due to displacement, comminution, and greater degrees of shortening, patients have reported greater degrees of dissatisfaction due to symptomatic malunion, nonunion and poor functional outcome with conservative management [8, 9, 10, 11]. Because of these factors not only do patients expect an earlier resumption of daily activities but also the outcome of non-operative treatment is not as favourable as surgeons expected in the past. So, there has been a trend toward operative treatment of clavicle mid shaft fractures. There are various methods for treating clavicle midshaft fractures, such as intramedullary K-wires or elastic stable intramedullary nailing and plate fixation. [12, 13, 14, 15, 16] Plate fixation provides stable anatomical fixation and locking compression plate (LCP), which are Pre-contoured to the shape of the clavicle are most commonly used [17].

Nevertheless, open surgical procedures are associated with a high incidence of soft tissue and implant related complications. Intramedullary titanium elastic nailing (TEN), as an alternative is associated with lesser soft tissue injury and a lower nonunion rate [18]. Unfortunately, malunion, nail migration or nail breakage, and rotational instability are the disadvantages of intramedullary nailing techniques [19, 20, 21].

Corresponding Author:
Dr. Neelanagowda V P Patil
Professor and HOD, Department
of Orthopaedics, MMCRI,
Mysore, Karnataka, India

Studies with Minimally invasive percutaneous plate osteosynthesis technique along With application of locking plate have been recently introduced, and have the advantage of maintenance of a good reduction along with the lack of periosteal stripping, and the same principle has been applied in treatment of mid shaft clavicle fractures with LCP using MIPO technique. In this study we reviewed 31 patients with clavicle mid piece Fractures Treated with MIPO Technique between January 2019 and December 2019 in our Hospital. We aimed to access functional and Radiological outcome of the mid clavicle fracture patients with MIPO technique using Locking Reconstruction plate.

Material and Methods

In our institution we treated 31 patients with displaced middle – third shaft clavicle fractures by MIPO using Pre-contoured locking compression plate between January 2019 and December 2019. Primary indication for surgery were displaced clavicle fractures, comminuted clavicle fractures and fractures with shortening of greater than 2 cms. Patients with open fractures, associated neurovascular injury, ipsilateral limb injuries and those who are not willing to give consent to participate in our study were excluded. After stabilizing the patient, routine pre-operative evaluation was done including Antero-posterior radiograph. All patients were operated within 3 days after injury. Finally 31 patients were included in our study. Patient’s consent was obtained prior to surgery and institutional ethical committee clearance was obtained before commencement of study

Surgical technique:

Operations of all patients were performed after Brachial plexus anaesthesia or general anaesthesia. The patient was positioned in a beach chair position on a radiolucent operating table Parts are Scrubbed, Painted and Draped. The head of the patient was

turned away from the operating site, fluoroscopic images were taken in neutral 30 degrees cranial and caudal for determining the displacement of fracture. Two incisions of 2-3cms each were put over the clavicle on medial and lateral thirds of clavicle leaving the fracture site skin intact. Incision was deepened, a sub deltoid and subpectoralis extra periosteal tunnel was then created with blunt dissection using a Bristow periosteal elevator. The fracture was reduced and the Pre-contoured Locking Reconstruction plate was inserted from lateral to medial. Two 3.0-mm threaded k-wires were inserted into the anterior surface of the clavicle adjacent to the fracture ends, and super inferior displacement was reduced using the joystick technique (figure 1). While one assistant maintained super inferior alignment of the fracture, reduction status was confirmed under an image intensifier on the AP view. For pressurized Fixation two 3.5mm cortical screws were planted into both sides closer to Fracture area. After tested under Fluoroscope we removed K-wires to plant Additional one or two locking screws on both sides to complete the Fixation (figure 3). Finally two incisions were sutured after irrigation and hemostasis (figure 4). Then dressing was done with Bandages. After operation arm sling was used to support upper limb. Antibiotics were used for Five days to prevent Infection. Patient was encouraged to perform exercises as gentle pendulum exercises with arm sling from first post-operative day. Patients were advised exercise initiation after two weeks, and without arm sling 5 wks after surgery. Sutures were removed during second week after surgery.

Follow Up

The patients were followed up at intervals of, 6 weeks, 12 weeks, 16 weeks, 24 weeks, to assess the radiological union (figure 5). Patients were functionally assessed at the end of follow up period as per the CONSTANT MURLEY Shoulder outcome scoring system (figure 6).

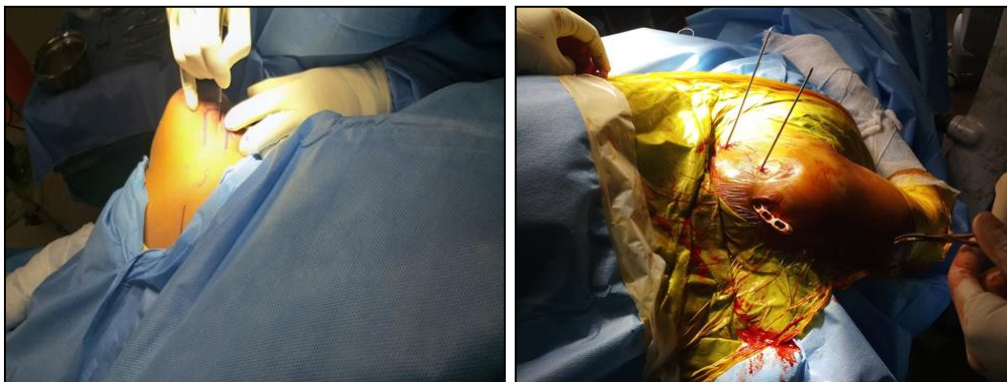


Fig 1: Showing incisions and fracture reduction using two 3.0mm k wires and pre-contoured LCP temporarily

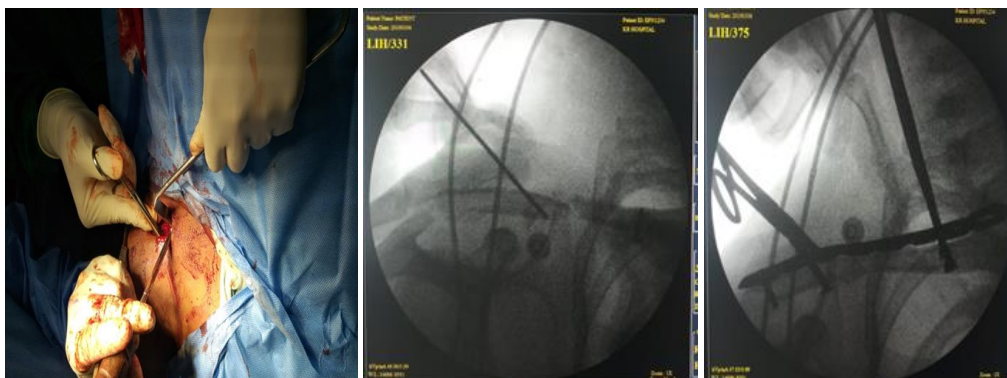


Fig 2: Showing reduced fracture and pre-contoured LCP locked with 2 cortical screws

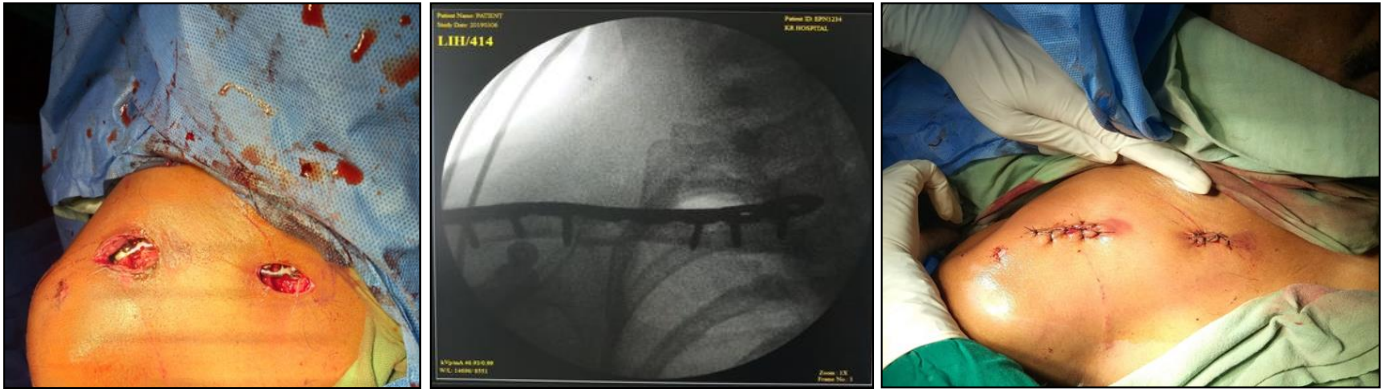


Fig 3: Showing completing fixation

Fig 4: Showing Wound closure

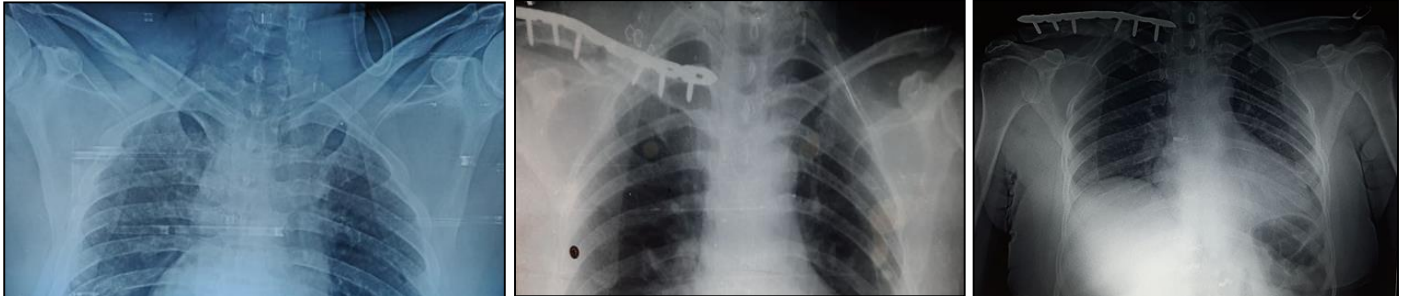


Fig 5: Showing pre op X-ray, Immediate post op X-ray and post op X-ray at 12 weeks of union

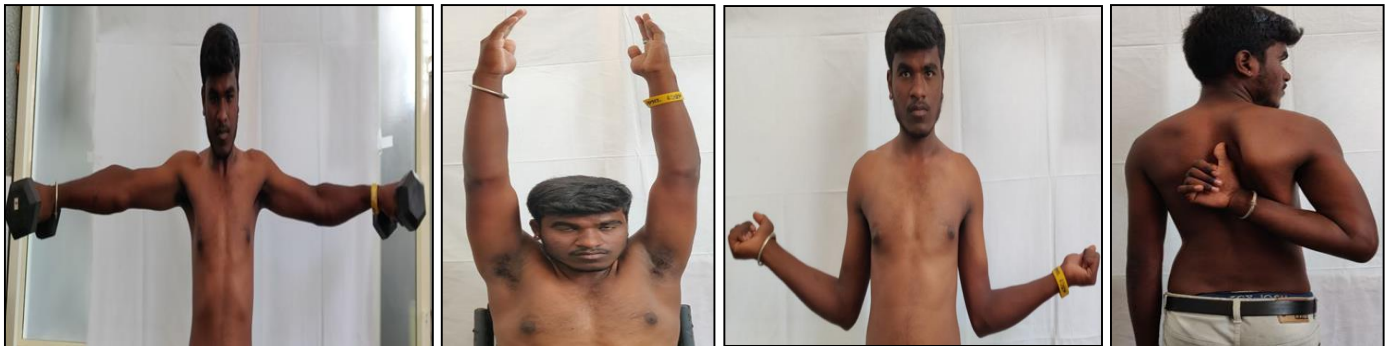

Fig 6: Functional Outcome

Results

Demographic data of studied sample and fracture pattern are shown in (table 1). Average duration of surgery was 35 mins (25 -45 mins). Mean duration of union was 13 weeks (table 2). 23 patients (74%) returned to light work by 6 weeks and pre injury activities by 14 weeks. Mean constant score at follow up is shown in (table 3), functional outcome in (table 4) and complications in (table 5). All fractures were united at final follow up. All patients achieved full range movements of shoulder at 3 months. One of our patient developed superficial infection (image 1) which was subsided with antibiotics. All wounds were healed with minimal surgical scar except in 2 patients which was healed by hypertrophic scar (image 2).

Discussion

The clavicle is an important bone that transfers power from the trunk to the arm. It is S-shaped with a medial convexity and lateral concavity. The middle third is the thinnest, most subcutaneous part of the clavicle that is devoid of muscle and soft tissue attachments. Thus, it is vulnerable to direct and indirect trauma, making it the most common site of fracture in the clavicle accounting for about 80% of all clavicle Fractures. Earlier mid shaft clavicle fractures have been routinely treated

conservatively, but a newer data revealed that no operative management was associated with poor results. A recent study confirmed that plate fixation management had benefits as faster union, early returning to unrestricted activity^[22].

With the availability of locking compression plates there is a trend towards treating these fractures by ORIF. MIPO, using locking compression plate has been well accepted treatment modality in long bone fractures such as humerus, femur, tibia etc. The advantage of the MIPO is the preservation of the soft tissue attachments at fracture site while providing relative stability, there by patients are allowed for early rehabilitation. Reduced surgical invasiveness is linked to a lower rate of wound related complications. There are only few studies where MIPO has been used in treatment of clavicle fractures.

In a study by Hoonsangsohn *et al.* described a surgical Technique for minimally invasive plate osteosynthesis, In this the technique accesses the Fracture via a medial window and the lateral window without opening the Fracture area. A 3.5mm Locking Reconstruction plate is applied to fix the clavicle Fracture and Reduction is achieved with joystick technique using two threaded k-wires^[23]. In our present study we implemented minimally invasive technique combined with reconstruction plate for clavicle midpiece fracture treatment. As

reconstruction plate has a better clinical effect for patients with clavicle fractures and helps in indirect reduction of fragments. In our study two percutaneous K- wires were used in reduction of Fracture displacement.

In a study by Xiu hui wang *et al.* described the minimally invasive with locking Reconstruction Plate is a Good Option for Clavicle mid piece Fracture Treatment with Good fracture Healing [24].

In a study by Tabet. Alsadek *et al.* described a Pre-contoured plate anatomically configured to fit the clavicle was easier to apply and MIPO technique for mid shaft clavicle Fractures is a good option [25].

In a study by Tao Zhang *et al.* Described the self-Designed clavicle reductor can effectively pave the way for application of MIPO technique with Locking Reconstruction Plate is feasible and worthwhile alternative for Mid clavicle Fracture [26].

In our study majority of the patients (24 patients, 77%) fracture union occurred between 10 to 14 weeks remaining patients (23%) fracture union occurred between 14 to 16 weeks. In our study mean time to union was 13 weeks which was compared to other studies in (table-6).

As the skin incisions were made in the direction of langer lines, postoperative scaring was minimal but 2 of our patients developed hypertrophic scar (image 2). In our study we didn't encounter injury to supraclavicular nerves which results in numbness and parasthesia below incision as this complication commonly encountered in ORIF. As in our study we made dissection in submuscular plane close to the bone at fracture site, keeping the skin and platysma intact and passing the plate submuscularly has possibly avoided injury to supraclavicular nerve. In our study no hardware irritation was observed whereas in R.S. Kundangar *et al.* 4 patients had hardware irritation in total 22 patients. In our study implant prominence was seen in 3 patients. Limited dissection and preserving the coverage of soft tissues around the fracture has probably prevented this complications.

In our study we used Constant-Murley scoring System for Functional Assesement of patients because, 'The Constant – Murley Score has a Subjective Patient Based component and an Objective Evaluator Based Component [27]. In our study of 31 patients treated with MIPO using precontoured LCP, 21 patients (68%) had excellent functional outcome, 10 patients (32%) had good functional outcome. None of the patients had poor outcome. The mean constant score was 92.5% with a standard deviation of 6.1. However, in our study the most important clinical advantage is the preservation of soft tissue attachment and the blood supply at the fracture site, enhancing healing and minimizing the risk of infection and other complications.

Table 1: Demographic and fracture related characteristics

Age (years)	32.9 (18-55)
Gender (Male: female)	27:4
Mechanism of injury	
Fall from moto bike	17
Road traffic accident	14
AO/OTA Type	
15-2A2	9
15-2A3	7
15-2B2	15
Associated injuries	
Lower limb fracture	1
Opposite upper limb fracture	1
Abrasion	2

Table 2: Duration of union

Weeks	Frequency	Percent	Cumulative Percent
10	3	9.7	9.7
11	6	19.4	29.0
12	5	16.1	45.2
13	6	19.4	64.5
14	4	12.9	77.4
15	4	12.9	90.3
16	3	9.7	100.0
Total	31	100.0	

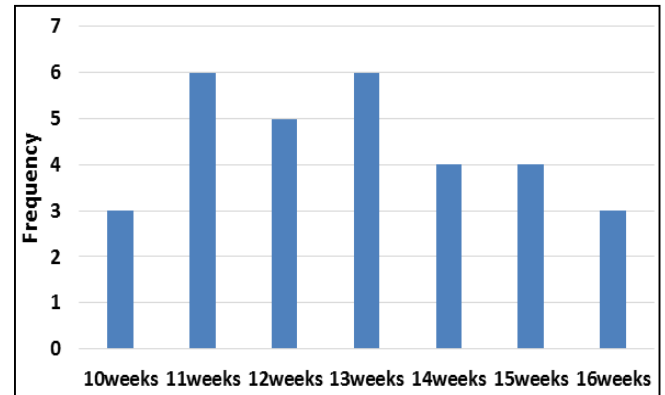


Fig 7: Duration of Union

Table 3: Mean constant score

Constantscore	Frequency	Percent	Cumulative Percent
80	1	3.2	3.2
82	1	3.2	6.5
83	2	6.5	12.9
84	2	6.5	19.4
86	1	3.2	22.6
87	1	3.2	25.8
89	2	6.5	32.3
91	2	6.5	38.7
92	1	3.2	41.9
94	1	3.2	45.2
95	3	9.7	54.8
96	4	12.9	67.7
98	8	25.8	93.5
100	2	6.5	100.0
Total	31	100.0	

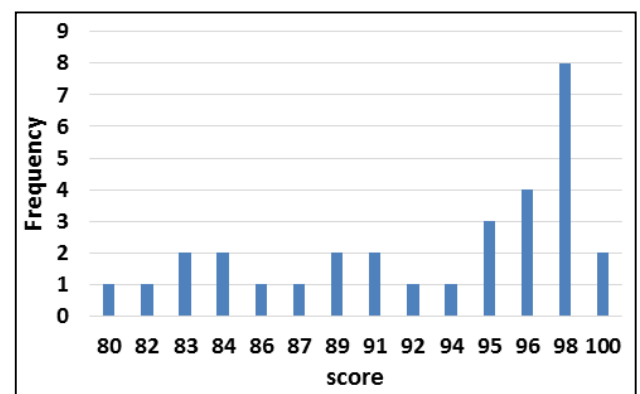


Fig 8: Constant score

Table 4: Functional outcome

	Frequency	Percent	Cumulative Percent
Excellent	21	67.7	67.7
Good	10	32.3	100.0
Total	31	100.0	

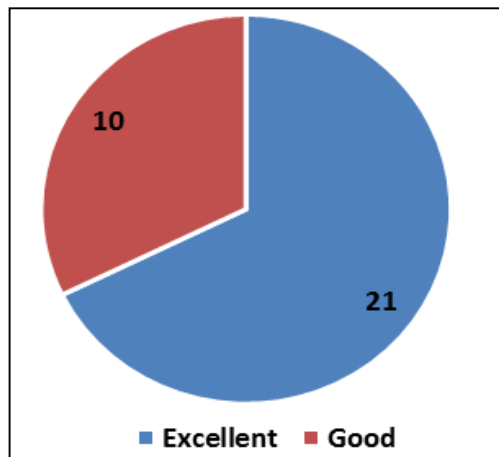


Fig 9: Functional outcome

Table 5: Complications

Complications	Frequency	Percent	Cumulative Percent
Hypertrophic scar	2	6.5	6.5
Implant Prominence	3	9.7	16.1
No Complication	25	80.6	96.8
Superficial infection	1	3.2	100.0
Total	31	100.0	

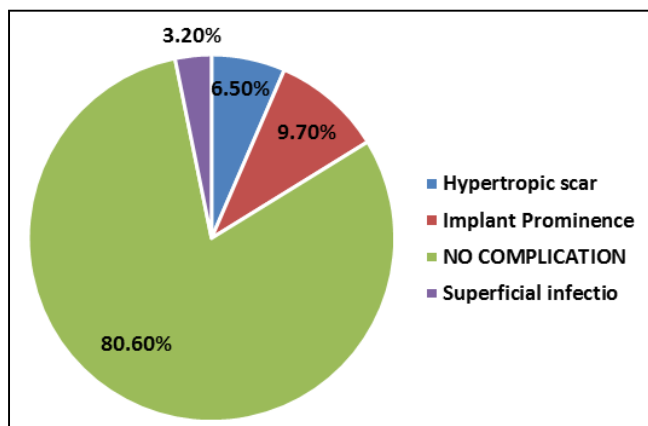


Fig 10: Complications

Table 6: Union Rate Comparison

Name of study	Duration of union(in weeks)
Hoonsangsohn <i>et al.</i>	15.3
Xiuhui Wang <i>et al.</i>	10
Tao Zhang <i>et al.</i>	20
Yuelei Zhang <i>et al.</i>	10
Tabet alsadek <i>et al.</i>	20
R S Kundangar <i>et al.</i>	12.5
Present study	13

Conclusion

Closed biological fixation using MIPPO technique with locking Pre-contoured plate can preserve the blood supply of the fracture site and minimize soft-tissue related complications. The satisfactory outcomes such as high fracture union rates, good functional outcomes and low complication rate of this study suggest that MIPPO technique is effective for midclavicle fractures.

References

1. Johnson EW, Collins HR. Non-union of the clavicle. Arch Surg 1963;87(6):963-6.
2. Paffen PJ, Jansen EW. Surgical treatment of clavicular

fractures with Kirschner wires: a comparative study. Arch Chir Neerl 1978;30(1):43-53.

3. Khan LA, Bradnock TJ, Scott C *et al.* Fractures of the clavicle. J Bone Joint Surg Am 2009;91:447-60.
4. Nordqvist A, Petersson C. The incidence of fractures of the clavicle. Clin Orthop Relat Res 1994;300:127-32.
5. Postacchini F, Gumina S, De Santis P *et al.* Epidemiology of clavicle fractures. J Shoulder Elbow Surg 2002;11:452-6.
6. Postacchini R, Gumina S, Farsetti P *et al.* Long-term results of conservative management of midshaft clavicle fracture. Int Orthop 2010;34:731-736.
7. Andersen K, Jensen PO, Lauritzen J. Treatment of clavicular fractures: figure-of-eight bandage versus a simple sling. Acta Orthop Scand 1987;58:71-74.
8. Hill JM, McGuire MH, Crosby LA. Closed treatment of displaced middle-third fractures of the clavicle gives poor results. J Bone Joint Surg Br 1997;79:537.
9. Canadian Orthopaedic Trauma Society. Nonoperative treatment compared with plate fixation of displaced midshaft clavicular fractures: a multicenter, randomized clinical trial. J Bone Joint Surg Am 2007;89:1-10.
10. Nowak J, Holgersson M, Larsson S. Can we predict longterm sequelae after fractures of the clavicle based on initial findings? A prospective study with nine to ten years of follow-up. J Shoulder Elb Surg 2004;13(5):479-486.
11. Hill JM, McGuire MH, Crosby LA. Closed treatment of displaced middle-third fractures of the clavicle gives poor results. J Bone Joint Surg Br 1997;79(4):537-539.
12. Chu CM, Wang SJ, Lin LC. Fixation of mid-third clavicular fractures with knowles pins: 78 patients followed for 2-7 years. Acta Orthop Scand 2002;73:134-9.
13. Chuang TY, Ho WP, Hsieh PH *et al.* Closed reduction and internal fixation for acute midshaft clavicular fractures using cannulated screws. J Trauma 2006;60:1315-20.
14. Shen WJ, Liu TJ, Shen YS. Plate fixation of fresh displaced midshaft clavicle fractures. Injury 1999;30:497-500.
15. Robinson CM, Court-Brown CM, McQueen MM *et al.* Estimating the risk of non-union following non-operative treatment of a clavicular fracture. J Bone Joint Surg Am 2004;86:1359-65. Operative treatment of clavicle midshaft fractures 671
16. Smekal V, Irenberger A, Struve P *et al.* Elastic stable intramedullary nailing versus non-operative treatment of displaced midshaft clavicular fractures-a randomized, controlled, clinical trial. J Orthop Trauma 2009;23:106-12.
17. Chul CH, Song KS, Min BW *et al.* operative treatment of clavicle midshaft fractures: comparison between reconstruction plate and locking compression plate. Clin Orthop Surg 2010;2:154-9.
18. Zhu Y, Tian Y, Dong T *et al.* Management of the mid-shaft clavicle fractures using plate fixation versus intramedullary fixation: an updated meta-analysis. Int Orthop 2015;39:319-328.
19. Millett PJ, Hurst JM, Horan MP, Hawkins RJ. Complications of clavicle fractures treated with intramedullary fixation. J Shoulder Elb Surg 2011;20(1):86-91
20. Strauss EJ, Egol KA, France MA, Koval KJ, Zuckerman JD. Complications of intramedullary Hagie pin fixation for acute midshaft clavicle fractures. J Shoulder Elb Surg 2007;16(3):280-284.
21. Krettek C, Schandelmaier P, Mclau T, Tscherne H. Minimally invasive percutaneous plate osteosynthesis (MIPPO) using the DCS in proximal and distal femoral

- fractures. *Injury* 1997;28(Suppl 1):A20-A30
22. Vander Have KL, Perdue AM, Caird MS, Farley FA. Operative versus nonoperative treatment of midshaft clavicle fractures in adolescents, *J. Pediatr. Orthop* 2010;30(4):307e312.
 23. Sohn HS, Kim BY, Shin SJ. A surgical technique for minimally invasive plate osteosynthesis of clavicular midshaft fractures. *J Orthop Trauma* 2013;27(4):e92-6. doi: 10.1097/BOT.0b013e31826579c7. PMID: 22773015.
 24. Xiuhui Wang, Zhe Wang, Shengli Xia, Beigang Fu. Minimally invasive in the treatment of clavicle middle part fractures with locking reconstruction plate, *International Journal of Surgery* 2014;12(7):654-658, ISSN 1743-9191, <https://doi.org/10.1016/j.ijso.2014.05.001>.
 25. Al-Sadek TA, Niklev D, Al-Sadek A. Midshaft Clavicular Fractures - Osteosynthesis with Minimally Invasive Technique. *Open Access Maced J Med Sci* 2016;4(4):647-649. doi: 10.3889/oamjms.2016.136. Epub 2016 Nov 22. PMID: 28028406; PMCID: PMC5175514.
 26. Zhang T, Chen W, Sun J *et al.* Minimally invasive plate osteosynthesis technique for displaced midshaft clavicular fracture using the clavicle reductor. *International Orthopaedics (SICOT)* 2017;41:1679-1683. <https://doi.org/10.1007/s00264-016-3392-z>
 27. Constant CR, Murley AH. A clinical method of functional assessment of the shoulder *Clin Orthop Relat Res* 1987;(214):160-164.