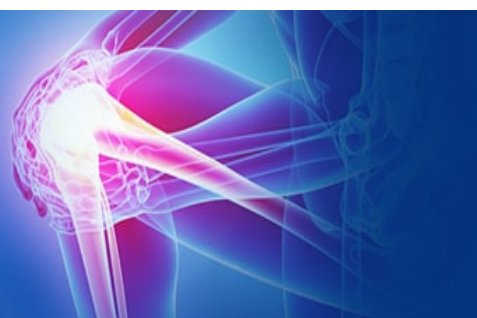



ISSN (P): 2521-3466
ISSN (E): 2521-3474
© Clinical Orthopaedics
www.orthoresearchjournal.com
2021; 5(1): 114-117
Received: 13-11-2020
Accepted: 17-12-2020

Pavith T Janardhan
Senior Resident, Department of
Orthopaedics, Kodagu Institute
of Medical Sciences, Madikeri,
Karnataka, India

Manjunath S Japatti
Orthopaedic Surgeon,
Department of orthopaedics,
Lalith orthopaedic hospital
Sulepeth, Chincholi, Kalburgi,
Karnataka, India

Comparative study of efficiency of PFN vs PFNA-II (Asian) in Intertrochanteric femur fracture with deficient lateral wall- A prospective interventional study

Pavith T Janardhan and Manjunath S Japatti

DOI: <https://doi.org/10.33545/orthor.2021.v5.i1b.305>

Abstract

Background: Proximal femoral nail is the gold standard for many peri trochanteric fracture. Being a load bearing device and intramedullary implant theoretically it is superior than DHS. Lateral wall integrity is the major concern for varus collapse of fixation. Some recent studies reported many PFNA induced lateral wall blow out during insertion. PFNA II came with modifications to prevent these complications during insertion. PFN also has many complications like z effect, screw cut-out, migration and reverse z effect, varus collapse in deficient lateral wall. Hence, we conducted this study to analyse the efficiency of PFN vs PFNA II in lateral wall deficient unstable intertrochanteric fracture.

Methods: It is a prospective interventional study involving 50 patients with intertrochanteric fracture having deficient lateral wall. Study conducted at our institution during 2017-2019. Patients were randomized into two groups of 25 each using computer-based randomization to be treated with PFN or PFNA-II. Post operatively followed at regular intervals and analyzed radiographically and functionally using x ray and Harris hip score respectively.

Results: The average time to union radiologically was 25.2 weeks and 20.18 weeks for PFN and PFNA-II group respectively. The mean HHS accounted for 85.64 in PFN group and 88.45 in PFNA-II group at the end of study. In this study 12 patients had excellent HHS, 8 patients with good HHS, 3 fair HHS and 2 patients with poor HHS in PFN group whereas 14 patients have excellent HHS, 9 patients with good HHS, 1 fair and 1 patient with poor HHS in PFNA-II group. In PFN two patients suffered surgical site infection, two patients progressed to have varus collapse and screw backout. In PFNA II one patient had helical blade cut through. These failed implants patients underwent revision surgery.

Conclusions: single helical blade with ability to create visible compression and impaction at fracture site has a clear advantage over PFN having two screws to be passed through deficient lateral wall. End cap with locking helical blade within the nail prevents its backout and reduces complications related to it. PFNA II is better than PFN in lateral wall deficient intertrochanteric femur fracture.

Keywords: PFN, PFNA II, harris hip score, Z effect

Introduction

The incidence of intertrochanteric femur fractures is increasing with growing elderly population [1]. IT fractures causes considerable morbidity and mortality in older age group. Surgical treatment is now the accepted standard of management to attain acceptable reduction and early mobilization in the elderly osteoporotic individual [2]. Conservative management of intertrochanteric femoral fracture often yields poor therapeutic outcomes, and surgical fixation is generally warranted [3]. DHS was considered gold standard for most of the intertrochanteric femur fractures however it failed to give results in reverse oblique fractures and in unstable IT femur fractures with deficient lateral wall. DHS was an extra medullary implant system [4, 5]. To overcome the failures of this system and to achieve adequate rotational and angular stability various intramedullary systems have been developed. Gamma nail was introduced which showed late complication which ended up having revision surgeries [6, 7] PFN was an intramedullary system which had a compression screw and an antirotation screw which gave excellent results in unstable IT fractures. Although PFN proved to be superior to extra medullary devices for unstable intertrochanteric fractures, screw cut-out, back out, varus

Corresponding Author:
Manjunath S Japatti
Orthopaedic Surgeon,
Department of orthopaedics,
Lalith orthopaedic hospital
Sulepeth, Chincholi, Kalburgi,
Karnataka, India

collapse and rotational instability continued to be significant postoperative complications specially in lateral wall deficient fractures, with up to 31% complication rates being reported in literature [8]. PFNA was developed to reduce implant related complications which consisted of a single helical blade with locking system.

PFNA provides angular and rotational stability, which is especially important in osteoporotic bone, and allows early mobilization and weight bearing on the affected limb [9, 10]. Biomechanical studies have proven that the helical blade, by compaction of cancellous bone around it, has superior resistance to rotation and varus collapse [11].

The following study was conducted to compare the clinical and functional outcomes of PFN and PFNA –II implant system, in patients having IT femur fractures with deficient lateral wall.

Methods

The following study was a prospective study conducted at a tertiary care hospital from 2017 to 2019. Patients were randomized into two groups of 25 each using computer-based randomization to be treated with PFN or PFNA-II. Patients with IT femur fractures with deficient lateral wall were classified into AO types (AO 31 A2 and A3) were included in the study. Patients were investigated with radiography – x ray of pelvis with both hips and full-length AP and lateral views of the affected femur. All patients were operated within a week of admission. Standard operative procedures were followed while implanting PFN and PFNA-II. Post-operative x-rays were taken for all the patients for analyzing implant position and reduction of fracture. All patients were started on mobilization with non-weight bearing 2 days after surgery. Patients were followed up at interval of 3rd month, 6th month and 1 year to look for union, collapse and malunion, implant failure – screw back out, z effect, reverse z effect, blade cut through. Serial radiography and functional outcome were assessed with Harries Hip Scoring on each visit.

Results

50 patients were involved in the study, 25 were treated with PFN and other 25 were treated with PFNA-II. The average age group of PFN implant group was 75.08 years and that of PFNA-II group was 76.85 years. There were 5(20%) females and 20(80%) males included for PFN group and 8(32%) females and 17 (68%) males in PFNA-II group. Fractures were classified using AO classification for IT femur fracture. The PFN group included ten 3.1A2 fractures and fifteen 3.1.A3 fractures. The PFNA-II group consisted of twelve 3.1A2 fractures and thirteen 3.1A3 fractures. The mean HHS accounted for 85.64 in PFN group and 88.45 in PFNA-II group at the end of study. Average time to union radiologically was 25.2 weeks and 20.18 weeks for PFN and PFNA-II group respectively. In this study 12 patients had excellent HHS, 8 patients with good HHS, 3 fair HHS and 2 patients with poor HHS in PFN group whereas 14 patients have excellent HHS, 9 patients with good HHS, 1 fair and 1 patient with poor HHS in PFNA-II group. There were two patients with superficial surgical site infections which was treated with sensitive antibiotics and regular dressing in PFN group. There were two patients with implant related complications that is varus mal alignment and screw back out in PFN group. One patient had helical blade cut through in PFNA-II group. Patients with implant complications underwent revision surgeries.

Tables

Table 1: demographic profile

	PFN (n=25)	PFNA-II(n=25)
Average age (years)	78.85	75.08
Sex		
Male n (%)	5 (20)	8(32)
Female n (%)	20 (80)	17(68)
AO classification		
31.A2(n)	10	12
31.A3(n)	15	13
HHS (final follow up avg)	85.64	88.45
Union time radiologically(weeks)	25.2	20.1
Implant failure (n)	2	1

Table 2: Harries hip score

Harries hip score	Excellent >90	Good >80-89	Fair >70-79	Poor <70
PFN system(n)	12	8	3	2
PFNA-II system(n)	14	9	1	1

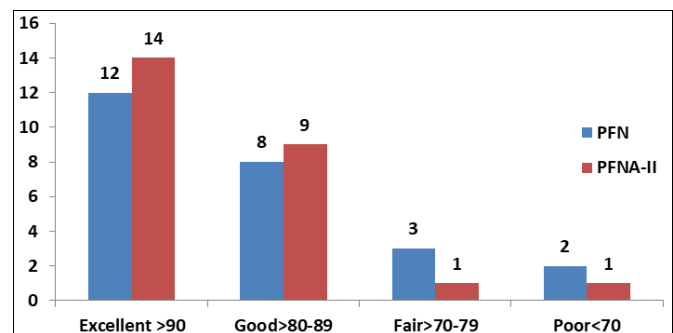


Fig 1: Bar chart depicting harries hip score

Discussion

There has been a significant change in implants used for intertrochanteric femur fractures. PFN used an antirotation screw along with a compression screw to achieve stable fixation. PFNA –II system has replaced these two locking bolts with a single helical blade which gives compression and even rotational stability. Management of unstable intertrochanteric fractures continues to pose a challenge to orthopaedic surgeons, which is further compounded by the effect of deficient lateral wall and osteoporosis on the outcome of these injuries [12]. Biomechanical studies have proven that osteoporosis and lateral wall is an important determinant of screw migration in the proximal femur, thereby predisposing to implant failure [13]. Clinical studies have also shown that osteoporosis is associated with inferior outcomes in intertrochanteric fractures [14]. Therefore, various methods are being used in attempt to improve fixation in osteoporotic intertrochanteric fractures with deficient lateral wall, including cement augmentation and improvements in implant design [15]. In our study we compared the clinical and functional outcome of patients treated using PFN and PFNA- II system. For unstable fractures, intramedullary implants generally present biomechanical advantages over their extra medullary counterparts and literature suggests the same [16, 17]. PFN implant system was introduced with two proximal locking bolts for achieving adequate compression and antirotation. Complications related to implant includes lateral protrusion of screws, cut through of screws, Z or reverse Z effect, and fracture of lateral trochanteric wall. [18] Lateral wall fracture adds to more instability at fracture site along with the posteromedial and

medial wall fracture which may end up in a collapse, implant failure and redo procedure. Lateral wall fracture patients needed revision surgeries as studies done by Palm H *et al.* [19] Compromising the lateral wall leads to a situation in which internal strength of the bone of the head of the femur only will resist the medial deforming forces. All cases of implant failure show varus collapse invariably as the lateral wall fails to provide enough support to the implant [20]. However, studies have shown that PFNA-II showed better results in IT fracture along with lateral wall fractures [21, 22].

There is no exact agreement upon which implant to be used for unstable intertrochanteric femur fractures with lateral wall fractures. In our study we found that PFNA-II had lesser operative time, faster union time, shorter hospital stays and minimal complications when compared to PFN implant group. PFN group had complications which needed revision due to the varus collapse following IT fracture with lateral wall fracture. Functional outcomes were better for PFNA-II group assessed based on the mean HHS. Based on the above findings we found that PFNA-II to be superior in patients with IT fractures with lateral wall fractures. Single helical blade system used in PFNA-II had better hold of the fracture fragments even in osteoporotic bones and achieved better compression and lesser complications such as varus collapse and lateral trochanteric wall collapse.

Figures

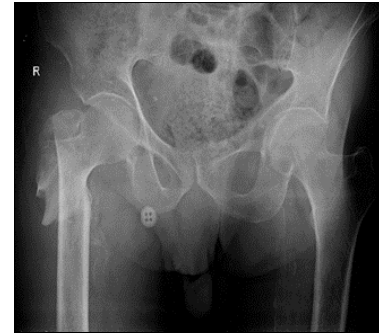


Fig 1: Unstable IT fracture

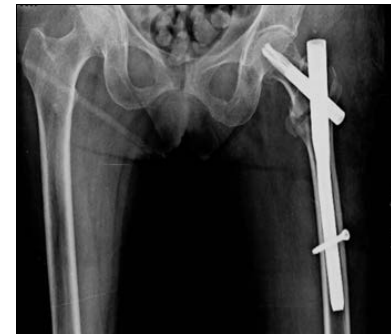

Fig 2: Protruding nail

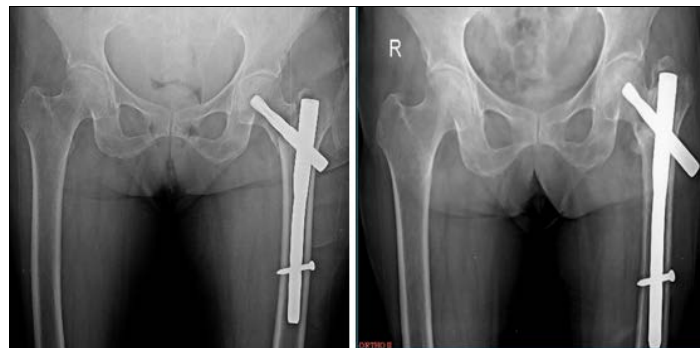

Fig 3 and 4: Screw back out in PFNA II

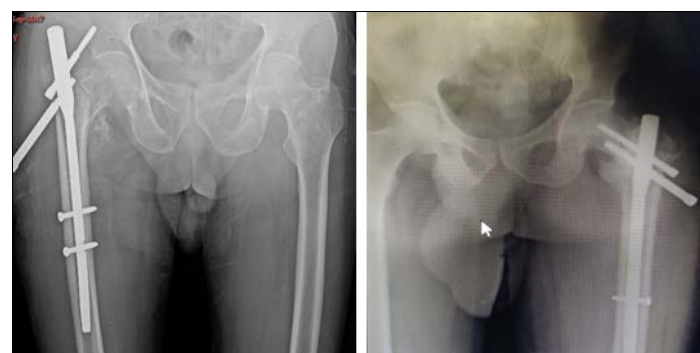

Fig 5 and 6: Z effect

Conclusion

Single helical blade with ability to create visible compression and impaction at fracture site PFNA II has a clear advantage over PFN having two screws to be passed through deficient lateral wall. End cap with locking helical blade within the nail prevents its backout and reduces complications related to it. PFNA II is better than PFN in lateral wall deficient intertrochanteric femur fracture.

Limitations of the study; Small sample size and short follow-

up taken in this study population. Hence long-term implant related complications are not commented upon.

Declarations

Funding: None

Conflict of interest: None

Ethical approval: The study was approved by the institutional ethics committee

Acknowledgement

We are thankful to the faculty of Department of Orthopaedics SDM Medical College Dharwad for helping in this study. No benefits or funds were received in support of this study.

References

- Kanis JA, Johnell O, De Laet C, Jonsson B, Oden A, Ogelsby AK. International variations in hip fracture probabilities: implications for risk assessment. *J Bone Miner Res* 2002;17:1237-44.
- Zhang K, Zhang S, Yang J, [2] Dong W, Wang S, Cheng Y *et al.* Proximal femoral nail vs. dynamic hip screw in treatment of intertrochanteric fractures: a meta-analysis. *Med Sci Monit* 2014;20:1628-33.
- Yin PB, Long AH, Shen J, Tang PF. Treatment of intertrochanteric femoral fracture with proximal femoral medial sustainable intramedullary nails: study protocol for a randomized controlled trial. *Clinical Trials in Orthopedic Disorders* 2016;1(2):44.
- Matre K, Havelin LI, Gjertsen JE *et al.* Sliding hip screw versus IM nail in reverse oblique trochanteric and subtrochanteric fractures. A study of 2716 patients in the Norwegian Hip Fracture Register. *Injury* 2013;44:735-42.
- Knobe M, Gradl G, Ladenburger A *et al.* Unstable intertrochanteric femur fractures: is there a consensus on definition and treatment in Germany *Clin Orthop Relat Res* 2013;471:2831-40.
- Ekström W, Karlsson-Thur C, Larsson S, Ragnarsson B, Alberts KA. Functional outcome in treatment of unstable trochanteric and subtrochanteric fractures with the proximal femoral nail and the Medoff sliding plate. *J Orthop Trauma* 2007;21:18-25.
- Handoll HH, Parker MJ. Conservative versus operative treatment for hip fractures in adults. *Cochrane Database Syst Rev* 2008;16:CD000337.
- Hohendorff B, Meyer P, Menezes D, Meier L, Elke R. [Treatment results and complications after PFN osteosynthesis]. *Unfallchirurg* 2005;108(11):938, 940, 941-46
- Merreddy P, Kamath S, Ramakrishnan M, Malik H, Donnachie N. The AO/ASIF proximal femoral nail antirotation (PFNA): a new design for the treatment of unstable proximal femoral fractures. *Injury* 2009;40:428-32.
- Kristek D, Lovrić I, Kristek J, Biljan M, Kristek G, Sakić K. The proximal femoral nail antirotation (PFNA) in the treatment of proximal femoral fractures. *Coll Antropol* 2010;34:937-40.
- Strauss E, Frank J, Lee J, Kummer FJ, Tejwani N. Helical blade versus sliding hip screw for treatment of unstable intertrochanteric hip fractures. *Biomech Eval Injury* 2006;37:984-89.
- Broderick JM, Bruce-Brand R, Stanley E, Mulhall KJ. Osteoporotic hip fractures: the burden of fixation failure. *Scientific World J* 2013;2013: 515197.
- Cheema G, Rastogi A, Singh V, Goel S. Comparison of cut out resistance of dynamic condylar screw and proximal femoral nail in reverse oblique trochanteric fractures: a biomechanical study. *Indian J Orthop* 2012;46(3):259-65.
- Akan K, Cift H, Ozkan K, Eceviz E, Tasyikan L, Eren A. Effect of osteoporosis on clinical outcomes in intertrochanteric hip fractures treated with a proximal femoral nail. *J Int Med Res* 2011;39(3):857-65.
- Gupta RK, Gupta V, Gupta N. Outcomes of osteoporotic trochanteric fractures treated with cement-augmented dynamic hip screw. *Indian J Orthop* 2012;46(6):640-45.
- Kokoroghiannis C, Aktseles I, Deligeorgis A, Fragkomichalos E, Papadimas D, Pappadas I. Evolving concepts of stability and intramedullary fixation of intertrochanteric fractures - A review. *Injury* 2012;43(6):686-693.
- Tyllianakis M, Panagopoulos A, Papadopoulos A, Pappas S, Mousafiris K. Treatment of extracapsular hip fractures with the proximal femoral nail (PFN): long term results in 45 patients. *Acta Orthop Belg* 2004;70:444-454.
- Rethnam U, Cordell-Smith J, Kumar TM, Simha A. Complex proximal femoral fractures in the elderly managed by reconstruction nailing – complications and outcomes: a retrospective analysis. *J Trauma Manag Outcomes* 2007;1(7):1-7.
- Palm H, Jacobsen S, Sonne-Holm S. Hip fracture study group. Integrity of the lateral femoral wall in inter trochanteric hip fractures: an important predictor of a reoperation. *J Bone Joint Surg Am* 2007;89(3):470-475.
- Gadegone W, Shivashankar B, Lokhande V, Salphale Y. Augmentation of proximal femoral nail in unstable trochanteric fractures. *SICOT-J* 2017;3:12.
- Shi Y, Li F, Tan W, Liu J. [Effectiveness comparison of proximal femoral nail anti-rotation and locking compression plate for intertrochanteric fractures with lateral unsubstantial femoral wall in elderly patients]. *Zhongguo Xiu Fu Chong Jian Wai Ke Za Zhi*. 2014;28(10):1199-203. Chinese. PMID: 25591291.
- Xie H, Wang Z, Zhang J, Xu L, Chen B. Clinical outcome of dynamic hip locking plates and proximal femoral nails anti-rotation-Asia for treating intertrochanteric femur fracture with lateral wall fractures in the elder patients. *Oncotarget* 2017;8(47):82700-82704.