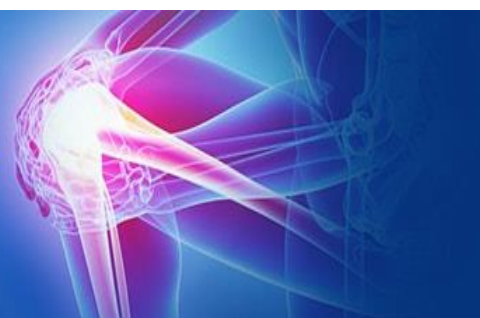



ISSN (P): 2521-3466
 ISSN (E): 2521-3474
 © Clinical Orthopaedics
 www.orthoresearchjournal.com
 2021; 5(1): 97-101
 Received: 25-11-2020
 Accepted: 29-12-2020

Dr. Harish Rajpurohit
 MBBS, DNB (Orthopedics)
 Consultant Orthopaedic
 Lifeline Hospital, Jodhpur,
 Rajasthan, India

Dr. Abhishek Jaroli
 MBBS, DNB (Orthopedics)
 Consultant Orthopaedic
 Mumbai Port trust Hospital
 Wadala, Mumbai, Maharashtra,
 India

Dr. Hiren Bhalala
 MBBS, DNB (Orthopaedics),
 MNAMS, Consultant
 Orthopaedic, SIC Hospital Surat,
 Gujarat, India

Dr. Gajanan Dhaked
 MBBS, DNB (Orthopaedics),
 MNAMS, Consultant
 Orthopaedic, S N Pareek
 memorial hospital and research
 centre, Kota, Rajasthan, India

Hip arthroplasty as a salvage procedure for failed fixation of hip fractures

Dr. Harish Rajpurohit, Dr. Abhishek Jaroli, Dr. Hiren Bhalala and Dr. Gajanan Dhaked

DOI: <https://doi.org/10.33545/orthor.2021.v5.i1b.267>

Abstract

Failed surgical treatment of hip fractures presents a significant challenges in elderly osteoporotic population typically leads to profound functional disability and pain. Revision internal fixation and a salvage treatment with hip arthroplasty are two accepted treatment options. The purpose of this study was to assess the intra operative difficulties encountered and to evaluate the functional outcome of hip arthroplasty performed after failed internal fixation of intertrochanteric (IT) and fracture neck of femur (NOF). 20 patients with failed internal fixation (June 2012 to October 2013) were enrolled and operated during the study period. Functional assessment was done using the Harris Hip Score (HSS) and complications, if any, were documented. There were 11 cases (55%) with failed IT fracture and 9 cases (45%) of failed fixation of NOF fractures. Total hip replacement (THR) was performed in 13 patients (6 cemented and 7 uncemented) and bipolar hemiarthroplasty was done in 7 patients (4 cemented and 3 uncemented). The mean time interval to failure was 3.31 years (SD \pm 3.17). The Harris hip score improved from preoperative 32.95 (SD \pm 7.54) to 77.80 (SD \pm 9.22) at final follow up which was significant ($p < 0.001$). Also the mean difference of improvement in preoperative Harris hip score and any postoperative score or between any two successive post-operative Harris hip scores was significant (P value < 0.001). Complications were seen in 8 of 20 cases (7 I/T group and 1 NOF group). Mean HHS was higher in NOF group than I/T fracture group preoperatively as well as at final follow up (P value 0.003 preoperative and 0.013 postoperative). Our conclusion is that hip arthroplasty is an effective salvage procedure after failed fixation of proximal hip fractures despite the technical challenges and complications associated with it.

Keywords: Intertrochanteric fracture, arthroplasty, harris hip score.

Introduction

Treatment of peritrochanteric fractures has undergone evolution with time. Most intertrochanteric hip fractures can be treated successfully with internal fixation^[1, 2]. Primary arthroplasty is less commonly used in this fracture setting given the often complicating issue of trochanteric involvement and more distal extension of the fracture. However, in cases of pre-existing arthritis or severe osteoporosis, arthroplasty can be used successfully as the initial treatment. In the elderly patient, the use of arthroplasty has been shown to reduce the need for subsequent reoperation and improve patient satisfaction^[3]. There have been several recent studies demonstrating even greater success with the use of primary total hip replacement in functional patients with a displaced femoral neck injury^[3, 4, 5, 6, 7, 8].

In both types the fracture pattern, bone quality, accuracy of reduction, suboptimal fixation are key factors determining outcome. An intertrochanteric fracture is subjected to significant biomechanical loads, which can lead to loss of reduction and/or fixation failure. Between 25%-45% of femoral neck fractures have been shown to fail surgical fixation. Intertrochanteric fractures with unstable fracture patterns are associated with failure rates as high as 56%^[9, 10, 11, 12]. Failure can be secondary to nonunion, loss of fixation, femoral head osteonecrosis, posttraumatic arthritis, malunion, infection, or symptomatic hardware.

Failed surgical treatment of hip fractures typically leads to profound functional disability and pain^[13]. The two main treatment options for such patients are revision internal fixation and a salvage treatment with hip arthroplasty^[14]. Most surgeons prefer salvage with internal fixation for physiologically younger patients with a long life expectancy and even for some active older

Corresponding Author:

Dr. Abhishek Jaroli
 MBBS, DNB (Orthopedics)
 Consultant Orthopaedic
 Mumbai Port trust Hospital
 Wadala, Mumbai, Maharashtra,
 India

patients with a well-preserved femoral head, good acetabular cartilage, adequate bone quality, and a favourable fracture pattern [15, 12]. There are a number of technical issues related to conversion of failed hip fractures into hip arthroplasty, including difficult exposure, fibrosis of soft tissues around hip, excess blood loss, removal of previous implant, distorted anatomy of proximal femur, presence of screw holes, reduced bone strength etc. Also malunion or non-union of trochanteric region interfere with insertion and proper implant placement. Poor bone quality, absence of calcar support and distorted anatomy of femoral canal are problems associated with cementless conversion arthroplasty. A cementless implant exposes to a risk of peri-operative fractures because the holes act as stress risers. Cemented operations are encountered with per-operative problems like presence of screw holes in shaft and trochanteric region [16, 17]. The conversion operations are at least theoretically associated with higher orthopaedic and non-orthopaedic complications [17, 18, 19]. The rate of dislocation after conversion of failed internal fixation of femoral neck fracture to total hip arthroplasty is reported to be as high as 20% [20, 21, 22]. However salvage hip arthroplasty dramatically alleviated pain, improved function, allows most patients to regain function that otherwise had been lost, which is the hallmark of an effective salvage procedure. The purpose of this study is to assess the intra operative difficulties encountered and to evaluate the functional outcome of hip arthroplasty performed after failed internal fixation of intertrochanteric and neck fractures of the proximal femur.

Methods

Data was collected from patients admitted in the Department of Orthopaedics, Sir Ganga Ram Hospital, New Delhi with failure of previously fixed intertrochanteric or femur neck fractures and treated with hip arthroplasty from June 2012 to October 2013.

All patients meeting the eligibility criteria during the study period (June 2012 to October 2013) were enrolled. 20 patients were admitted and operated during this study period.

All patients were treated surgically with bipolar hemiarthroplasty or total hip replacement and patients were followed up postoperatively at 2 weeks, 6 weeks, final follow up (minimum of 6 months; the maximum follow up in our study was 20 months) and data recorded at each visit.

Inclusion criteria

1. Patients older than 20 years and either sex.
2. Patients with failure of internal fixation of intertrochanteric fractures or neck femur fracture.

Exclusion criteria

1. Compound fractures.
2. Patients <20 years of age.
3. Patients with associated ipsilateral or contra lateral fracture of upper or lower extremities or acetabular fracture.
4. Failed fixation of subtrochanteric fractures.
5. Patient with neurological disorder affecting lower limbs.
6. Patients treated with failure of primary arthroplasty for proximal femur fractures.

Patients were admitted in the hospital one day prior to the date of planned surgery. Detailed history and physical examination was done, limb length discrepancy, deformity or limitation of movements of hip were noted. Preoperative Harris hip score was determined for each patients and records maintained. Radiographs of pelvis with both hips and true antero-posterior

and lateral view of involved hip were taken.

Preoperative medical fitness was taken in all cases. Pre-anesthetic examination was carried out a day prior to the surgery. A written consent for the surgery was taken for all patients. All surgeries were performed using standard aseptic precautions by the same surgical and anaesthetic team by using the same pre-op and post-op protocol. Surgery was performed under spinal or general anesthesia. All possible inventories for implant removal were kept available including high speed burs and hollow mill. Universal extractor was used for removing proximal femoral nails.

Straight lateral position with the patient lying on the unaffected side down was used. Hip joint was exposed using standard Moore's posterior approach. Previous scars were not taken into account in planning new incisions. The gemelli, obturator internus and the piriformis tendons were divided at their insertions after tagging them for easier identification and reattached later. Capsule cut with T shaped incision and joint exposed. Femoral head was dislocated before implant removal in all cases with failed intertrochanteric fractures with DHS in situ, except in patients who had screw cut out where implant removal was done before hip dislocation. In cases with proximal femoral nail and corticocancellous screws fixation, implant removal was done prior to dislocation of femoral head. After the hip was dislocated posteriorly, osteotomy of the neck was done at a level 1 cm proximal to the base of neck. The complete head and part of neck was removed en mass keeping the posterior capsular flap for closure and size measured using template. Acetabular labrum was never excised except in cases where total hip arthroplasty was being performed.

The femoral shaft was rasped using a broach and prepared for the insertion of the prosthesis. Cemented or uncemented THA was done as decided by the operating surgeon according to the age of the patient and according to condition of bones as seen in preoperative radiographs and also per-operatively. Femoral stem was fixed in place in 10-15° of anteversion using standard cementing techniques – lavage, cleaning, drying and plugging of the canal in case of cemented hip arthroplasty. Limb length was only adjusted by soft tissue tension as the local anatomy was distorted.

Piriformis and posterior capsule was closed with drill holes through the greater trochanter, the wound was closed in layers over a suction drain, which is removed at the first change of dressing after 48 hours. Blood loss was calculated by keeping account of amount of blood collected in suction container and absorbed in sponges. Further the amount of blood collected in the drain post-operatively is documented and is not included in the intraoperative blood loss.

Patients were followed up at an interval of 6 weeks, 3 months, 6 months and final follow up maximum 20 months. Clinico-radiological and functional assessments were carried out. All patients were functionally assessed using the Harris Hip Score and complications, if any, were documented. Radiological assessment was done with serial radiographs to look for signs of stem and cement position, loosening, protrusion and dislocation.

Statistical method

Statistical testing was conducted with the statistical package for the social science system version SPSS 17.0. Continuous variables are presented as mean \pm SD, and categorical variables are presented as absolute numbers and percentage. The comparison of normally distributed continuous variables between two groups was performed using Student's t test and ANOVA was used for more than two groups. Repeated

measurements (HHS scores) were analyzed by repeated measures ANOVA with further paired comparisons at each time interval performed using the t-test. Nominal categorical data between the groups were compared using Chi-squared test or Fisher's exact test as appropriate. $P < 0.05$ was considered statistically significant.

Results

There were 10 women and 10 men with an average age of years 59.9 years ($SD \pm 16.28$). 18 patients were above 40 years of age. 12 cases had left side and in 8 cases right hip was involved. There were 11 cases (55%) with failed intertrochanteric fracture and 9 cases (45%) of failed fixation of neck of femur fractures. DHS was used for primary fixation in 9 cases, in 8 cases Cortico cancellous screw fixation was done previously. In 3 of 20 cases proximal femoral nail was used, of which 1 patient had failure with both PFN and DHS.

In 6 cases the cause of failure (Fig 1) was cut out of DHS screw, 4 cases failed due to AVN of head, 4 cases had non-union of previous fracture and 3 cases had malunion. 2 cases had secondary arthritis of hip and 1 case with intertrochanteric fracture had failure due to deep infection with DHS implant in situ. This case was treated with 2-stage revision surgery.

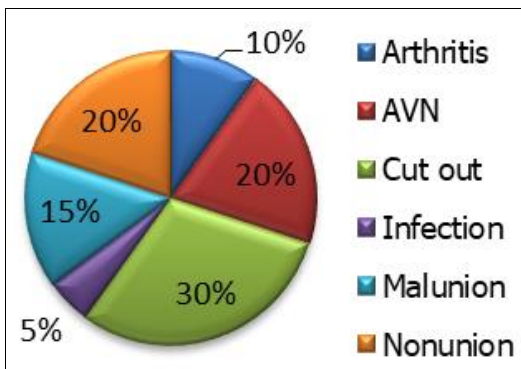


Fig 1: Cause of failure

Time interval between primary fixation surgery for fracture of hip and hip arthroplasty performed for failure of fixation is noted in all cases and mean time interval to failure was 3.31 years ($SD \pm 3.17$). The average limb shortening on the affected side was 1.66 cms ($SD \pm 0.77$), with a range of 0.5 to 3 cms. No shortening was seen in 4 cases.

Total hip replacement was performed in 13 patients of which cemented prosthesis was used in 6 cases and non-cemented in 7 cases. 7 patients were treated with Bipolar hemiarthroplasty (4 cemented and 3 none cemented) (Figure 2). The mean intraoperative blood loss in our study was 595 ml ($SD \pm 347.13$). 11 of 20 cases required intraoperative or postoperative blood transfusion and 9 cases did not need blood transfusion. The mean duration of operation was 2.05 hrs ($SD \pm 0.74$). The minimum duration of operation was 1 hour in and maximum operation time taken was 3.5 hours. The mean duration of stay in hospital was 8.8 days ($SD \pm 4.34$) with minimum duration of 2 days and maximum duration of 21 days.

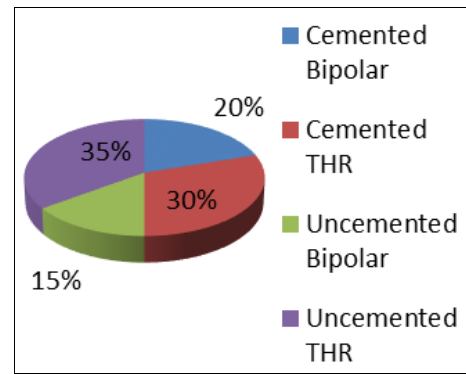


Fig 2: Surgery performed

No complications were seen in 12 patients. Intraoperative or early postoperative complications were found in 8 patients. Out of the 8 cases, 3 had early dislocation of hip out of which 2 were of failed I/T group and 1 case of failed NOF group, superficial infection was seen in 2 cases. Periprosthetic fracture occurred in 1 case with failed I/T fracture during preparation of canal and it was treated with circlage wiring. Intraoperative or early postoperative complications were seen in 8 of 20 cases in our study. 7 of them were from I/T group and 1 from failed fracture neck of femur. This difference in incidence of complications is significant (P value 0.028).

The mean preoperative Harris hip score (Table 1) was 32.95 ($SD \pm 7.54$) which increased to 77.80 ($SD \pm 9.22$) at final follow up. The clinical improvement was found to be significant with P value < 0.001 . Also the mean difference of improvement in preoperative Harris hip score and any postoperative score or between any two successive post-operative Harris hip scores was significant (P value < 0.001).

Table 1: Harris hip score

	Mean \pm SD	Min - Max	P value
Pre-op HHS	32.95 \pm 7.54	21 - 45	< 0.001
HHS 2 weeks	49.55 \pm 8.70	38 - 66	
HHS 6 weeks	63.90 \pm 8.52	52 - 74	
HHS Final Follow up	77.80 \pm 9.22	58 - 90	

Mean Harris hip score was higher in NOF group than I/T fracture group preoperatively and at final follow up. The difference was statistically significant (P value 0.003 preoperative and 0.013 postoperative). There is no significant difference in duration of failure after primary fixation in intertrochanteric and fracture neck of femur groups.

In our study excellent functional outcome (HHS > 90) was seen in 1 case and good results (HHS 80-89) in 12 patients. Poor results (HHS < 70) were seen in 4 cases and fair (HHS 70-79) in 3 patients. In 4 cases with poor outcome, 3 had some postoperative complication like dislocation, intraoperative femoral shaft fracture and DVT.

Discussion

Hip fracture for which treatment has failed presents a difficult challenge to the orthopaedic surgeon. In younger patients, salvage typically involves efforts to preserve the hip joint with repeat internal fixation; elderly patients with disuse osteopenia treatment options allowing early ambulation are limited [23]. Failed treatment of a hip fracture typically leads to severe functional disability and pain, especially in elderly patients. Prior studies have demonstrated higher complication rates with these salvage procedures when compared with primary THA for

arthritis [24]. Revision cases are challenging and require overcoming numerous obstacles including femoral and acetabular bone defects, osteopenic bone, removal of broken hardware and previous fixation devices, surgical dissection through heterotopic bone and scar tissue, and bone loss from previous fractures [18, 22].

DeHaan *et al.* [25] reviewed 46 patients who underwent salvage hip arthroplasty (SHA) for revision of failed cannulated screws (CS), sliding hip screws (SHS), or intramedullary nails (IMN) to determine differences in operative difficulty. The mean time to failure of the index implant requiring salvage hip arthroplasty was 42 months (range 3 weeks–20 years). The mean operative time was 136 min (range 65–280), estimated blood loss was 717 ml (range 200–2500), and hospital length of stay was 5.0 days (range 3–12). Mean follow-up time was 8.1 months. Their results showed that SHA after failed femoral neck fixation was associated with lower intraoperative demands than after failed peri-trochanteric fractures.

Shrivastav *et al.* [26] studied 21 hips in 20 patients (13 females and seven males) with mean age of the 62 years (range 38 years to 85 years). Nine patients were treated for femoral neck fracture, 10 for intertrochanteric (I/T) fracture and two for sub trochanteric (S/T) fracture of the hip. Uncemented THA was done in 11 cases, cemented THA in eight hip joints and hybrid THA in two patients. The average duration of follow-up was four years (2-13 years). The mean duration of surgery was 125 min and blood loss was 1300 ml.

In our study 20 patients with mean age 59.9 years were treated with hip arthroplasty for failed treatment of hip fracture. Out of 20 patients, there were 11 cases of failed intertrochanteric fractures, and 9 had failed fracture neck of femur. Screw cut out was (30%) found to be most common cause of failure followed by non-union (20%) and AVN of head of femur (20%). 1 case had infected implant, 3 patients had malunion and secondary arthritis of hip was cause of failure in 2 cases in our study. Average intra-operative blood loss was 595 ml. Out of 20 patients 11 required blood transfusion. Mean Operative time was 123 minutes with minimum of 1hour and maximum of 3.5 hours. The average time to failure was 3.31 years. Blood loss, operative time and duration of stay of patients with I/T group was higher than NOF group. In our series 13 patients were operated with conversion to total hip replacement, of which 6 underwent cemented and 7 cementless total hip replacement. In 7 patients bipolar hip arthroplasty was performed, 4 of them underwent cemented femoral fixation and 3 uncemented femoral fixations.

D'Arrigo *et al.* [18] reported on 21 patients who underwent THA for failed treatment of intertrochanteric fractures found improved functional outcomes in their series with good and excellent results in 70% of patients. The mean Harris hip score was 31 preoperatively and 81 postoperatively. Hammad *et al.* [26] reviewed 32 patients and found that clinical results were good or excellent in 78% of patients at last follow-up.

In our series preoperatively, all patients had either moderate or severe pain and were unable to walk except 9 patients who had a limited walking ability with use of either two arm supports or crutches in seven patients and walker in another two patients. Postoperatively all the patients had significant pain relief. The mean preoperative Harris hip score was 32.95 that increased to 77.80 at final follow up, with minimum score of 58 and maximum of 90. We had good and excellent results in 65% of patients.

Higher rate of complications were found with salvage hip arthroplasty in some studies. Mehlhoff *et al.* [16] in their study on

thirteen patients reported complications in the form of dislocation in three and revision because of instability in two patients. D'Arrigo *et al.* [18] in their study on 21 patients reported 2 postoperative complications. In the study of Archibeck *et al.* [24] there were 12 patients who had early surgical complications related to the procedure (11.8%, 12/102). These included 5 patients who had dislocations (4.9%), 4 periprosthetic fractures (4%), 2 hematomas, and 1 infection. Of the 5 patients with dislocations, 3 were in prior femoral neck fractures with screw fixation, 1 was in a prior dynamic hip screw construct, and 1 was in a prior trochanteric nail. All 4 periprosthetic femur fractures were in prior intertrochanteric fractures (3 dynamic hip screws, 1 trochanteric nail). Srivastav *et al.* [27] in their study reported 3 dislocations (14.3%), 3 intraoperative fractures (14.3%), 1 superficial and 1 deep infection in their study. DeHaan²⁵ *et al.* reported 12 total complications (26%) and 6 failures (13%) requiring revision surgery after salvage total hip arthroplasty.

In our study among all cases 8 patients (40%) had intra or postoperative complications. One patient with intertrochanteric fracture had failure with PFN initially and was managed with DHS that failed due to cut out of screw had intraoperative fracture of shaft of femur during canal preparation. This case was managed with encirclage wiring of the shaft and cemented bipolar hemiarthroplasty. Three patients had complications in form of dislocation(15%), out of which 2 were of failed I/T group and one with failed CC screw fixation. 2 dislocations that were detected on 1st postoperative day were managed with closed reduction in the operation theatre, while one patient required open reduction of the hip. Higher incidence of complications was seen in failed I/T group compared to NOF group.

The strength of this study includes the number of patients treated with hip replacement for failure of fixation of hip fractures, and the fact that the operations were in recent years, thus allowing us to assess the results of this operation in an era in which hip arthroplasty methods and implants have evolved sufficiently to treat these challenging problems effectively. Secondly, evaluated patients were treated by a single surgeon at a single centre, means that there was consistency in surgical technique and implant use in the study.

The weakness of this study includes the diversity of implant fixation method in the primary treatment of the fracture and the diversity of the prosthetic implant used for revision. A variety of treatment options were used to manage these patients ranging from modular bipolar (cemented and cementless) to total hip replacement (cemented and cementless), which makes comparison of results in these heterogenous group of patients difficult. The number of patients were small with limited follow up and had failed intertrochanteric or neck fracture fracture treatment due to a variety of implants.

Conclusion

Hip arthroplasty attenuated pain and improved function in majority of patients. It requires meticulous preoperative planning. Salvage arthroplasty procedures performed for failed internal fixation are associated with increased technical demands and risk of complications compared with routine primary hip arthroplasty. Use of tailored implants and careful consideration of fixation method become paramount. Surgeons must understand the increased risk of perioperative morbidities and individually counsel patients according to both health status and functional demand when deciding for salvage arthroplasty. Hip arthroplasty is an effective salvage procedure after failed

fixation of proximal hip fractures despite the technical challenges and complications associated with it. Further study of long-term outcomes is necessary to delineate the survival incidence and technical aspect of reoperations performed for failed internal fixation.

References

- Kyle RF, Gustilo RB, Premer RF. Analysis of six hundred and twenty two inter trochanteric hip fractures. *J Bone and Joint Surg Am* 1979;61:216-221.
- Kyle RF, Cabanela ME, Russel TA, Swiontkowski MF, Winkquist RA, Zuckerman JD *et al.* Fractures of the proximal part of femur. *J Bone and Joint Surg Am* 1995;44:227-253.
- Schmidt AH, Leighton R, Parvizi J, Sems A, Berry DJ. Optimal arthroplasty for femoral neck fractures: Is total hip arthroplasty the answer? *J Orthop Trauma* 2009;23:428-433.
- Leonardsson O, Rogmark C, Karrholm J, Akesson K, Garellick G. Outcome after primary and secondary replacement for subcapital fracture of the hip in 10,264 patients. *J Bone Joint Surg Br* 2009;91:595-600.
- McKinley JC, Robinson CM. Treatment of displaced intracapsular hip fractures with total hip arthroplasty: Comparison of primary arthroplasty with early salvage arthroplasty after failed internal fixation. *J Bone Joint Surg Am* 2002;84(A):2010-2015.
- Hopley C, Stengel D, Ekkernkamp A, Wich M. Primary total hip arthroplasty versus hemiarthroplasty for displaced intracapsular hip fractures in older patients: Systematic review. *BMJ* 2010;340:c2332.
- Gjertsen JE, Lie SA, Fevang JM, Havelin LI, Engesaeter LB, Vinje T *et al.* Total hip replacement after femoral neck fractures in elderly patients: Results of 8,577 fractures reported to the Norwegian Arthroplasty Register. *Acta Orthop* 2007;78(4):491-497.
- Baker RP, Squires B, Gargan MF, Bannister GC. Total hip arthroplasty and hemiarthroplasty in mobile, independent patients with a displaced intracapsular fracture of the femoral neck. A randomized, controlled trial. *J Bone Joint Surg Am* 2006;88:2583-2589.
- Benterud JG, Husby T, Nordsletten L, Alho A. Fixation of displaced femoral neck fractures with a sliding screw plate and a cancellous screw or two Olmed screws: a prospective, randomized study of 225 elderly patients with a 3-year follow-up. *Ann Chir Gynaecol* 1997;86:338-342.
- Bhandari M, Devereaux PJ, Swiontkowski MF, Tornetta P, Obremskey W, Koval KJ *et al.* Internal fixation compared with arthroplasty for displaced fractures of the femoral neck. A meta-analysis. *J Bone Joint Surg Am* 2003;85A:1673-1681.
- Leonardsson O, Sernbo I, Carlsson A, Akesson K, Rogmark C. Long-term follow-up of replacement compared with internal fixation for displaced femoral neck fractures: Results at ten years in a randomised study of 450 patients. *J Bone Joint Surg Br* 2010;92(3):406-412.
- Haidukewych GJ, Israel TA, Berry DJ. Reverse obliquity fractures of the intertrochanteric region of the femur. *J Bone Joint Surg Am* 2001;83:643-650.
- Jeffrey O, Anglen JN. Nail or plate fixation of intertrochanteric hip fracture: Changing pattern of practice. A review of the American Board of Orthopaedic Surgery database. *J Bone Joint Surg Am* 2008;90:700-707.
- Stea S, Bordini B, De Clerico M, Petropulacos K, Toni A. First hip arthroplasty register in Italy: 55000 cases and 7 years follow-up. *Int Orthop* 2009;33:339-346.
- Dimon J, Hughston J. Unstable intertrochanteric fractures of the hip. *J Bone Joint Surg Am* 1967;49(A):440-450.
- Mehlhoff T, Landon GC, Tullos HS. Total hip arthroplasty following failed internal fixation of hip fractures. *Clin Orthop relat res* 1991;269:32-37.
- Zhang B, Chiu KY, Wang M. Hip arthroplasty for failed internal fixation of intertrochanteric fractures. *J Arthroplasty* 2004;19:329-333.
- D'Arrigo C, Perugia D, Carcangiu A, Monaco E, Speranza A, Ferretti A. Hip arthroplasty for failed treatment of proximal femoral fractures. *Int Orthop* 2010;34:939-942.
- Ramiah RD, Baker RP, Bannister GC. Conversion of failed proximal femoral internal fixation to total hip arthroplasty in osteopetrotic bone. *J Arthroplasty* 2006;21:1200-1202.
- Sah AP, Estok II DM. Dislocation rate after conversion from hip hemiarthroplasty to total hip arthroplasty. *J Bone Joint Surg Am* 2008;90:506-516.
- Mabry TM, Prpa B, Haidukewych GJ, Harmsen WS, Berry DJ. Long-term results of total hip arthroplasty for femoral neck fracture nonunion. *J Bone Joint Surg Am* 2004;86:2263-2267.
- Tabsh I, Waddell JP, Morton J. Total hip arthroplasty for complications of proximal femoral fractures. *J Orthop Trauma* 1997;11:166-169.
- Haidukewych GJ, Berry DJ. Hip arthroplasty for salvage of failed treatment of intertrochanteric hip fractures. *J Bone Joint Surg Am* 2003;85(A):899-904.
- Archibeck MJ, Carothers JT, Tripuraneni KR, White RE Jr. Total hip arthroplasty after failed internal fixation of proximal femoral fractures. *J Arthroplasty* 2013;28(1):168-171.
- DeHaan AM, Groat T, Priddy M, Ellis TJ, Duwelius PJ, Friess DM *et al.* Salvage hip arthroplasty after failed fixation of proximal femur fractures. *J Arthroplasty* 2013;28:855-859.
- Hammad A, Abdel-Aal A, Said HG, Bakr H. Total hip arthroplasty following failure of dynamic hip screw fixation of fractures of the proximal femur. *Acta Orthop Belg* 2008;74:788-792.
- Srivastav S, Mittal V, Agarwal S. Total hip arthroplasty following failed fixation of proximal hip fractures. *Indian J Orthop* 2008;42:279-286.