



ISSN (P): 2521-3466
ISSN (E): 2521-3474
© Clinical Orthopaedics
www.orthoresearchjournal.com
2021; 5(1): 69-76
Received: 15-11-2020
Accepted: 05-12-2020

Dr. Prakhar Agarwal
Assistant Professor, Department
of Orthopaedics, Teerthankar
Mahaveer Medical College and
Research Centre, NH 24, Delhi
Road, Bagadpur, Moradabad,
Uttar Pradesh, India

**Dr. Arunmozhimaran Vijaya
Babu**
Professor and HOD, Department
of Orthopaedics, Aarupadai
Veedu Medical College and
Hospital, Cuddalore Main Road,
Kirumampakkam, Puducherry,
India

Evaluation of functional results in the management of supracondylar fracture of humerus in children by different methods

Dr. Prakhar Agarwal and Dr. Arunmozhimaran Vijaya Babu

DOI: <https://doi.org/10.33545/orthor.2021.v5.i1b.260>

Abstract

Introduction: Supracondylar fractures of humerus in children are not only the commonest fractures but also one of the most difficult fractures to treat.

Materials and Methods: 30 Patients with Supracondylar Fracture of Humerus admitted and got treated at Department of Orthopaedics, Aarupadai Veedu Medical and Hospital, Puducherry during the period from 2013 to 2015 were studied after informed consent was obtained from the patients.

Results: In this series of 30 patients the youngest patient was 3 years old and the oldest was 14 years old. Most of the patients were between 5-8 years of old age (43.33%). Males (63.33%) were more affected than Females and left side was more involved (73.33%) than right side. According to Gartland's Classification Type III fracture were more i.e. 63.33%. Type I fractures were treated by above elbow slab in 90°-120° flexion, out of total 3 cases 2 showed excellent results and one showed good result. Type II fractures, out of 8 patients 3 were treated with closed reduction and casting, 2 showed excellent 1 showed good result. Rest 5 patients were treated with closed reduction and k-wire fixation, all showed excellent result. Type III fractures, out of 19 patients 12 patients were treated by closed reduction and K-wire fixation, 10 showed excellent results, 2 showed good results and rest 7 were treated open reduction and K-wire fixation, 2 of them showed excellent, 2 showed good results, 2 showed fair results and 1 poor result.

Conclusion: Type I Supracondylar Fractures are treated with immobilization in POP slab for 3 weeks. Type II Supracondylar Fracture treated by closed reduction and Immobilization when the reduction is stable and there is no gross angulations at the fracture site. In Type II when the reduction is unstable or when the fracture shows greater collapse of weakened medial column is being treated by closed reduction and stabilization with K-wire fixation. In Type II and III fractures when closed reduction is not satisfactory and in open fractures, open reduction and stabilization with K-wires, 1 from medial and 1 from lateral end of lower end of humerus in mandatory. In our present study the above protocol of treatment of Supracondylar Fracture has given good cosmetic and functionally satisfied results.

Keywords: Supracondylar fractures, children, management

Introduction

Supracondylar Fracture of Humerus is one of the commonest fractures sustained by children. Supracondylar Fracture of Humerus is the commonest fracture around the elbow in children accounting for 50% to 70% of fractures in this region.

Supracondylar fractures of humerus in children are not only the commonest fractures but also one of the most difficult fractures to treat because of rather frequently occurring complications like Nerve injury, Vascular injury, Volkman's Ischaemic Contracture, Stiffness of Elbow and Malunion.

In the beginning of 20th century, Sir Robert Jones echoed the opinion of that era about Elbow injuries. The difficulties experienced by surgeons in making an accurate diagnosis, the facility with which serious blunders can be made in prognosis and treatment, and fear shared by so many of the subsequent limitation of functions, serve to render injuries in the neighborhood of the Elbow less attractive than they might otherwise have proved. These concerns are applicable even today.

Many treatment modalities are available in the management of Supracondylar Fractures of Humerus like:

Corresponding Author:
Dr. Prakhar Agarwal
Assistant Professor, Department
of Orthopaedics, Teerthankar
Mahaveer Medical College and
Research Centre, NH 24, Delhi
Road, Bagadpur, Moradabad,
Uttar Pradesh, India

- Closed reduction and Immobilization in Above Elbow Cast/Slab.
- Overhead Olecranon Wing Nut Traction.
- Closed Reduction and Percutaneous Pinning under Image Intensifier Control.
- Open reduction and Pinning (Lateral pin, Cross pinning constructs)
- Lateral External Fixator.
- Straight Arm Skeletal Traction.
- Type II - Displaced with intact posterior cortex/anterior cortex
- Type III - Displaced with no bone contact
- Type III is further classified into two types (Wilkins modification) depending upon the displacement type
 - a) Posteromedial
 - b) Posterolateral

Supracondylar Fracture of Humerus is known for complications because of the inherent fracture instability, close vicinity of Brachial artery and three major nerves of upper extremity and poor radiographs and poor interpretation of reduction and modality of maintenance of reduction and lastly patient compliance to treatment.

Materials and Methods

30 patients with Supracondylar Fracture of Humerus admitted and got treated at Department of Orthopaedics, Aarupadai Veedu Medical and Hospital, Puducherry during the period from AUGUST 2013 to SEPTEMBER 2015 were studied after informed consent was obtained from the patients and after Ethical Clearance was obtained from the Ethical Clearance Committee of Aarupadai Veedu Medical College and Hospital, Puducherry.

Inclusion criteria

1. Age of patients 1 to 16 years.
2. All types of Supracondylar Fracture of Humerus.

Exclusion criteria

1. Age of patients less than 1 and above 16 years.
2. Patients with Intercondylar Component.
3. Patients not seeking treatment modality according to our protocol.
4. Patients presenting with infection at fracture site.

Evaluation of patients were done in terms of

- Side of limb injured
- Time since injury
- Closed or open fracture
- Puckering of skin at elbow
- Amount of swelling at elbow
- Presence or absence of radial pulse
- Nail bed circulation and signs of compartment syndrome
- Associated nerve injuries – radial, median and ulnar
- Associated musculoskeletal injuries

Radiologically evaluation consisted of - Anteroposterior and Lateral films initially and after manipulation with or without pinning, Jones view is evaluated. In Anteroposterior films – Baumann's angle was measured in lateral films – Anterior humeral line, Crescent sign and Fish tail sign were noted. In Jones view assessment of the coronal alignment of distal fragment was done.

For classification we used Gartland's classification with Wilkins modification.

Extension types and flexion types

Depending upon the sagittal tilt of distal fragment.

Both types are further classified into-

- Type I – Undisplaced

Our management protocol was

For Type I (Undisplaced) - simple above elbow slab in flexion of about 90 degrees to 120 degrees depending upon the angle at which radial pulse is intact. No anaesthesia required. Follow up done after 1 week to look for any displacement. If there is no displacement pop slab continued for another 2 weeks. After which x-ray are taken to evaluate the signs of fracture healing. If enough callus present slab is removed and active exercises are initiated if not, pop slab given for another week and then slab removed and active exercises are started. For type II (displaced but posterior cortex intact) – closed reduction under anaesthesia with or without Percutaneous k-wire fixation depending upon the stability and peripheral pulse. After reduction elbow is stabilized in above elbow pop slab or casting. For Type III (completely displaced) – closed or open reduction and fixation with k-wire. After fixation elbow is supported with above elbow pop slab or cuff and collar.

Indications for Open Reduction and k-wire fixation were-

1. 2 to 3 attempts of failed Closed Reduction maneuver
2. An Open fracture or
3. A Fracture associated with vascular damage.

Method of closed reduction

Radiographs were studied properly and manipulation maneuver planned accordingly. Under general anaesthesia after preparation and draping, reduction maneuvers done. An assistant applies counter traction by grasping the upper arm and manipulates the distal fragment. Surgeon holds the wrist and applies traction with elbow in extension. Proximal pull of triceps and biceps should be overcome by longitudinal traction. Elbow may be slightly hyperextended to disengage the fragments with caution not to over stretch the vital anterior structures. With one hand the distal fragment is manipulated and first lateral displacement is corrected then with continuing traction the elbow is flexed to lock the fracture fragment in position. The amount of flexion possible is limited by the amount of swelling present and is dictated by the position where possible is limited by the amount of swelling present and is directed by the position where the radial artery is palpable. The elbow can be flexed just to the point where radial pulse disappears then it should be extended 5 degrees to 10 degrees to accommodate additional swelling. The position of forearm is decided by the type of displacement of distal fragment that is either posteromedial (pronation) or posterolateral (supination).

- Adequacy of reduction is evaluated.
- Clinically – full elbow flexion should be possible.
- Assessment of carrying angle just before flexion.
- The axis of forearm would be parallel to the axis of arm.

Radiologically

Lateral view of elbow was assessed for shaft condylar angle and anterior humerus line crossing capitellum.

Jones view of elbow was taken to assess coronal alignment of distal fragment measurement of baumann's angle deviation of more than 5 degrees in comparison opposite side mean inadequate reduction.

Anatomy of medial and lateral pillars was analysed for comminution anatomic reorientation of olecranon fossa was considered as index of pillar orientation and reduction.

After satisfactory reduction stability of fracture was assessed by flexion and extension of elbow and if fracture was not stable pinning was selected otherwise casting was done.

Pinning technique

Cross pinning

In supine position after preparation and draping, fracture was reduced and adequacy of the reduction checked under c-arm control. First lateral pin was introduced through lateral epicondyle directing at an angle of 40 degrees superiorly and 10 degrees posteriorly. Decrease the amount of flexion to pose the ulnar nerve posteriorly and pass the medial pin through medial epicondyle more horizontally than dose the lateral pin. Both pins should catch the opposite cortex and cross proximal to fracture site and at least one pin should pass through olecranon fossa. Cut the pins off either outside or beneath the skin and bend their ends so that pins won't migrate, but can be easily retrieved in outpatient department. Radial pulse was checked, stability at fracture site was checked and posterior splint was given.

Lateral pinning

Fracture was reduced and arm was held with elbow hyper flexed and forearm pronated or supinated according to the type of displacement to maintain the reduction. The goal was to have two pins divergent on AP and lateral films.

In choosing a site for the first pin, we generally place it through the center of the ossified capitellum, cross the olecranon fossa, giving it greater stability, and then further penetrate the medial cortex. A second pin is placed through the distal humeral epiphysis lateral to the capitellum but clearly within the epiphysis. The pin proceeds up the lateral column and engages the opposite cortex. If the first pin is placed centrally in the lateral column, the second pin will nearly always cross the first just above the fracture, which will be a less satisfactory lateral pinning. Maximal pin separation increases the stability with this technique. Gentle stress can be used to test the stability of two lateral pins. If the arm can be grasped by the proximal humerus and stressed mildly without displacing the fracture, the fixation is satisfactory. If displacement occurs, it is generally rotational with loss of reduction of the medial column. We simply reduce the fracture to an anatomic position and place either a medial pin as described in the technique for crossed pinning or a third lateral pin.

Open reduction technique

Anaesthesia

General anaesthesia was given in all open reduction cases.

Operative technique

The patient was placed on the operation table in lateral position. No tourniquet was used. Intravenous antibiotics ceftriaxone was administered before the start of the procedure. The arm, elbow

& forearm was scrubbed with betadine scrub and was painted with betadine and spirit and then draped. The limb was hanged on the side of table with the arm board.

Posterior – lateral approach (CAMPBELL)

Make the skin incision 10cm proximal to the elbow on the posterolateral aspect of the arm, and continue it distally for 13cm.

Deepen the dissection through the fascia, and expose the aponeurosis of the triceps as for distally as its insertion on the olecranon.

When the triceps muscle has been contracted by fixed extension of the elbow, free the aponeurosis proximally to distally in a tongue – shaped flap, and retract it distally to its insertion incise the remaining muscle fibers to the bone in the midline if the triceps muscle has not been contracted, divide the muscle and aponeurosis longitudinally in the midline, and continue the dissection through the periosteum of the humerus, through the joint capsule, and along the lateral border of the olecranon elevate the periosteum together with the triceps muscle from the posterior surface of the distal humerus for 5 cm.

For wider exposure, continue the subperiosteal stripping on each side releasing the muscular and capsular attachments to the condyles and exposing the anterior surface, taking care not to injure the ulnar nerve. Strip the periosteum from the bone as conservatively as possible.

Fracture reduced, under direct vision and k-wire passed on either side i.e. both medial and lateral pinning (crossed pinning), & checked under image intensifier. K-wires bent and cut outside the skin, close the wound in layers, apply sterile dressing and give well-padded above elbow POP slab in 90 degree of flexion and mid prone position.

Antibiotics (intravenous) was continued over the next post-operative day and was then switched over to oral antibiotics (cefuroxime) for the next 5 days.

Good callus should be observed at the fracture before pin removal, generally 3 to 4 weeks after injury.

Results were graded according to the Flynn's criteria as excellent, good, fair and poor results.

Excellent

- Loss of movement 0-50 (functional)
- Loss of carrying angle 0.50 (cosmetic)

Good

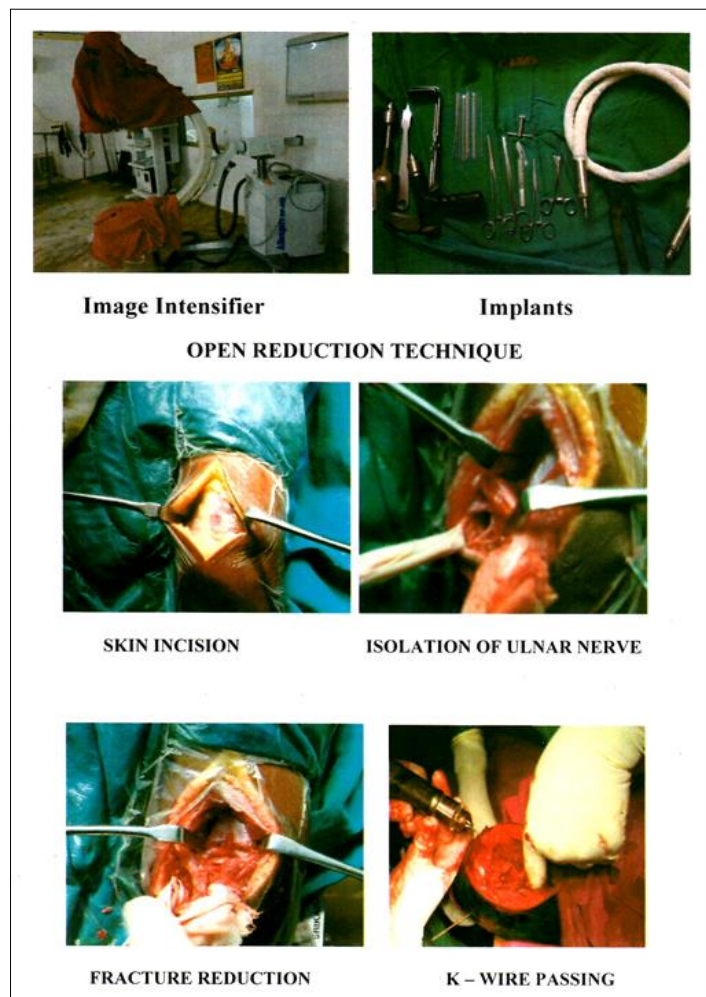
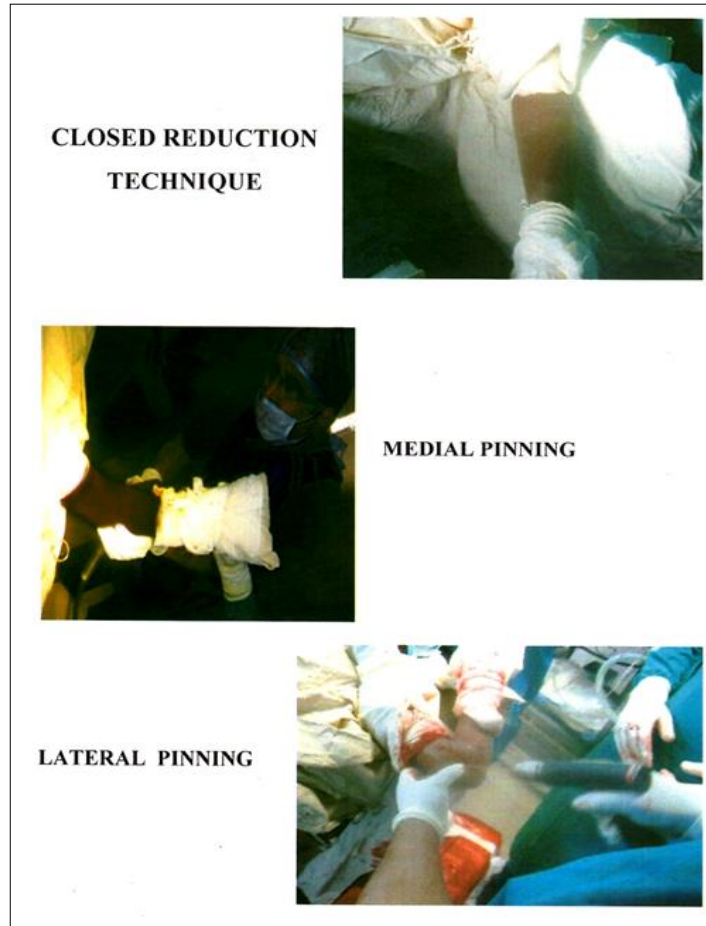
- Loss of movement 5-100 (functional)
- Loss of carrying angle 5-100 (cosmetic)

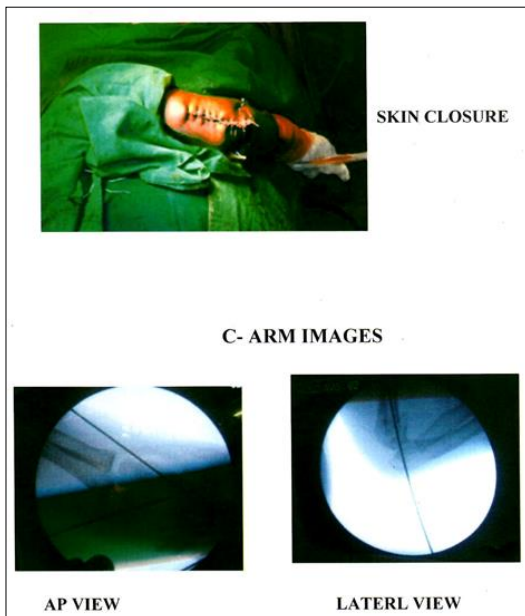
Fair

- Loss of movement 10-150 (functional)
- Loss of carrying angle 10-150 (cosmetic)

Poor

- Loss of movement 150 (functional)
- Loss of carrying angle 150 (cosmetic)





Incidence of supracondylar fracture of humerus was more in males (70%) when compared to females (30%) in our study.

Table 3: Side of injured limb

Sex	No. of patients	Percentage
Right	8	26.66%
Left	22	73.33%

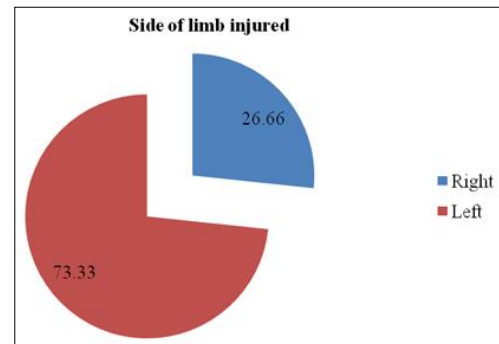


Fig 3: Side of injured limb

Observation and Results

Table 1: Age wise distribution

Age in years	No. of patients	Percentage
0 – 4	3	10%
5 - 8	13	43.33%
9 – 12	11	36.67%
13 – 16	3	10%

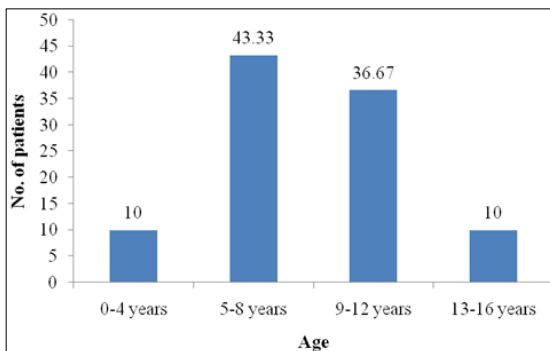


Fig 1: Age wise distribution

In present series of 30 patients, most of the patients are in the age group of 5-8 years (43.33%) in our study.

Table 2: Sex wise distribution

Sex	No. of patients	Percentage
Female	11	36.66
Male	19	63.33

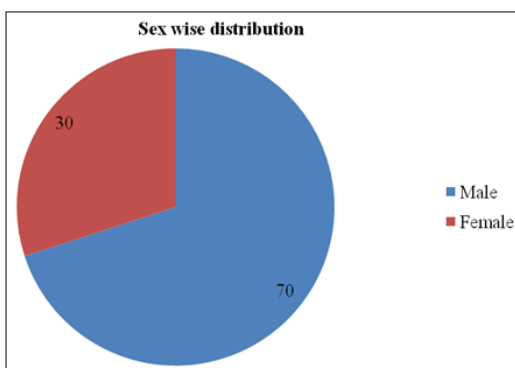


Fig 2: Sex wise distribution

In our study involvement of left side (73.33%) is more than right side.

Table 4: Type of fracture (Gartland's classification)

Type of fracture	No. of patients	Percentage
Type I	3	10%
Type II	8	26.66%
Type III	19	63.33%

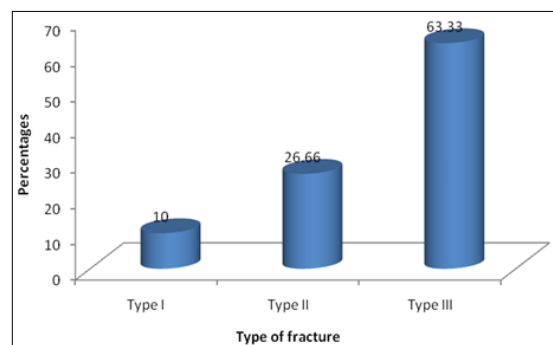


Fig 4: Type of fracture

Table 5: Treatment modality employed

Treatment modality	No. of patients	Percentage
Closed reduction and casting	6	26.66%
Closed reduction and percutaneous pinning	17	56.6%
Open reduction and pinning	7	23.33%

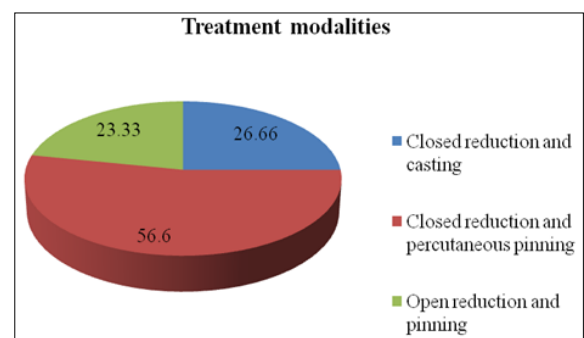


Fig 5: Treatment modality employed

Total type I cases, 3 all treated by closed reduction and casting. Total type II cases are 8. Out of eight 5 were treated with closed reduction and percutaneous pinning rest 3 were treated closed reduction and casting. Total type III cases are 19 in these 12 were treated with closed reduction and percutaneous pinning rest 7 were treated open reduction and pinning.

Table 6: Pin constructs

Type of construct	No. of patients	Percentage
2 lateral pin construct	2	8.33%
1 lateral and 1 medial pin	19	79.16%
2 lateral and 1 medial	3	12.5%

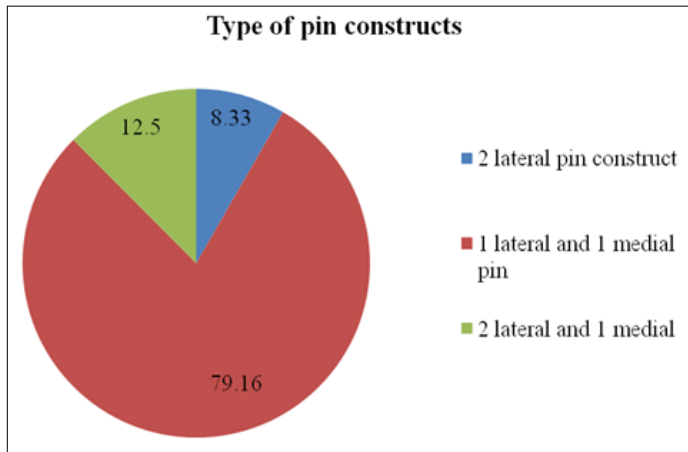


Fig 6: Pin constructs

We had 24 Supracondylar Fracture of Left Humerus out of 30 patients. Our preferred construct was cross pinning. We did 1 lateral and 1 medial pinning in 19 cases, and 2 lateral pins in 2 cases and 2 lateral pins and 1 medial pin construct in 3 cases.

Table 7: Post-operative complications

Complications	No. of patients	Percentage
Cubitus varus deformity	1	3.33%
Pin tract infection	1	3.33%
Nerve injury	0	0
Proximal migration of pins	0	0
Restriction of movement	2	6.66%

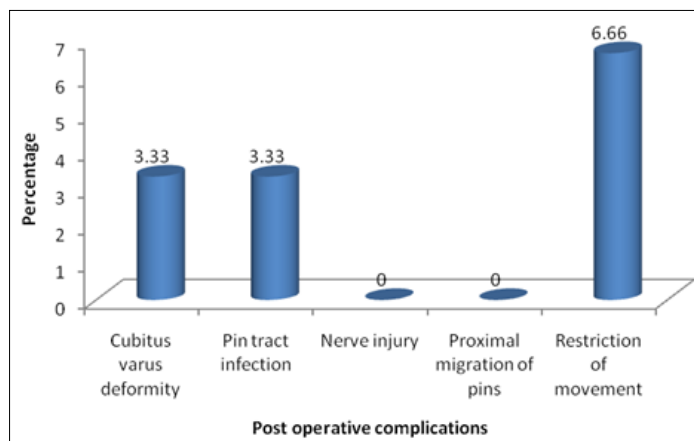


Fig 7: Post-operative complications

Post operatively out of 24 patients in whom fracture was fixed with K-wire one patient had pin infection. Out of 30 patients treated ONE patient had developed cubitus varus deformity and 2 patients had restriction of movements.

Table 8: Change in carrying angle

Change in carrying angle	No. of patients	Percentage
0-5	21	70%
6-10	6	20%
11-15	2	6.66%
Above 15	1	3.33%
Total	30	100%

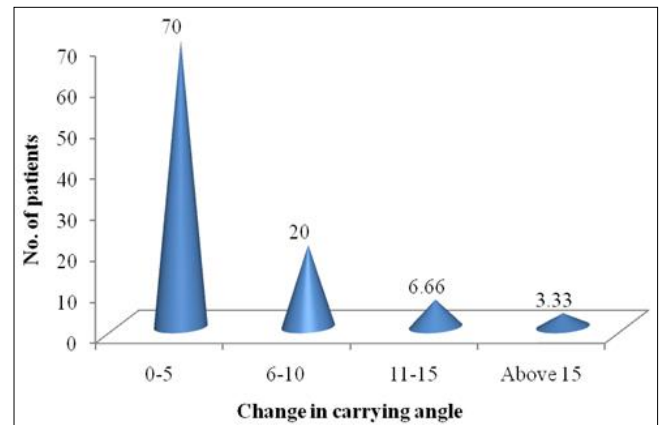


Fig 8: Change in carrying angle

90% cases, change in carrying angle was less than 10 degrees.

Table 9: Final results

Result	According to loss of range of motion		According to loss of carrying angle		Average percentage
	No. of patients	%	No. of Patients	Percentage	
Excellent	21	70%	21	70%	70%
Good	6	20%	6	20%	20%
Fair	2	6.66%	2	6.66%	6.66%
Poor	1	3.33%	1	3.33%	3.33%

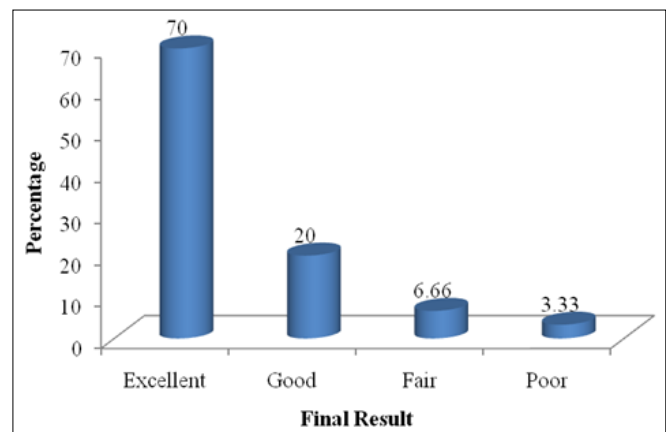


Fig 8: Final results

According to FLYNN'S criteria results of our study are analyzed. In our study, out of 30 patients 90% were good excellent and 10% showed fair and poor result.

Table 10: Flynn's criteria

Result	Functional factor (Loss of motion in degree)	Cosmetic factor loss of carrying angle in degrees
Excellent	0-5 ⁰	0-5 ⁰
Good	06-10 ⁰	06-10 ⁰
Fair	11-15 ⁰	11-15 ⁰
Poor	>15 ⁰	>15 ⁰

70% of patient had excellent results and 20% cases had good result. The total satisfactory results were 90%, 6.66% of cases had fair results and 3.33% cases had poor results. The total unsatisfactory results were 10%.

Poor and fair results were because of initially they had prior treatment before admission in the form of massage and secondarily due to difficulty in reduction and fixation of the fragments in unsatisfactory position.

Results

In our study 36.66% were Females (11 cases) and 63.33% were Males (19 cases).

In our study, 10% were in the age group of 0-4 years, 43.33% were in the age group of 5-8 years, 36.67% were in the age group of 9-12 years, 10% were in the age group of 13-16 years.

73.33% had involved on the left side and 26.66% on the right side.

Complication encountered in this study

In our study two cases had restriction of elbow movement after open reduction and internal fixation, with physiotherapy satisfactory range of motion was obtained, ONE case had mild degree of cubitus varus noticed, because of unsatisfactory reduction and fixation of the fragment in poor position.

27 patients retained satisfactory range of motion just by loss of 0-10°, 3 patients had unsatisfactory range motion by loss of more than 10°

10% of cases had loss carrying angle more than 10°, 10% of cases had loss of range of motion more than 10°

27 cases (90%) had excellent and good results (satisfactory).

3 cases (10%) had fair and poor results.

Cause of unsatisfactory results because of

1. Delayed reporting
2. Prior manipulation else where
3. History of massage
4. Unsatisfactory reduction and fixation
5. Delayed physiotherapy
6. Bad follow up

Excellent and good results were due to

1. Early reporting time
2. No prior treatment
3. No massage and manipulation
4. Anatomical reduction and fixation
5. Immediate physiotherapy after pin removal
6. Good follow up

Discussion

30 patients of Supracondylar Fracture of Humerus were treated in, Department of Orthopaedics, AARUPADAI VEEDU MEDICAL COLLEGE & HOSPITAL, PUDUCHERRY during a period from AUGUST 2013 to SEPTEMBER 2015.

The aim of the study was known the short term outcome of patients with Supracondylar Fracture of Humerus treated with different modalities.

Age distribution

Musa *et al.* [38] conducted prospective study based on 30 cases with Type III Gartland's Fracture managed by crossed Percutaneous pinning over a period of two years. Age group range was 2 to 13 years with a mean age of 7.06 years.

Charles A Rockwood observed that the peak incidence of Supracondylar Fracture of Humerus in children is in the later

part of first decade of life.

In the present study, the average age is 7 years (range 2 — 15 years) and the most common age group affected was between 5 – 8 years (43.33%).

Sex distribution

Pirone AM *et al.* in their study of 230 patients with Supracondylar Fracture of Humerus showed that boys (119) were affected more than girls (111).

Robert D ambrosia in his series found an incidence of Supracondylar Fracture of Humerus in male child is 63% and female child is 37%.

In our study, the incidence of Supracondylar Fracture of Humerus is 36.66 % in Females and 63.33% in Males.

Side involvement

Robert D ambrosia found involvement of left elbow was 64% and involvement of right side was 36% among his cases of Supracondylar Fracture of Humerus in children.

Ahmed *et al.* in their study of Supracondylar Fracture of Humerus in children showed the predominance of left side involvement. In the present study left side was involved in 73.33% and right side 26.66% cases. Incidence of side involvement in the present study is consistent with the above series.

Fracture type incidence (Gartland's classification with Wilkins modification)

Pirone AH *et al.* (1988) studied 230 cases of displaced Supracondylar Fracture of Humerus and observed that 137 (62%) cases were Type III Fractures and 83 (36%) were Type II. In Type III Fractures 94 were with posteromedial displacement, 22 with posterolateral displacement and 21 with direct posterior displacement

Mehlman *et al.* during their study of operative treatment of Supracondylar Fracture of Humerus in children found that according to Gartland's classification, 77.4% were Type III fractures and 18.3% were Type II fractures on comparison, in the present study of 30 patients, 3(10) were Type I, 8(26.66%) were Type II and 19(63.33%) were Type III Fractures.

Complications

Pin tract infection

Pirone A H *et al.* (1988) studied 230 cases of displaced Supracondylar Fractures of Humerus and observed that out of 78 treated with closed reduction and Percutaneous pinning 52 cases had pin tract infection. Cramer K E in his retrospective review of 29 children with Supracondylar Fracture of Humerus in children treated with closed reduction and Percutaneous pinning and Open reduction and Percutaneous pinning, 1 patient in closed reduction and Percutaneous pinning out of 15 cases showed superficial pin tract infection.

Lejman T *et al.* showed no case of pin tract infection in 20 cases of Supracondylar Fracture of Humerus cases treated with closed reduction and percutaneous pinning

In our study 1 patient showed evidence of pin tract infection in 7 cases treated with open reduction and pinning. Infection was treated with antibiotics and regular dressing.

Cubitus varus

Topping *et al.* showed incidence of cubitus varus in one patient (4.3%) out of 43 cases treated with closed reduction and percutaneous pinning.

Kennedy observed 2 cases with cubitus varus deformity among

32 cases of Displaced Supracondylar Fracture of Humerus in children.

In the present study, one patient (3.3%) developed cubitus varus deformity this deformity is seen in closed reduction and percutaneous pinning patient.

Proximal migration of wire

Pirone A M *et al.* observed migration of one lateral pin out of 96 cases treated with closed reduction and percutaneous pinning.

In our study, no case we saw this complication because in all pinning cases we bent k-wires outside the skin.

Conclusion

- The outcome of results of Supracondylar Humerus Fracture in children depends on perfect anatomical reduction and possible early treatment.
- Distal neurovascular assessment is mandatory.
- In Type I: Undisplaced Supracondylar Fractures are treated with immobilization in plaster slab for 3 weeks.
- Type II: Supracondylar Fracture treated by closed reduction and Immobilization when the reduction is stable and there are no gross angulations at the fracture site.
- In Type II when the reduction is unstable or when the fracture shows greater collapse of weakened medial column is being treated by closed reduction and stabilization with percutaneous K –wire fixation.
- In Type II and III fractures when closed reduction is not satisfactory and in open fractures, open reduction and stabilization with K- wires, 1 from medial and 1 from lateral end of lower end of humerus in mandatory.
- In our present study the above protocol of treatment of Supracondylar Fracture has given good cosmetic and functionally satisfied results.

References

1. David DA, Bruce Ip. Supracondylar Fractures of Humerus – a modified technique of closed pinning. CORR 1987;219:174-184.
2. Prirone AM, Graham HR, Krajbich JI. Management of displaced extension – type Supracondylar Fractures of the Humerus in children. JBJS 1988;70-A(50):641-650.
3. Hamid RM, Charles S. Crossed pin fixation of displaced Supracondylar Fracture of Humerus in children. CORR 2000;376:56-61.
4. James RK, James HB. Rock wood Green's fracture in children. 5th ed. Lippincott Williams & Wilkins 2001.
5. John AH. Tachdjian's pediatric orthopedic. 3rd ed, saunders 2002.
6. Jeffery LN, Malcom LE, Stanley MK, Paul AL, Marianne D. Supracondylar Fracture of Humerus in children treated by closed reduction and percutaneous pinning. CORR 1983;177:203–209.
7. Teddy slongo *et al.* lateral external external fixation – a new technique for displaced unreducible Supracondylar Fracture of Humerus in children JBJS, Am, Aug 2008;90:1690-1697.
8. Gadgil A *et al.* straight – arm traction for Supracondylar Fracture of Humerus fractures of the humerus in children urnal of Bone & Joint surgery: British 2005;87–B(1):82-87.
9. Attenborough CG. Remodeling of humerus after supracondylar fracture in childhood. JBJS 35(B):386-395.
10. Madsen E. Supracondylar Fracture of Humerus in children JBJS 38(B):241.
11. French PR. Varus deformity of the elbow following Supracondylar Fracture of the Humerus in children. Lancet 2 1959; 439.
12. Staples OS. Dislocation of brachial artery a complicate of Supracondylar Fracture of Humerus in children. JBJS 1965: 47 –A: 1525.
13. EI sharkawi H, Fattah HA. Treatment of displaced Supracondylar fracture of Humerus in children in full extension and supination. JBJS 1965; 47 – B: 273.
14. D' Ambrosia Rd. Supracondylar Fracture of Humerus prevention of cubitus varus. JBJS 1972; 54-A: 60-66.
15. Fowles JV, Kassab MT. Displaced Supracondylar Fracture of the elbow in children. JBJS 1974;56-B: 490-500.
16. Flyn JC, Mathew JC, Beoit RL. Blind pinning of Supracondylar Fracture of Humerus in children. JBJS 1974; 56-A: 263 -71.
17. Arnold JA, Nasca RJ, Nelson CL. The role of dynamic factors in the prevention of deformity. JBJS 1997; 59-A: 589-95.