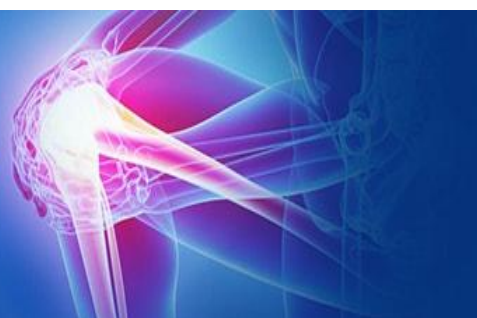



ISSN (P): 2521-3466
ISSN (E): 2521-3474
© Clinical Orthopaedics
www.orthoresearchjournal.com
2017; 1(3): 46-51
Received: 10-08-2017
Accepted: 11-09-2017

Dr. Vikrant Kulkarni
Senior Resident, Department of
Orthopedics, ESIC Medical College,
Kalaburagi, Karnataka, India

Dr. Ullas Mahesh
Assistant Professor,
Rajarajeshwari Medical College
and Hospital, Bangalore,
Karnataka, India

Dr. Mithun S Jumani
Senior Resident, MBBS,
D Ortho, DNB Orthopaedics,
ANIIMS Port Blair Andaman and
Nicobar Islands

Dr. Kirthi Shivalingaiah
Assistant Professor,
Rajarajeshwari Medical College
and Hospital, Bangalore,
Karnataka, India

Dr. Hareesha YS
Senior Resident, Department of
Orthopaedics, Rajarajeshwari
Medical College and Hospital,
Bangalore, Karnataka, India

Correspondence
Dr. Ullas Mahesh
Assistant Professor,
Rajarajeshwari Medical College
and Hospital, Bangalore,
Karnataka, India

To study the outcome of intercondylar fractures of distal humerus using dual plating and its functional outcome

Dr. Vikrant Kulkarni, Dr. Ullas Mahesh, Dr. Mithun S Jumani, Dr. Kirthi Shivalingaiah and Dr. Hareesha YS

Abstract

Introduction: Distal humeral fractures account for approximately 2%–6% of all fractures and for approximately 30% of all elbow fractures^[1]. The complex anatomy of the distal end of the humerus, with its unique orientation of articular surfaces supported by a meager amount of cancellous bone, makes its fracture a constant challenge to orthopaedic surgeons^[2].

Materials and methods: A prospective study was conducted in Tertiary hospital for a period of 1 year. We studied 25 consecutive patients with distal humerus intercondylar (AO Type C) fracture, included in study as per inclusion criteria.

Discussion: Regardless of the method of treatment, substantial damage to the distal humerus usually results in some limitation of motion, pain, weakness, and possibly instability. Even minor irregularities of the joint surface of the elbow usually cause some loss of function. This can usually be minimized by early, accurate open reduction with sufficiently rigid fixation to permit immediate motion.

Conclusion: Delay in open reduction internal fixation with delayed soft tissue dissection leads to increased chances of elbow stiffness due to periarticular fibrosis. Use of conventional plates will suffice and more importance should be given to achieve good intercondylar reduction and pillar reconstruction.

Keywords: Distal humerus, intercondylar fractures, dual plating

Introduction

Distal humeral fractures account for approximately 2%–6% of all fractures and for approximately 30% of all elbow fractures^[1]. The complex anatomy of the distal end of the humerus, with its unique orientation of articular surfaces supported by a meager amount of cancellous bone, makes its fracture a constant challenge to orthopaedic surgeons^[2].

The complex shape of the elbow joint, the adjacent neurovascular architecture, and the sparse soft tissue envelope combine to make these fractures difficult to treat. Acceptable results have been reported in a majority of patients treated by open reduction and internal fixation^[3]. There is a bimodal distribution with respect to the patients age and gender. Peaks of incidence were described in males age 12 to 19 years and in females age 80 and older^[4].

The most common causes of these fractures are falls in the elderly population and sports injuries or road traffic accidents in the younger patients^[5]. Up to now, the rareness of distal humerus fractures has prevented any single surgeon from gaining sufficient experience in managing the different fracture patterns, resulting in differing recommendations for treatment^[6]. Majority of the distal humerus fractures (96%) have a complex pattern involving both the columns and the articular surface (AO type C injuries)^[7].

The only reliable method for restoring the normal alignment and contour of the distal humerus is operative exposure and direct manipulation of fracture fragments. However, fixation of fracture fragments must be stable enough to allow motion while ensuring union. In the early and middle parts of twentieth century, operative treatment was combined with devascularizing exposure, inadequate fixation, and cast immobilization. The result was often elbow stiffness and delayed healing. In this context, non-operative treatments, such as the so-called bag of bones technique (a short duration of immobilization in either a cast or a collar and cuff followed by mobilization as tolerated) were established as treatment alternatives^[8].

Aims and objectives

The aim of this study is

To evaluate the end result of surgical management of intercondylar fractures of distal end of humerus using dual plating with respect to:

- Bony union
- Functional outcome
- Range of movements

The minimum duration of follow up after which, these three outcomes were assessed was 6 months.

Materials and methods

A prospective study was conducted in a tertiary hospital for 1 year. We studied 25 consecutive patients with distal humerus intercondylar (AO Type C) fracture, included in study as per inclusion criteria. On admission of the patient, a careful history was elicited from the patient and/or attendants to reveal the mechanism of injury and the severity of trauma. The patients were then assessed clinically to evaluate their general condition and the local injury. Methodical examination was done to rule out fractures at other sites. Local examination of injured elbow revealed swelling, deformity and loss of function. Any nerve injury was looked for and noted. Distal vascularity was assessed by radial artery pulsations. Radiographic study was done taking AP and lateral x-ray of the involved elbow. CT scan was done in comminuted fractures especially to rule out capitellum fracture. All patients were informed before they were included in study and written consent for willful participation was taken. Fractures were classified as per AO classification and only AO type C were included in the study. All patients were treated surgically using posterior trans-olecranon approach with ulnar nerve exploration and fixation using dual plating and tension band wiring for olecranon osteotomy.

Selection criteria

Inclusion criteria

- Patients over 18 yrs of age.
- Patients with Intercondylar fractures of distal end of Humerus (AO Type C)

Exclusion criteria

- Open fractures
- Skeletally immature patients
- Fractures with neurovascular deficits
- Ipsilateral fractures of the same limb.
- AO type A and B distal humerus fractures.

Operative photographs



Fig 1: Pneumatic tourniquet



Fig 2: Implants used




Fig 3: Power drill

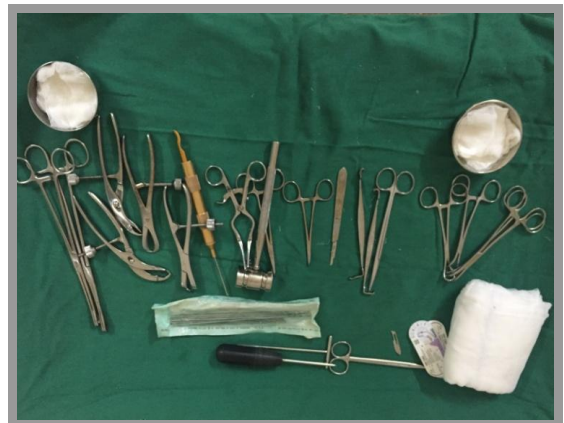

Fig 4: Instruments used

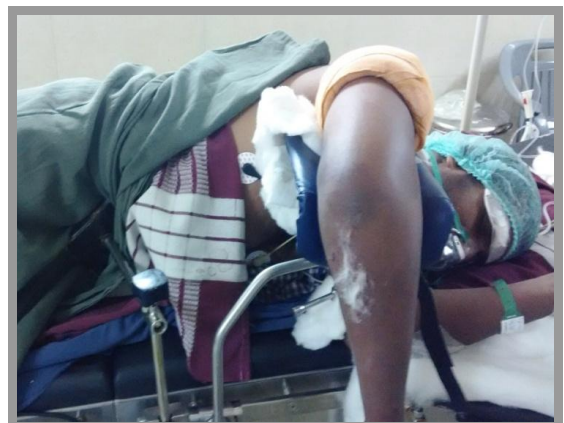

Fig 5: lateral position with tourniquet

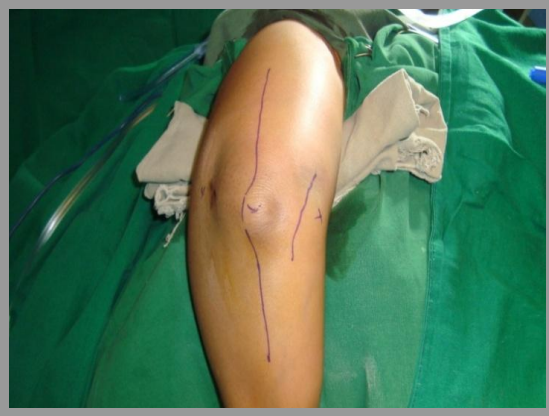

Fig 6: Skin incision marking

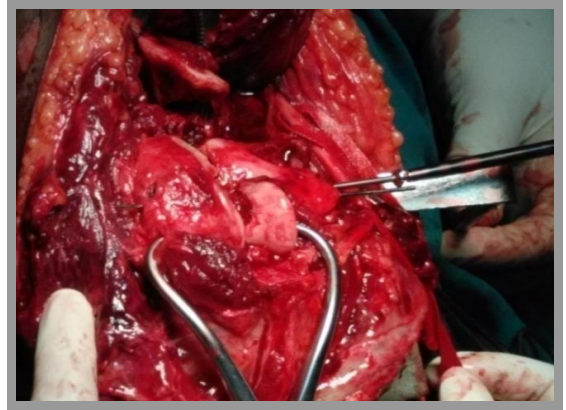


Fig 10: Fixation of condyles using reduction clamp Cancellous screw

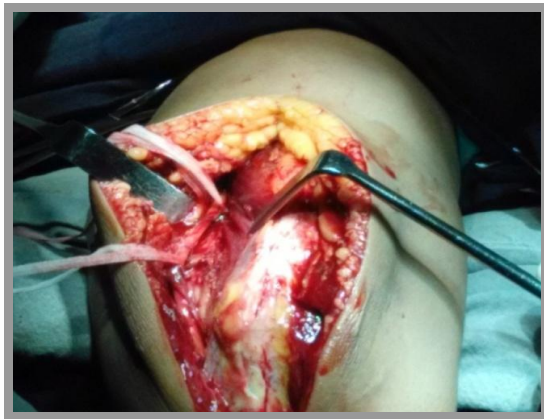

Fig 7: Ulnar nerve exposed and secured

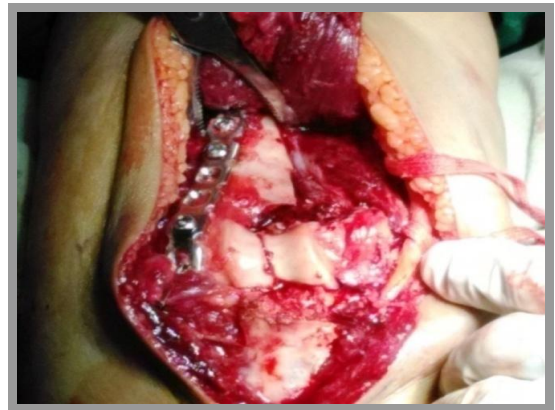

Fig 11: 3.5 mm recon plate fixed for posterior

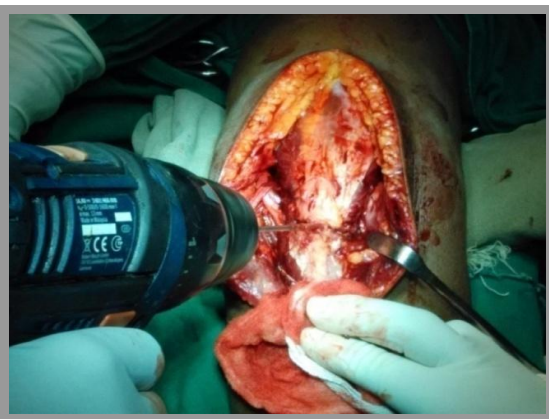

Fig 8: Olecranon osteotomy using multiple with 2 umbilical tapes drilling

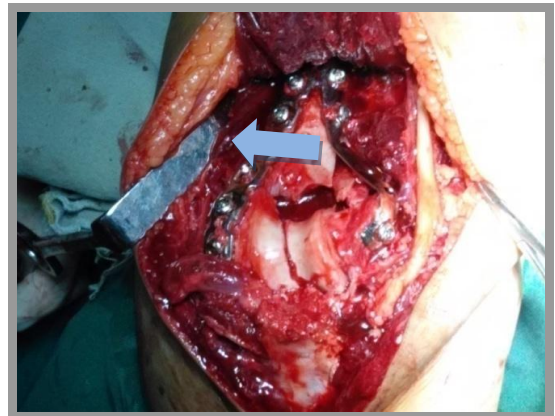


Fig 12: 2nd plate for medial aspect aspect of radial column of ulnar column

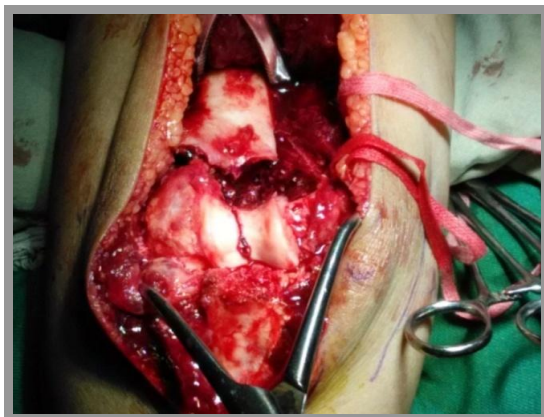

Fig 9: Reduction of condyles done with

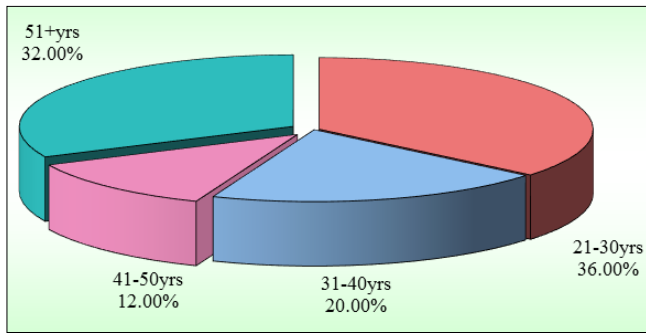
Results

Age incidence

In our study, distribution of age was between 21- 67 years. The youngest patient was 21 years & oldest was 67 years. The average age was 41.24 years with peak incidence of between 21-30 years.

Table 1: Distribution of samples by age groups.

Age groups	No of samples	% of samples
21-30yrs	9	36.00
31-40yrs	5	20.00
41-50yrs	3	12.00
51+yrs	8	32.00
Total	25	100.00
Mean age	41.24	
SD age	15.42	



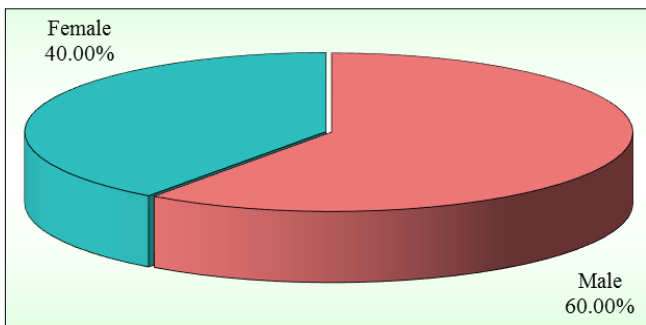
Graph 1: Distribution of samples by age groups

Gender distribution

There were 15 males & 10 females. Male patients constituted 60% and female were 40%. Male to female ratio is 1.5: 1.

Table 2: Distribution of samples by sex

Sex	No of samples	% of samples
Male	15	60.00
Female	10	40.00
Total	25	100.00



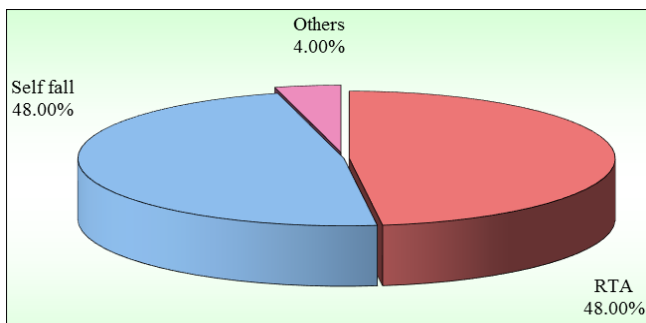
Graph 2: Distribution of samples by sex

Mechanism of injury

In our study 12 (48%) patients sustained fractures following Road Traffic Accidents, 12(48%) sustained fracture due to self fall and 1(4%) had fall from height.

Table 3: Distribution of samples by mode of injury

Mode of injury	No of samples	% of samples
RTA	12	48.00
Self fall	12	48.00
Others	1	4.00
Total	25	100.00



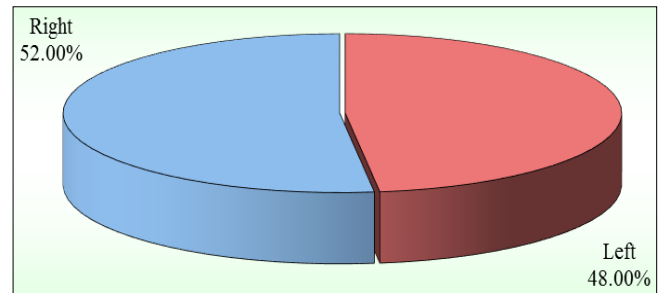
Graph 3: Distribution of samples by mode of injury

4. Laterality of fractures

Right upper limb was involved in 13(52%) cases and left upper limb in 12(48%) cases.

Table 4: Distribution of samples by sides effects.

Sides	No of samples	% of samples
Left	12	48.00
Right	13	52.00
Total	25	100.00



Graph 4: Distribution of samples by sides effects

Discussion

The management of distal humerus fractures has always held a particular interest for orthopaedic surgeons. They are often difficult to treat, and functional results are poor. Distal humerus fractures are commonly seen in young males and a severe fracture is associated with complications which may affect the socioeconomic status of the patient in the long run.

Fractures and fracture-dislocations involving the elbow joint often produce extensive soft tissue injury in addition to the bony injury. Supracondylar fractures without an intraarticular component usually can be treated nonsurgically in both children and in some adults where the patient is medically unfit/ demand is less. Fractures extending into the joint in either children or adults often require open reduction and internal fixation, but treatment should be individualized. To routinely perform open reduction and internal fixation of all fractures involving the condyles of the humerus is as unwise as the defeatist attitude of treating them all nonsurgically with early motion and accepting the results. Non operative measures often fail if articular surfaces are involved. The forearm musculature originating from the condyles tends to produce rotational redisplacement even when closed reduction is achieved. Preoperative roentgenograms should be carefully evaluated, and appropriate treatment should be instituted as soon as possible. If open reduction is delayed by indecision or follows failure of closed methods, the best time for surgery may be lost and soft tissue contractures, myositis ossificans, and much more difficult reconstructive procedures are more likely. However, soft tissue damage, skin abrasions, multiple injuries, or poor general condition of the patient may necessitate postponement of surgery.

Regardless of the method of treatment, substantial damage to the distal humerus usually results in some limitation of motion, pain, weakness, and possibly instability. Even minor irregularities of the joint surface of the elbow usually cause some loss of function. This can usually be minimized by early, accurate open reduction with sufficiently rigid fixation to permit immediate motion.

Conclusion

- Fractures of the distal humerus often produce extensive soft tissue injury in addition to the bony injury.
- Preoperative roentgenograms should be carefully evaluated and appropriate treatment should be instituted as soon as possible. CT scan can be of additional help especially in comminuted fractures to know the fracture pattern and to rule out capitellum fracture.

- Delay in open reduction internal fixation with delayed soft tissue dissection leads to increased chances of elbow stiffness due to periarticular fibrosis.
- Operative treatment with rigid anatomical internal fixation should be the line of treatment for all AO type C fractures, more so in young adults as it gives best chance to achieve good elbow function.
- During open reduction internal fixation, anatomic nature of articular surface should be given prime importance.
- We used transolecranon approach in all patients as it provides best visualization of articular surface.
- Use of conventional plates will suffice and more importance should be given to achieve good intercondylar reduction and pillar reconstruction.
- Vigorous, active physiotherapy is a must for good results.
- Stable fixation allows early, active and aggressive postoperative mobilization.
- 84% of our patients had good to excellent results as per Mayo elbow scoring system.

Summary

- A prospective study conducted at HOSMAT Hospital between September 2014 to May 2015.
- Sample size was 25 patients.
- Mean age was 40.24 years ranging over 21 to 67 years.
- There were 15 male and 10 female patients in our study.
- All fractures were classified as per AO classification and only AO type C fractures were included.
- There are 2 patients with Type C1, 9 patients with Type C2 and 14 patients with Type C3 fractures in our study.
- The Post operative follow up period ranged from 6 months to 15 months (Mean follow up - 9.4 Months) and the minimum follow up period was 6 months.
- Preoperative X rays of involved elbow AP and lateral views were done for all patients.
- All patients were treated surgically using posterior transolecranon approach with ulnar nerve exploration and fixation using dual plating and tension band wiring for olecranon osteotomy.
- Mayo Elbow Scoring System (MESS) was used for grading results at 2 months and 6 months follow up.
- Mean, standard deviation, mean difference and standard deviation difference were calculated for all groups.
- Student paired and unpaired t-test were used between groups for data analysis.
- Mean Fixed Flexion deformity of elbow at 2 months was 32.2 degrees
- Mean Fixed Flexion deformity of elbow at 6 months was 18.6 degrees
- Mean Flexion ROM arc at 2 months was 66.6 degrees.
- Mean Flexion ROM arc at 6 months was 96.6 degrees.
- Mean MESS score at 2 months was 70.2
- Mean MESS score at 6 months was 85.6
- Mean Flexion ROM arc in C1 fractures was 90 degrees.
- Mean Flexion ROM arc in C2 fractures was 103.3 degrees.
- Mean Flexion ROM arc in C3 fractures was 91.7 degrees.
- Mean MESS score in C1 fractures was 82.5
- Mean MESS score in C2 fractures was 91.42
- Mean MESS score in C3 fractures was 81.07
- The comparison between C1, C2 and C3 with respect to MESS scoring and flexion ROM arc was statistically not significant.

- There was no difference in results between parallel plating and orthogonal plating.
- Mean duration for radiological evidence for fracture union was 10.4 weeks.
- Complications: superficial infection-1, deep infection-1, implant failure-2, ulnar nerve neuropathy- 1, radial nerve neuropathy-1, myositis ossificans-1.
- No patients had non union and elbow instability.
- Depending on Mayo Elbow performance score we had excellent results in 11 Patients, good results in 10 patients, 2 patients had fair results and 2 patients had poor results.

References

1. Korner J, Lill H, Müller LP, Rommens PM, Schneider E, Linke B. The LCP-concept in the operative treatment of distal humerus fractures-biological, biomechanical and surgical aspects. *Injury*. 2003; 34(2):20-30.
2. Jupiter JB, Morrey BF. Fractures of the distal humerus in adults. In: Lampert R. *The elbow and its disorder*. 3rd ed. Philadelphia, London, New York, St. Louis, Sydney, Toronto: WB Saunders company, 2000, 293-329.
3. Kuntz JR, David G, Baratz ME. Fractures of the elbow. *Orthop Clin North Am Jun*, 1999; 30(1):37-61.
4. Robinson CM, Hill RM, Jacobs N, Dall G, Court-Brown CM. Adult distal humeral metaphyseal fractures: epidemiology and results of treatment. *J Orthop Trauma*. 2003; 17:38-47.
5. Lill H, Korner J, Josten C. Fractures of the distal humerus. In: Josten C, Lill H, eds. *Elbow Injuries, Biomechanics, Diagnostics, Therapy*. Darmstadt: Steinkopff, 2001, 163-82.
6. Jupiter JB, Morrey BF. Fractures of the distal humerus in the adult. In: Morrey BF. *The Elbow and its Disorders*. 2nd ed. Philadelphia Pa: WB Saunders, 1993, 328-36.
7. McCarty LP, Ring D, Jupiter JB. Management of distal humerus fractures. *Am J Orthop*. 2005; 34:430-8.
8. Jupiter JB, Neff U, Holzach P. Intercondylar fractures of the humerus: An operative approach. *J Bone Joint Surg Am*. 1985; 67(2):226-38.
9. Muller ME, Allgower M, Schneider R, Willenegger H. *Manual of internal fixation techniques recommended by the AO group*, 2nd ed. New York: Springer, 1979.
10. Helfet DL, Schmeling GJ. Bicondylar intraarticular fractures of the distal humerus. *Clin Orthop Relat Res*. 1993; 292:26-36.
11. O'Driscoll SW, Sanchez-Sotelo J, Torchia ME. Management of the smashed distal humerus. *Orthop Clin North Am*. 2002; 33(1):19-33.
12. Holdsworth BJ, Mossad MM. Fractures of the adult distal humerus: Elbow function after internal fixation. *J Bone Joint Surg Br*. 1990; 72(3):362-5.
13. Hitzrot JM. Fractures at the lower end of the humerus in adults. *Surg Clin North Am*. 1932; 12:291-304.
14. Lawrence XW. Fractures of the distal humerus. In: Robert WB, James DH, Charles CB, editors. *Rockwood and Green's fractures in adults*. 5th Edn, Philadelphia: Lippincott Williams and Wilkins, 2001, 954-971.
15. Riseborough EJ, Radin EL. Intercondylar T fractures of the humerus in the adult. A comparison of operative and nonoperative treatment in twenty nine cases. *J Bone Joint Surg Am*. 1969; 51(1):130-41.
16. Bickel WE, Perry RE. Comminuted fractures of the distal humerus. *JAMA*. 1963; 184(7):553-7.
17. Brown RF, Morgan RG. Intercondylar T shaped fractures of the humerus. *J Bone Joint Surg Br*. 1971; 53(3):425-8.

18. Gabel GT, Hanson G Bennett JB. Intraarticular fractures of the distal humerus in the adult. Clin Orthop Relat Res. 1987; 216:99-108.
19. Aitken GK, Rorabeck CH. Distal humeral fractures in the adult. Clin Orthop Relat Res. 1986; 207:191-7.
20. Henley MB. Intra-articular distal humeral fractures in adults. Orthop Clin North Am. 1987; 18(1):11-23.