



ISSN (P): 2521-3466  
ISSN (E): 2521-3474  
© Clinical Orthopaedics  
www.orthoresearchjournal.com  
2021; 5(1): 06-09  
Received: 04-11-2020  
Accepted: 07-12-2020

**Dr. Dilip Gupta**  
Consultant, Department of  
Orthopedics, District Hospital  
Basti, Alinagar Marg, Murlijiot,  
Basti, Uttar Pradesh, India

**Dr. Narendra Singh Kushwaha**  
Additional Professor,  
Department of Orthopaedic  
Surgery, King George's Medical  
University, Lucknow,  
Uttar Pradesh, India

**Dr. Vijay Gupta**  
Consultant, Department of  
Orthopedics, Siddhartha Ortho &  
Neuro Care Center Railway  
Godam Road Chapadiya,  
Coloney, Khalilabad, Sant Kabir  
Nagar, Uttar Pradesh, India

**Corresponding Author:**  
**Dr. Narendra Singh Kushwaha**  
Additional Professor,  
Department of Orthopaedic  
Surgery, King George's Medical  
University, Lucknow,  
Uttar Pradesh, India

## A prospective study of aseptic nonunion treatment of tibia with Ilizarov ring fixator in a tertiary care hospital

**Dr. Dilip Gupta, Dr. Narendra Singh Kushwaha and Dr. Vijay Gupta**

**DOI:** <https://doi.org/10.33545/orthor.2021.v5.i1a.250>

### Abstract

**Objective:** There is no gold standard for the treatment of nonunions of the tibia. The purpose of our study was to assess the results of treatment with the Ilizarov method in patients with aseptic nonunions of the tibia, depending on the employed treatment strategies and surgical techniques. To achieve union at nonunion site with correction of limb length discrepancy and correction of deformity with early function and mobilization.

**Methods:** The operators used one of two treatment strategies: neutral fixation without compression or continued compression. The following were assessed: rates of union, ASAMI bone scores, ASAMI functional scores, treatment time, complications, duration of hospital stay. It is prospective study of treatment of aseptic nonunion of shaft tibia. As we have taken 35 patients of tibial nonunion. All relevant pre and perioperative information and complications were recorded. Also assessment of functional outcome was made.

**Results:** We also analyzed the differences in time to union in the subgroup of patients with at least one risk factor for disturbances in fracture healing. The following risk factors were considered: diabetes mellitus, corticosteroid therapy, smoking, advanced lower extremity vascular disease, and alcohol dependence. Sample size in our study was of 32 out of 35 cases has united, about 91% success rate. The average duration of nonunion was about 14.5 months, average union time (fixator removal) is about 6.2 months. Two of our patient were showing poor tolerance to Ilizarov external fixator changed to other modality.

**Conclusion:** The Ilizarov method offers a greater extent of correction in posttraumatic deformities and helps better correct posttraumatic limb shortening in comparison to the results achieved with internal osteosynthesis methods. Therefore Ilizarov technique is very helpful in treating nonunion of long bones and has advantage of early wt. Bearing, movements of nearby joints encouraged which reduces edema and joint stiffness.

**Keywords:** Nonunion shaft tibia, Aseptic nonunion, Ilizarov ring fixator

### Introduction

Tibia pseudarthroses represent a wide spectrum of diagnoses that can be divided into several subtypes. Based on the extent of pathological mobility, pseudarthroses can be classified as stiff or mobile. The amount of bone fragment perfusion leads to hypertrophic (well-perfused) or atrophic (inadequately perfused) pseudarthroses. Another subgroup constitutes infected pseudarthroses, where a superimposed infection is an additional factor that worsens the prognosis. Due to the variety of pseudarthrosis types (presented above), there is no single universal surgical technique, and each case must be considered individually [1, 14]. Despite the progress in surgical methods and the development of novel implants, treatment of bone nonunion remains a challenge for orthopedic surgeons. Extended therapy, which can last months or even years, is expensive and adversely affects the patients' professional and personal life [2, 15, 16].

Nonunions of the tibia may be associated with: low-density bone tissue, bone loss, adjacent soft-tissue damage, limb shortening, limb deformities, and joint contractures. All of these adversely affect the course of treatment and increase the risk of treatment failure There are many modalities of treatment of aseptic nonunion of shaft tibia, which have evolved during last so many years, all aims at achieving the common goal of union of fracture and restoration

of function. Management of nonunion shaft tibia has been described as difficult and discouraging because of lesser blood supply to area owing to anatomical location where there is less muscular attachment. Improvement in internal fixation system have proved sufficiently stable fixation to allow active and passive range of movement of adjacent joint but Ilizarov external fixator continues to be an effective and versatile method for the treatment of difficult nonunions [5, 6] Ilizarov method is axially elastic and allows weight bearing and function, which is important for union, it corrects associated deformity [3, 4].

### Material and method

We have collected the data for this study in Department of Orthopedics, District Hospital Basti, Alinagar Marg, Murlijot, Basti, Uttar Pradesh and Department of Orthopedics, King George's Medical University, Shah Mina Rd, Chowk, Lucknow, Uttar Pradesh over a period of two years. Duration for Follow up ranged from 2 to 4 years. All the patients were hospitalized and managed according to a standard protocol, which include preoperative evaluation starting of compression distraction osteogenesis after stitch removal. Discharge with advise of compression distraction follow up on OPD basis.

**Preoperative Planning** [3, 4]: Each case of non union was classified according to AO and Paleys classification, orientation of non union with special consideration to atrophic / hyper tropic/ gap non union/need of corticotomy for shortening keeping the preconstruct ready. All required blood investigations and radiographs were done. Physician fitness taken.

**Operative Procedure:** Atrophic nonunion:- Under IITV control fracture site is exposed bone ends are visualized shingling is done upto 2 to 3cm on either side freshening done till 15 unctuate bleeding appears (i.e. paprika sign) after release of tourniquet medullary canal on both the fragment are reamed and cancellous bone grafts are placed taken from iliac crest. Fibulectomy It is done about 8 cm above the lateral malleolus.

**Hypertrophic nonunion:** Ilizarov frame applied and nonunion site stabilized for compression distraction osteogenesis.

**Oligotrophic nonunions:** Requires exploration of nonunion site reaming of canals freshening bone grafting and external stabilization.

**Application Of Ilizarov Ring Fixator:** A four ring pre construct [6] inserted in leg under IITV pass a reference wire at proximal tibial level parallel to the joint using tibial safe zones and fix it to the first ring, then pass a K wire in to the distal tibia 2 cm proximal to joint line and fix it to the distal ring. Then pass another wire from the proximal tibia making maximum possible angle to the reference wire is passed through safe zone, another wire is pass through the fibula before passing this wire just put a thumb over common peroneal nerve to protect it and displaced it away from the course of wire fix this two wire to the proximal tibial ring, then another two wires are passed at distal tibial site and fix it to 4th ring, then one K wire is passed in each of fragment and fixed to 2nd and 3rd ring. Insertion of shanz pin - Rancho cubes are attached to the 2nd and 3rd ring in such a way that they are at anteromedial surface of the tibia and 6 mm tapered shanz pin is passed and fixed to rings. Corticotomy it is defined is sectioning of cortex of bone at the same time preserving the periosteal and nutrient artery integrity supplying

the medullary canal [7, 10]. In some cases of paley's type B2 and B3 patient required a proximal tibial corticotomy.

### Post Op. Management

Day 1: Walking with walker full weight bearing, dorsiflexion by alkathien foot plate. And movements of toes, ankle and knee joint.

Day 3: Corticotomy dressing 2) Daily wire and pin track care

Day 7: Starting of compression at fracture site and distraction at corticotomy site @ 0.25mm four time a day.

Day 12: Suture removal.

Day 14: Check x-ray for fracture site and corticotomy site.

Discharge patient with following instruction Distraction at corticotomy and compression at fracture site. Daily wire tract dressing, physiotherapy, report immediately if pain or wire breakage. Follow up visit after 15 days. Follow Up Visit Following things were checked

1. X-ray - distraction and regeneration, Signs of union at nonunion site
2. Wire site for superficial infection
3. Movements of adjacent joints 4
4. Degree of pain Removal of fixator:- Between 12 to 16 weeks 7,8,11 Depends on X-ray 1) corticalization of regenerate
5. Union at nonunion site clinically
6. No pain at nonunion site
7. No mobility on removing bars - AP, Mediolat, rotational Post fixator removal care –
8. Consider plaster of paris cast with full weight bearing for 4 weeks and further as per condition
9. After cast removal consider physiotherapy for strengthening

### Criteria for Assessment Of Results 4,7,10 Satisfactory results

1. Achievement of union
2. Angular deformity

### Functional Results

1. Patient walking full wt. Bearing without walking aids.
2. Absences of pain and infection
3. Full ROM of adjacent and joint.
4. Plantigrade foot with no equines contracture

### Observation and results

**Table 1:** Age distribution

| Age            | No. of Cases | Percentage (%) |
|----------------|--------------|----------------|
| 20-30 Years    | 14           | 40%            |
| 30-40 Years    | 12           | 34.28%         |
| 40-50 Years    | 7            | 20%            |
| Above 50 Years | 2            | 5.71%          |
| Total          | 35           | 100%           |

**Table 2:** Sex distribution

| Sex    | No. of cases | Percentage (%) |
|--------|--------------|----------------|
| Female | 29           | 82.85%         |
| Male   | 6            | 17.15%         |
| Total  | 35           | 100%           |

**Table 3:** Side of nonunion

| Side  | No. of cases | Percentage (%) |
|-------|--------------|----------------|
| Right | 21           | 60%            |
| Left  | 14           | 40%            |
| Total | 35           | 100%           |

**Table 4:** Type of nonunion according to weber classification (10)

| Type         | No. of cases | Percentage (%) |
|--------------|--------------|----------------|
| Artropic     | 13           | 37.14%         |
| Hypertrophic | 18           | 51.43%         |
| Oilgotrophic | 4            | 11.42%         |
| Total        | 35           | 100%           |

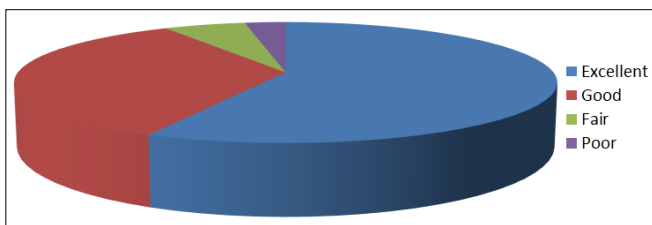
**Table 5:** Type of nonunion according to paley's classification

| Type of nonunion | No. of cases | Percentage (%) |
|------------------|--------------|----------------|
| A1               | 13           | 40%            |
| A2.1             | 0            | 0%             |
| A2.2             | 18           | 51.42%         |
| B1               | 0            | 0%             |
| B2               | 3            | 11.42%         |
| B3               | 1            | 8.57%          |

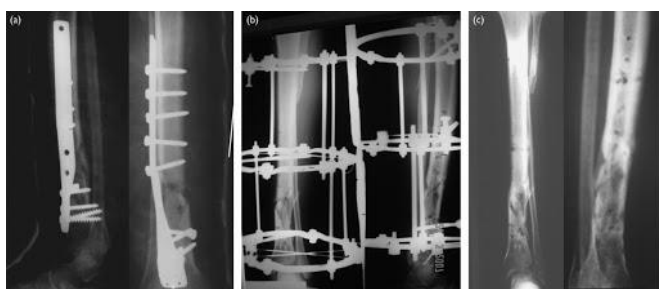
**Table 6:** Results

| Results   | No. of cases | Percentage (%) |
|-----------|--------------|----------------|
| Excellent | 20           | 57.14%         |
| Good      | 12           | 34.28%         |
| Fair      | 2            | 5.71%          |
| Poor      | 1            | 2.85%          |

Excellent to good results were seen in 91.42% of cases as shown in table 6 and Figure 1

**Fig 1:** Results post follow up of our study**Table 7:** Comparative series

|                               | Gonzalez <i>et al.</i> | Current series |
|-------------------------------|------------------------|----------------|
| No of cases                   | 45                     | 35             |
| Average time of nonunion      | 10.7mon                | 14.5 months    |
| Average healing time          | 5.4 mon                | 6.2 months     |
| No of cases united            | 39                     | 32             |
| Results Good                  | 36                     | 32             |
| Fair                          | 3                      | 2              |
| Poor                          | 6                      | 1              |
| Poor tolerance                | 4                      | 2              |
| Bone grafting                 | 00                     | 13             |
| Achilles lengthening          | 1                      | 00             |
| Pin tract infection           | .....                  | 6              |
| Deep intramedullary infection | .....                  | 1              |



**Fig 2:** (a) Radiograph of a 40-year-old man showing failed internal fixation, malunion in form of 32° procurvatum and 12° varus, and a broken plate. (b) after removal of the plate and application of the Ilizarov fixator, showing good correction (c) at the end of follow-up, showing healing of the fracture but with about 7° valgus.

## Discussion

The Motive of this study was to assess the treatment outcomes in patients with aseptic posttraumatic pseudarthrosis of the tibia treated with the Ilizarov method and to compare them with the outcomes of treatment via internal osteosynthesis. The Ilizarov method has been used at our center for over 30 years. Over this period, the technique has been employed in the treatment of extensive fractures with soft tissue loss, bone nonunion, and in other indications. Nonunion of shaft tibia is more common than nonunion of any other long bone in the body; this is because of lack of soft tissue surrounding the tibia and the subcutaneous nature of the tibial fractures being compound. In spite of many modalities for the treatment of aseptic nonunion of shaft tibia Ilizarov external fixator in treatment of choice and a versatile modality of treatment the existing orthopaedics literature has recorded widely varying results [2, 11, 12]. This present series of treatment of aseptic nonunion of shaft tibia by Ilizarov external fixator has been aim to try and reduce morbidity this series has 35 cases of aseptic nonunion shaft tibia in adults by Ilizarov external fixator. This series has got 18 cases out of 35 cases (52%) of hypertrophic nonunion 13 cases i.e. (37%) of atrophic nonunion 4 cases i.e. (11%) of oligotrophic nonunion. Among these cases majority of the cases i.e. 26 cases out of 35 cases were in the age group of 20-40 years (75%) youngest patient being of 20 years as the tibial fractures are associated with road traffic accidents majority of nonunions were males about 29 cases out of 35 cases i.e. 83% are males. Right and left side were in the proportion of 3:2 i.e. left 60% right 40% About 22 cases out of 35 cases i.e. (63%) were having closed fractures and 13 cases out of 35 i.e. (37%) were having compound fractures. Majority of cases i.e. 26 cases out of 35 cases (75%) were treated in one or the other modality of surgery and rest of i.e. 9 cases (25%) were treated in the form of above knee cast. According to paley's classification [3, 4, 10] amongst type –A 13 cases out of 35 i.e. (40%) were type A1 and 18 cases out of 35 i.e. (51%) were type A2.2 i.e. stiff nonunion without deformity. Average duration of nonunion is about 14.5 months longest being 72 months and shortest being 4 month. All the patients were treated with standard protocol given pre operative antibiotic. As in Figure 2. For the atrophic nonunion cases we have explored the fracture site removed all fibrous tissue at the fragments done freshening/shingling iliac crest bone grafting fibulectomy if it is united and stabilized it with a four ring Ilizarov external fixator. In the Gonzalez series 9 39 out of 45 cases about 86.66% has united his average duration of nonunion was 10.7 months His average union time was 5.4 months none of his cases has required bone graft 4 of his patients were showing poor tolerance to external fixator one of his case required tendo Achilles lengthening. In present series 32 out of 35 cases has united, about 91%. The average duration of nonunion was about 14.5 months average union time (fixator removal) is about 6.2 months 2 of our patient were showing poor tolerance to Ilizarov external fixator. All atrophic cases about 13 were augmented with cancellous bone graft none of the hypertrophic nonunion cases were explored In 4 oligotrophic nonunion cases only fracture site was explored and intramedullary canals were reamed and stabilized with Ilizarov ring assembly. Six of our cases developed superficial pin tract infection, which was tackled with oral antibiotics and local injection of gentamycin with no further complication. Two of our cases were showing signs of persistent nonunion clinically as well as radiologically were later on treated with locked intramedullary nailing which later on united solidly. One case developed intramedullary infection and was converted into infected nonunion which was

later on treated with vancomycin impregnated V-nail along with Ilizarov assembly which was united solidly along with cure of infection.

### Challenges

No surgery is devoid of complication and problems have its share in it. Following Complications are encountered.

1. Pain: - post op pain seen in few patient but could be well managed by analgesics. Limb elevation and rest about 80% of patient had pain at one or two pin site.
2. Superficial pin tract infections:- It was seen more with postero medial wire on first ring i.e. tibio fibular about 55% patient suffered from pin tract infection at one or more site which was treated with antibiotic one or two may required injection of local gentamicin
3. Adjacent neuro vascular injury:- Fortunately in this series there was no case reported to have neuro vascular injury.
4. In this series 3 cases (8.57%) were reported to have ROM

### Conclusion

Most important advantage of the Ilizarov technique is early weight bearing on first post op. day, movements of near by joint is encouraged, which reduces edema and joints stiffness. The Ilizarov method offers a greater extent of correction in posttraumatic deformities and helps better correct posttraumatic limb shortening in comparison to the results achieved with internal osteosynthesis methods. Ilizarov method offers advantage was that fixator assembly can be later on adjusted in wards. Early ambulation and wt. Bearing reduces the hospitalization as the patient can be discharged early from hospital and treated on OPD basis. Ilizarov method is characterized by high effectiveness in the treatment of disturbances in tibial fracture healing.

1. Males were predominant in the series
2. Nonunion was found to be commoner in the age group of 20-40 yrs
3. Poor stabilization in previous surgery was found to be commoner cause
4. Average duration of nonunion was 14.5 months
5. Average duration for union was 6.2 months
6. Bone grafting was done in all atrophic cases
7. Union was seen in all 35cases
8. Good to excellent results were seen in 92% of cases

### References

1. Brinker Mark R, O'connor Daniel P. Outcomes of Tibial nonunions in older adults following treatment using the Ilizarov method. *Journal of Orthopedic Trauma* 2007;21(9):634-642.
2. Modification of Ilizarov external fixator for aseptic nonunion of the clavicle; Tomic, Slavco: *Jour. Of Ortho. Trauma* 2006;20(2):122-128.
3. Paley D, Marc DC. Ilizarov bone transport treatment for bone defects; *Jour. of ortho. Trauma* 2000;14:76-85.
4. Paley D, Catagni MA, Argnani F, Villa A, Benedetti GB, Cattaneo R. Ilizarov treatment of tibial nonunions with bone loss. *Clin Orthop Relat Res* 1989;241:146-65.
5. Aronson J. The biology of Distraction osteogenesis: Operative principles of Ilizarov by ASAMI group.
6. Bangili G, Paley D. The compression distraction apparatus of Ilizarov :The Ilizarov methods 1990, 3-5.
7. Bianchi Maiocchi A. Operative principles of Ilizarov A.S.A.M.I. GROUP PG-9.
8. Catagni M. The radiographic classification of bone during

distraction: Operative principles of Ilizarov by ASAMI group 53-57.

9. Eduardo Garcia, Cimbrello Jose C, Gonzalez D. *CORR* 419, 2004, 65-70.
10. Kulkarni GS. *Textbook of Orthopedics and trauma* 2ND edition 2004, 1542-61.
11. Lammens Johan, Bauduin Gilles, Driesen Ronald. Treatment of nonunion of humerus using Ilizarov external fixator. *CORR* 1998;353:223-230.
12. Babhulkar Sudhir, Pande Ketan. Nonunion of diaphysis of long bones, *CORR* 2005;431:50-56.
13. Ayed al Shahrani, Tendla J. effectiveness of Ilizarov frame fixation on functional outcome in aseptic tibial: gap nonunion; *journal of Taibah university of medical sciences* 2015;10(2):216-221.
14. Ferreira N, Marais LC. Management of tibial non-unions according to a novel treatment algorithm. (In eng). *Injury* 2015;46(12):2422-7. <https://doi.org/10.1016/j.injury.2015.09.040>.
15. Hierholzer C, Friederichs J, Glowalla C, Woltmann A, Buhren V, von Ruden C. Reamed intramedullary exchange nailing in the operative treatment of aseptic tibial shaft nonunion," (in eng), *Int Orthop* 2017;41(8):1647-53. Doi: <https://doi.org/10.1007/s00264-016-3317-x>. *Int Orthop*.
16. O'Halloran K *et al*. Will my tibial fracture heal? Predicting nonunion at the time of definitive fixation based on commonly available variables. (in eng), *Clin Orthop Relat Res* 2016;474(6):1385-1395. Doi: <https://doi.org/10.1007/s11999-016-4821-4>. *Clin Orthop Relat Res*.