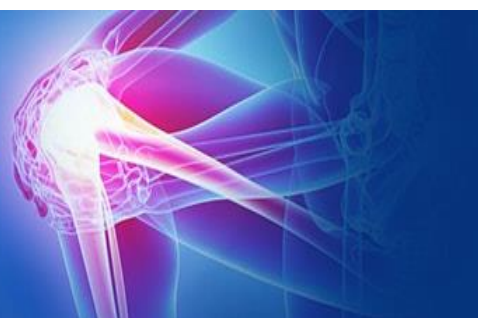



ISSN (P): 2521-3466
ISSN (E): 2521-3474
© Clinical Orthopaedics
www.orthoresearchjournal.com
2020; 4(1): 33-38
Received: 19-11-2019
Accepted: 23-12-2019

Dr. Haresh Rana
3rd Year Resident, Department
of Orthopaedics, B.J. Medical
College, Ahmedabad, Gujarat,
India

Dr. Kerul Ninama
2nd year Resident, Department of
Orthopaedics, B.J. Medical
College, Ahmedabad, Gujarat,
India

Dr. Rahul Gameti
1st year Resident, Department of
Orthopaedics, B.J. Medical
College, Ahmedabad, Gujarat,
India

Dr. Samsuddin Khoja
1st year Resident, Department of
Orthopaedics, B.J. Medical
College, Ahmedabad, Gujarat,
India

Correspondence

Dr. Samsuddin Khoja
1st year Resident, Department of
Orthopaedics, B.J. Medical
College, Ahmedabad, Gujarat,
India

A clinical study of surgical management of olecranon fractures

Dr. Haresh Rana, Dr. Kerul Ninama, Dr. Rahul Gameti and Dr. Samsuddin Khoja

DOI: <https://doi.org/10.33545/orthor.2020.v4.i1a.198>

Abstract

Background and Objective: Olecranon fractures are one of the most commonly seen orthopaedic injuries in the emergency room. Fractures of the Olecranon process of the Ulna typically occurs because of a motor-vehicle or motorcycle accident, a fall, or assault. The accepted management for Olecranon fractures is for Non displaced fractures short immobilization followed by gradually increasing range of motion. When displaced, Open reduction and internal fixation with k-wires and figure of eight tension band wiring for simple transverse fractures and olecranon hook plate for comminuted fractures the present study is undertaken to evaluate the results of surgical management, the merits and demerits and to assess elbow joint motion and stability after the procedure.

Materials and Methods: It is a prospective study which was carried out from September 2017 to September 2018 at B.J. Medical College, Ahmedabad. In this study period of 25 cases of fracture olecranon treated by Tension band wiring with Kirshner wire for Simple transverse fractures and Olecranon hook plate for Comminuted fractures

Results: In our series, majority of the patients were males, middle aged, with road traffic accident being the commonest mode of injury, Most of the cases were Type II B fractures i.e., oblique and transverse fractures according to Colton's classification Surgery was performed with in 3.48 average days, Union was noted clinically and radiologically and functional evaluation was done by Mayo elbow performance score. Excellent results was present in 18 patients (72%), 4(16%) good and 3(12%) fair with no poor results.

Interpretation /Conclusion: From the present study it is concluded that the technique of open reduction and internal fixation with Kirschner wires and tension band wiring for simple transverse and oblique fractures and olecranon plate fixation for comminuted fractures are effective means and gold standard technique of treating fractures of olecranon and is based on sound biomechanical principle.

Keywords: Olecranon fractures, open reduction, internal fixation

Introduction

Olecranon fractures are one of the most commonly seen orthopaedic injuries in the emergency room. Fractures of the Olecranon process of the Ulna typically occurs as a result of a motor-vehicle or motorcycle accident, a fall, or assault.

Non displaced fractures can be treated with a short period of immobilization followed by gradually increasing range of motion.

When displaced, open reduction and internal fixation are usually required to obtain anatomical realignment of the articular surface and restore normal elbow function. The fixation should be stable, allow active elbow flexion and extension and promote union of the fracture^[1].

In the past, closed reduction and plaster cast application was the treatment for fracture of olecranon. But, prolonged immobilization with its own complications increased the morbidity and mortality of patients^[2].

So keeping this in consideration, it has become important to intervene surgically. The active mobilisation after surgery will restore the patient to normal function as early as possible. The early and active movement not only prevents the tissue from fracture disease but greatly influences the quality and rapidity of fracture union.

Stable internal fixation with figure-of-eight tension-band wire fixation for simple transverse fractures allows early motion to minimize stiffness. The K-wire used in AO tension – band

technique resist shearing force better than the figure of eight wire alone. So this gives a good result by converting tensile force to compressive at the fracture site^[1, 3, 4].

For comminuted fractures, distal fractures involving coronoid process, oblique fractures, Plate fixation is most appropriate mode of treatment. For comminuted fractures and non unions, a dorsally applied Olecranon hook plate is used^[1, 4, 5].

This dissertation is directed towards the clinical evaluation of Surgical management of Olecranon fractures by tension band wiring for simple transverse fractures and plate fixation for comminuted fractures.

Aim: To clinically evaluate the result of tension band technique for simple transverse fracture & plate fixation for comminuted fracture of olecranon

Materials and Methods

The present study consisted of 25 cases of fracture olecranon treated by Tension band wiring with Kirshner wire for Simple transverse fractures and Olecranon hook plate for Communitated fractures at the B.J. Medical College, Ahmedabad between September 2017 to September 2018. Study was conducted with due emphasis for clinical observation and analysis of results after surgical management of fractures of olecranon by Krishner wires with Tension band wiring and Olecranon hook plate.

Immediate Management

Immediately on arrival of the patient, if he/she was in shock, the level of shock was noted and managed accordingly. X-ray of the part was taken and the elbow was immobilized in whatever the position patients presence in a A/E POP posterior slab. The affected limb was kept elevated. Analgesics and antibiotics were given if necessary. Patient was then prepared for surgery and anaesthesia after the pre-anaesthetic checkup.

History

A detailed history was elicited from the patients. The duration of injury and mechanism of injury, whether due to direct or indirect violence was noted. Whether trauma was due to traffic accidents, assault, fall from a height, industrial injury or domestic accident were specifically asked and also other associated injuries were noted. Enquiry was made to note the severity of pain and swelling and also about the active movements of the affected joint and external wound.

General Examination

A thorough clinical examination was done regarding the general condition of the patient and any associated systemic disease was ruled out. General survey was made to rule out other associated injuries. Motor vehicle accident injuries becoming more common, many patients were brought in a state of shock. Immediately the level of shock was estimated and managed accordingly.

Local Examination

It was done in following order: Inspection followed by Palpation, Movements, Measurements and Associated injuries.

On inspection the following points were noted: Attitude of the limb, whether the elbow was swollen and if so the size, shape and extent of the swelling, condition of the skin over the swelling and presence of any abrasions, contusions and lacerations.

On palpation, the following points were noted: Signs of fracture i.e. tenderness, bony irregularity and crepitus. presence of any gap or sulcus, any distal neurovascular deficit, both active and

passive movements of the elbow (flexion and extension) and forearm (supination and pronation) were noted and compared with normal side, the circumference of the injured elbow was measured and noted and compared with the normal elbow.

Investigations: Routine examination of blood and urine were carried out. Radiographic examination included standard X-ray in anteroposterior and lateral views for confirmation of diagnosis and also to know the type of fracture.

Patients: The patients falling into the inclusion criteria were selected for the study. The inclusion criteria for the study were: Age of the patient, extent of damage to the articular surface and degree of comminution. The patients of extremes of age and the patients in whom operative risk was great were not taken up for surgery.

Surgical Procedure

Anaesthesia - The operation was performed under general anaesthesia or brachial block.

Position and Tourniquet - Mid arm tourniquet was applied with patient in supine or lateral position. Site of the surgery was thoroughly painted with iodine and spirit and draped.

Exposure – Exposure of the olecranon was done by Campbell's posterolateral approach. A vertical incision was taken over the posterior aspect of the elbow about 2.5cms proximal to olecranon, curving distally along the lateral aspect of olecranon reaching the subcutaneous border of the ulna and extending distally for about 7.5 cms distal to olecranon. Fascia was incised along the line of skin incision and fracture site was exposed. Fracture haematoma was cleared off and the fracture site was gently curettage. Accurate anatomical hairline reduction was achieved and held with either reduction clamp or long towel clip.

K-wires was introduced parallel from the tip of the olecranon i.e., the proximal fragment across the fracture site to the distal fragment. Periosteum was stripped from the shaft of ulna distal to fracture site and a transverse hole was drilled approximately 3 to 5cms distal to fracture site. A No.18 stainless steel malleable wire was passed through this transverse hole and crossed over the posterior surface of olecranon in a figure-of-eight manner and then passed around the protruding Kirschner wires and tightened using AO tensioner and then secured with a twist. Bend the proximal ends of the Krishner wires 1800 and tap the cut ends back into the proximal fragment. Accuracy of reduction was checked and stability was tested by moving the joint. Wound closed in layers and sterile dressing and compression bandage given.

For communitated olecranon fracture, Exposure of the olecranon was done by Campbell's posterolateral approach. A vertical incision was taken over the posterior aspect of the elbow about 2.5cms proximal to olecranon, curving distally along the lateral aspect of olecranon reaching the subcutaneous border of the ulna and extending distally for about 7.5 cms distal to olecranon. Fascia was incised along the line of skin incision and fracture site was exposed. Fracture haematoma was cleared off and the fracture site was gently curettage. Accurate anatomical hairline reduction was achieved and held with either reduction clamp olecranon hook plate was applied on the posterior surface with cortical screws after drilling and tapping, through wash was given, wound closed in layers and sterile dressing was applied.

Postoperative Management: All the patients were treated with Inj. Cefotaxime 1gm twice daily for 5 days followed by Tab

Cefixime 200mg daily for 5 days. Some cases were treated with Inj. Amikacin 500mg daily for 3 days. Anti-inflammatory analgesics, Inj. Diclofenac for 3 days followed by Tab Diclofenac 50mg twice daily were prescribed. Affected limb was elevated and patient was asked to perform finger movements on day 1. Elbow movements was advised from 3rd postoperative day. For comminuted fractures and unstable fixations, the limb was immobilized in A/E POP posterior slab with elbow in 90° flexion for 2 weeks. For other fractures the limb was mobilized by about 3rd postoperative day.

Follow Up

This part of the study should be done very carefully and meticulously. In our study the patients on discharge were advised to report for follow up after 6 weeks and 12 weeks and thereafter every 3 months. The result is assessed 3 months after the procedure. At follow up a detailed clinical examination was done and patient was assessed subjectively for the symptoms like pain, swelling, restriction of joint motion. On clinical examination, swelling of the joint, tenderness, movements of the elbow joint, prominence of head of cancellous screw, nutrition and power of the muscles acting on the joint were noted. Patients were instructed to carry out physiotherapy in the form of, active flexion-extension and pronation-supination without loading. Patients were instructed to carry out physiotherapy in the form of active flexion extension and pronation supination without loading. Check x-ray were taken and when final x-ray showed union, implant was removed. In all patient's duration after which they returned to job was noted.

Evaluation of Results

Although there are many methods of evaluation of results given by many authors, the treated olecranon fractures by Tension band wiring and olecranon hook plate were evaluated in our study with Mayo Elbow Performance score (MEPS) (According to Morrey BF, An KN. Functional evaluation of the elbow.)⁶ for functional outcome and Standard radiographs for radiological outcome.

Results

Study consisted of 25 cases of fractures of the olecranon treated by Tension band wiring with Kirshner wire for Simple transverse fractures and Olecranon hook plate for comminuted fractures from September 2017 to September 2018 at B.J. Medical College, Ahmedabad. All cases were followed up periodically during the period 2010-2012. The following are the observations made and the available data are analysed as follows.

Age Incidence

Table 1: Showing the Age Incidence

Age in years	21-30	31-40	41-50	51-60
No. of cases	6	8	4	7
Percentage	24%	32%	16%	28%

The age of this patients ranged from 21-60 years, with fracture association being most common in 3rd decade i.e. 8 cases (32%) and mean age of 40.5 years.

In this series, 6(24%) patients between 21-30 years, 8 (32%) patients between 31-40 years, 4 (16%) patients between 41-50 years and patients below 51-60 years were 7(28%).

2. Sex Incidence

Table 2: Sex Incidence

Sex	No. of cases	Percentage
Male	17	68%
Female	8	32%

In the present series, males were 17 (68%) and females were 8 (32%) with M: F ratio of 2.2:1.

3. Side of Involvement

Table 3: Side of Involvement

Side involved	No. of cases	Percentage
Right	16	64%
Left	9	36%

4. Mode of Injury

Table 4: Mode of Injury

Mechanism of injury	No. of cases	Percentage
Road traffic accidents	13	52
Fall from height	11	44
Assault	1	4

In this series 13 cases (52%) were due to road traffic accidents, 11 cases (44%) were due to fall and 1(4 %) patient due to assault.

5. Type of Fractures: (Colton's Classification)⁵⁵

Table 5: Type of Fractures

Type of fractures	No. of cases	Percentage
1) Un-displaced and stable fractures	-	-
2) Displaced fractures		
A) Avulsion fractures	1	4
B) Oblique and transverse fractures	19	76
C) Comminuted fractures	5	20
D) Fracture – dislocation	-	-

6. Duration

Table 6: Showing the Time Interval between Injury and Surgery

Duration	No. of Cases	Percentage
2-10 days	25	100%

No case was operated as a surgical emergency. All the cases were operated on our regular operation theatre days, at the earliest possible time. The patients were operated upon with an average period of 3.48 days after the injury.

7. Associated Injury

Table 7: Associated Injury

Associated injuries	No. of cases	Percentage
Radial head fracture	2	8

In the present series, two patients had radial head fracture, one patient underwent radial head excision and one patient underwent k-wire fixation.

8. Incision

All the cases were operated upon by Campbell's posterolateral approach.

9. Immobilization

Two cases of oblique fractures of the olecranon where in it was difficult to obtain rigid fixation and comminuted fractures were immobilized with A/E posterior P.O.P. slab for a period of two weeks.

All the other cases were encouraged active elbow motion from the third postoperative day.

10. Duration of fracture union

The fracture was considered united when clinically there was no tenderness and no subjective complaints and when radio logically the fracture line was not visible.

Table 8: Time of Union

Time of union	No. of cases	Percentage
< 4 months	17	68
4-6 months	8	32
6months- 1year	-	-
Non union	-	-
Total	25	100

In this series, 17 (68%) patients had sound union in less than 04 months, 08 (32%) had union between 4-6 months and no patient had non union.

Mayo elbow performance score (MEPS) ^[06] Section -1 Pain Intensity

Table 9: Pain Intensity

Score	Pain Intensity	No. of cases	Percentage
45	None	18	72
30	Mild	7	28
15	Moderate	-	-
-	Severe	-	-

In the present series 18(72%) patients were pain free and 7(28%) patients had mild aching pain. No patients had moderate or severe pain.

Section-2 Range of Motion

Table 10: Range of Motion

Score	Range of motion	No. of cases	Percentage
20	Arc of motion greater than 100 degrees	22	88
15	Arc of motion between 50 and 100 degree	3	12
5	Arc of motion less than 50 degrees	-	-

In the present series 22(88%) patients were having Arc of motion greater than 100 degrees, 3(12%) patients were having Arc of motion between 50 and 100 degrees and no patients with Arc of motion less than 50 degrees.

Section-3 Stability

Table 11: Stability

Score	Stability	No. of cases	Percentage
10	Stable	23	92
5	Moderate instability	2	8
-	Grossly unstable	-	-

In the present series 23(92%) patients were having stable elbow, 2(8%) had moderate instability and no patient had gross instability.

Section-4 Functional Evaluation

Table 12: Functional Evaluation

Score	Function	No. of patients	Percentage
5	Can comb hair	22	88
5	Can eat	25	100
5	Can perform hygiene	25	100
5	Can don shirt	23	92
5	Can don shoe	25	100

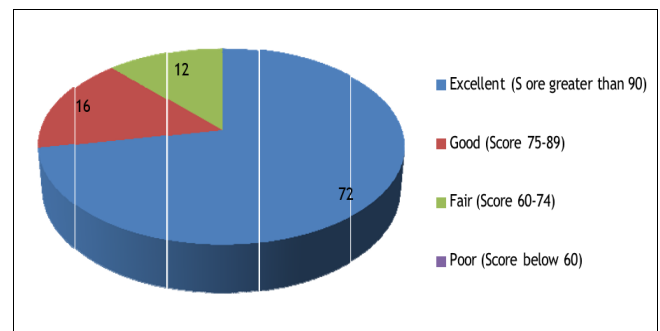
In the present series 22(88%) patients can comb hair, 25(100%) patients can eat, 25(100%) patients can perform hygiene, 23(92%) can don shirt, 25(100%) can don shoe.

Interpreting the Mayo elbow Performance Score

Table 13: Results

Grading	No. of Cases	Percentage
Excellent (Score greater than 90)	18	72
Good (Score 75-89)	4	16
Fair (Score 60-74)	3	12
Poor (Score below 60)	-	-

In the present series, the patients with excellent score were 18 (60%), 4 cases (16%) were with good results, fair results were noticed in 03 cases (28%). No cases were seen with poor results.



Graph 1: Interpreting the mayo elbow performance score

Complications or demerits of this procedure

Table 14: Complications

Complications	No. of Cases	Percentage
Superficial infection	3	12
Symptomatic metal prominence	4	16

The complications of the present study, superficial infection was in 3(12%) patients, which was treated with broad spectrum antibiotics. The symptomatic metal prominence was noticed in 4 (16%) patients.

Discussion

The main aim of the treatment of fracture is not only achieving union but to preserve the optimum function of the adjacent soft tissues and joints. In the management of intra articular fractures like fractures of the olecranon, a perfect anatomical reduction of the fragments to obtain articular congruity and rigid fixation of the fragments is of utmost importance, if early movements are to

be instituted to prevent complications like traumatic arthritis and joint stiffness. Tension band wiring with 2 intramedullary Kirschner wires provides the strength of fixation i.e. by converting tensile force to compressive force at the fracture site and for comminuted fractures Olecranon hook plate is used. In our study 25 cases of fractures of the olecranon were treated with Tension band wiring and Kirschner wires for simple transverse and oblique fractures and Olecranon hook plate for comminuted fractures. Our experience with this method of fixation has given favourable results. The findings, the end results and various other data will be analysed and compared in the following discussion.

1. Age Incidence

Table showing average age incidence in various study groups

Table 15: Demographics

Series	Average age
1) Jiang Xieyuan (2000) [7]	38 years
2) Macko Donald and Szabo (1985) [8]	35.5 years
3) Present study	40.05 years

The average age incidence; in the present study was found to be 40.05 years. This is well in accordance with the authors Jiang Xieyuan (2000) is his study average age was 38 years and Macko Donald and Szabo California (1985) average age was 35.5 years (15-76 years).

2. Sex Incidence

Table 16: Sex

Series	Male	Female
1) Jiang Xieyan (2000) [7]	10(66.66%)	5 (33.33%)
2) Hume &Wiss (1992) [9]	30(73.17%)	11(26.82%)
3) Wolfgang G. <i>et al.</i> (1987) [10]	27(60%)	18(40%)
4) Present study	17(68%)	8(32%)

The present study of fracture olecranon revealed greater incidence in males (68%). Similarly male predominance was found in the study of Jiang Xieyuan, Hume and Wiss and Garry Wolfgang *et al.* series.

3. Side Incidence

Table 17: Side

Series	Right	Left
1) Wolfgang G., <i>et al.</i> (1987) [10]	25(55.55%)	20 (44.44%)
2) Hume and Wiss (1992) [9]	16(39.2%)	25 (60.9%)
3) Present study	16(64%)	9(36%)

In this study the involvement of right side [16 patients (64%)] was seen more frequent than left side. But according to author Wolfgang G. *et al.*, study right side is more and according to author Hume and Wiss left is more.

4. Mechanism of Injury

Table 18: Mode of injury

Series	No.of cases	Percentage
1. Jiang Xieyuan (2000) [7]		
▪ Traffic accident	9	60%
▪ Fall from height	6	40%
2. Wolfgang G., <i>et al.</i> (1987) [10]		
▪ Fall	22	48.88%
▪ Motor vehicle accident	20	44.44%
▪ Direct blow	3	6.66%
3. Present study		
▪ Road traffic accident	13	52%
▪ Fall from height	11	44%
▪ Assault	1	4%

In this study, the patients with Road traffic accident were 13 (52%) patients, with Fall from height were 11 (44%) patients and 1(4%) patient was Assault. Where as according to Jiang Xieyuan series, the patients with traffic accidents were 9(60%) and patients with fall from height were 6 (40%) and according to Wolfgang *et al.*, 22 (48.88%) patients were fall from height 20(44.44%) were due to motor vehicle accident 3 (6.66%) were due to direct blow.

5. Type of Fracture

Table 19: Fracture type

Series	No. of cases	Percentage
1. Jiang Xieyuan (2000) [7]		
▪ Oblique fracture	1	6.67
▪ Comminuted fracture	14	93.34
2. Murphy <i>et al.</i> (1987) [11, 12]		
▪ Transverse fracture	26	57.5%
▪ Oblique fracture	12	26.7%
▪ Comminuted fracture	7	15.6%
3. Present study		
▪ Transverse fracture	14	56%
▪ Oblique fracture	6	24%
▪ Comminuted fracture	5	20%

In the present series 14 (56%) transverse fractures, 6 (24%) oblique fractures and 5 (20%) comminuted fractures. In Jiang Xieyuan study 1 (6.67%) oblique fractures and 14 (93.34%) comminuted fractures. In Murphy *et al.* series 26 (57.5%) transverse fracture 12 (26.7%) oblique fractures 7 (15.6%) comminuted fractures.

6. Postoperative complications or demerits of this procedure

Table 20: Complications

Complications	Present study	Murphy <i>et al.</i> [11]
1. Superficial infection	3 (12%)	-
2. Symptomatic metal prominence	4 (16%)	3 (6.6%)

In the present series superficial infection in 3(12%) patients, which was seen in diabetic patients probably due to decreased immunity which was treated with broad spectrum antibiotic. The symptomatic metal prominence in 4 (16%) where as complications in Murphy *et al.* 31 is only symptomatic metal prominence 3 (6.66%).

7. Results

Table 21: Results

Study	Results in percentage			
	Excellent	Good	Fair	Poor
1. Murphy <i>et al.</i> [11,12]	60	10	30	-
2. Jiang Xieyuan [7]	53.33	40	6.66	-
3. Present study	72	16	12	-

The results were evaluated according to the Mayo elbow performance score. The results obtained in our series were excellent in 18 (72%) patients, good in 4(16%) patients, fair in 3(12%) patients and no poor results.

The results in our series is almost accordance with the studies of Murphy *et al.* and Jiang Xieyuan.

Conclusion

From the present study it is concluded that the technique of open reduction and internal fixation with Kirschner wires and tension band wiring for simple transverse and oblique fractures and olecranon plate fixation for comminuted fractures are effective means and gold standard technique of treating fractures of olecranon and is based on sound biomechanical principle.

References

1. David Ring. Elbow fractures and dislocations in Rockwood and Green Fractures in Adults Chapter 32 Vol I 7th, Bucholz RW, Heckman JD, Lippincott Williams & Wilkins, 2010, 936-942.
2. Howard JL, Urist MR. Fracture dislocation of the radius and the ulna at the elbow joint. Clin Orthop. 1958; 12:276-284.
3. John R Willams. Coronoid, Radial head, Olecranon fractures and Elbow Dislocations' Chapter 3-35 Vol -3 in Oxford Text book of Orthopaedics and Trauma, 2002, 1969-1972.
4. Crenshaw Andrew H. Fractures of Shoulder, arm and forearm Chapter54, Campbell's Operative Orthopaedics, Vol 3, 11thEdn, Canale S Terry, James H. Beaty, 2008, 3411-3417.
5. Cooper Jerald L, D'Ambrosia Robert D. Fracture and Fracture Dislocation about the Elbow' Chapter 33 Operative Orthopaedics, Vol. I 2nd Edn. Chapman Michael W.,J.B. Lippincott Company, Philadelphia, 1993, 479-482.
6. Morrey BF, An KN. Functional evaluation of the elbow. In: Morrey BF, editor. The elbow and its disorders.3rded Philadelphia: WB Saunders, 2000, 82.
7. Jiang Xieyuan *et al.* Operative treatment of olecranon fracture associated with anterior dislocation of the elbow. Chinese J of Orthop. 2000; 20(3):154-156.
8. Macko D, Szabo RM. Complications of tension band wiring of olecranon fractures. J Bone Joint Surg, 1985, 57B:399.
9. Hume Mary C, Wiss Donald A. Olecranon fractures. Clin Orthop. 1992; 285:229-235.
10. Wolfgang G *et al.* Surgical treatment of displaced olecranon fractures by tension band wiring technique. Clin Orthop. 1987; 224:192-204.

11. Murphy DF *et al.* Displaced olecranon fractures in adults. Biomechanical analysis of fixation methods. Clin Orthop. 1987; 224:210-4.
12. Murphy DF, Greene WB, Damerson TB. Displaced olecranon fractures in adults. Clinical evaluation. Clin Orthop. 1987; 224:215-23.