



ISSN (P): 2521-3466
ISSN (E): 2521-3474
© Clinical Orthopaedics
www.orthoresearchjournal.com
2019; 3(1): 10-16
Received: 06-02-2019
Accepted: 09-03-2019

Dr. Prabhulingreddy Patil
Assistant Professor, Department
of Orthopaedics, Sri Devaraj Urs
Medical College, Tamaka, Kolar,
Karnataka, India

Dr. Eswara Reddy G
Assistant Professor, Department
of Orthopaedics, Sri Devaraj Urs
Medical College, Tamaka, Kolar,
Karnataka, India

Dr. Manoj Kumar R
Senior Resident, Department of
Orthopaedics, Sri Devaraj Urs
Medical College, Tamaka, Kolar,
Karnataka, India

Dr. Ravishankar J
Assistant Professor, Sri
Siddhartha Medical College
Tumkur, Karnataka, India

Correspondence

Dr. Eswara Reddy G
Assistant Professor, Department
of Orthopaedics, Sri Devaraj Urs
Medical College, Tamaka, Kolar,
Karnataka, India

A prospective study to evaluate the clinical and functional outcome of uncemented total hip replacement in avascular necrosis of femoral head in adults

Dr. Prabhulingreddy Patil, Dr. Eswara Reddy G, Dr. Manoj Kumar R and Dr. Ravishankar J

DOI: <https://doi.org/10.33545/orthor.2019.v3.i2a.03>

Abstract

Background: Osteonecrosis, also referred to as avascular necrosis (AVN), aseptic necrosis, and ischemic necrosis, is not a specific disease but rather a condition in which a circumscribed area of bone becomes necrotic as a result of a loss of its blood supply. The femoral head is the site most often affected. A number of procedures have been described to accomplish this. Total hip replacement is a reconstructive surgical procedure that provides stability, better quality of life and mobility in patients suffering from hip disorders thus eliminates pain and restore functions of hip. In hip arthroplasty, the acetabulum, femoral head and proximal neck is replaced with metal shell, plastic liner and metal ball.

Purpose: To evaluate the clinical, functional, radiological outcome and the complications of uncemented total hip replacement in avascular necrosis of femoral head in adults.

Materials and Methods: This prospective study done in the Department of Orthopaedics, Post Graduate Institute of Swasthiyog Prathistan, Miraj, from February 2013 to February 2014. We included the patients of avascular necrosis of femoral head, in the age group of 30 to 60 years.

Results: 36 hips of 30 patients with avascular necrosis of femur head who underwent uncemented Total Hip Replacement admitted during above period after evaluating clinically and radiologically Harris Hip Score was used to measure the functional outcome. 36.11 % of the patients were found to be in the 50 and above age group, with age ranging from 30 to 60 years and a mean age of 43.8 years. Majority, 27 (75%) were males and 9 (25%) were females. Excellent or good pain relieved and function were obtained in 86.01%. The mean total preoperative score was 34.61, which improved postoperatively to a mean score of 90.83. In the scoring system ie, pain, gait, functional activity and ROM, there was a statistically significant improvement ('p' value of <0.001) in the postoperative score when compared to preoperative score.

Conclusion: The outcome of uncemented total hip replacement done in cases of avascular necrosis of femoral head most of them who are in stage 3 and 4 of Ficat and Arlet classification in adults is determined by multiple factors, including the design of the component, the selection of the patients, and the operative technique.

Keywords: Avascular necrosis, femoral head, uncemented, hip arthroplasty

Introduction

Avascular necrosis (also osteonecrosis, bone infarction, aseptic necrosis, ischemic bone necrosis and AVN) is a disease where there is cellular death (necrosis) of bone components due to interruption of the blood supply, without blood the bone tissue dies and the bone collapses. If avascular necrosis involves the bones of a joint, it often leads to destruction of the joint articular surfaces^[1]. While it can affect any bone and half of cases show multiple sites of damage, avascular necrosis primarily affects the joints at the hip knee and shoulder. The classical sites are head of femur, neck of talus and waist of scaphoid^[2].

Clinical avascular necrosis most commonly affects the ends (epiphysis) of long bones such as the femur. Other common sites include the humerus, knees, shoulders, ankles and the jaw. Avascular necrosis usually affect people between 30 and 50 years of age^[3].

Total hip replacement arthroplasty is a surgical procedure, which has relieved millions of people from incapacitating pain arising from the hip joint at present it is the most commonly performed adult re-constructive hip procedure [4]. The field of total joint replacement is in an evolutionary state. The first total hip replacement is thought to have been done in London by Philip Wiles in 1938 [5]. The procedure was further developed in the 1950s by pioneers such as McKee and Farrar [6]. This early work laid the groundwork for the innovative studies of Sir John Charnley who in the late 1960s, approached the problem of artificial hip joint design by using the biomechanical principles of human hip joint function [7, 8]. Improvements in implant design materials and fixation techniques continued but Charnley's basic concept continues to be valid.

Non cemented total hip arthroplasty was developed in response to evidence that cement debris plays an important role in promoting bone lysis and loosening. Prosthetic devices have been developed that achieve fixation without cement, either by "press-fit" or by biologic ingrowth. With the press-fit technique, stabilization is achieved by interference fit of the implant into the femur with biologic ingrowth. Fixation occurs by bone ingrowth into a porous surface, noncemented devices are most frequently used in young patients with high physical demands. Compared with cemented hip arthroplasties, however, patients have a higher incidence of low-grade temporary thigh pain. Although short-term results appear to be less satisfactory compared with cemented hip arthroplasty, after 5 to 20 years, the results in the two procedures are similar [7]. The Harris hip score is the most widely used scoring system for evaluating hip arthroplasty [8]. The purpose of the study is to assess the clinical, functional as well as radiological assessment and related complications in uncemented total hip arthroplasty in cases of avascular necrosis of femoral head in adults.

Objectives of study

1. To study, the functional outcome of patient based on modified Harris hip score in terms of pain, functional disabilities and deformity, range of motion, limb length discrepancy
2. To study the radiological outcome with respect to functional outcome.
3. To evaluate the complications with respect to radiological and functional outcomes.
4. To evaluate the functional and radiological outcome with respect to stage of the avascular necrosis of femoral head.

Material and methods

The study was carried out on 36 hips of 30 patients who were diagnosed clinically and radiographically as avascular necrosis of femoral head and operated with Total Hip Replacement in the Department of Orthopaedics, Post Graduate Institute of Swasthityog Prasthan, Miraj, from February 2013 to February 2014. This was a prospective study. Patient follow up was for a minimum of 6 weeks to a maximum of 12 months (1 year). We included the patients of avascular necrosis of femoral head, in the age group of 30 to 60 years who are willing to give informed consent. Excluded those whose age less than 30 years, with any systemic and local infections and who are not medically fit for surgery.

Pre-Operative detailed history and proper clinical examination was taken. Duration of illness, focus of infection in the body, sensory motor examination, vascularity of limb, ambulatory status of the patient, and deformities of the hip, ROM of the hip and status of the other joints. The deformity and ROM were

measured with goniometer. All the patients were assessed using Modified Harris Hip Score.

Radiological assessment: The Pelvis with both hips with proximal half of shaft of femur AP view was taken for all patients. The radiograph was evaluated for staging of avascular necrosis of femoral head using Ficat Arlet classification

Stage 0: Normal

Stage 1: Normal

Stage 2: Density change in femoral head

2A: Sclerosis or cysts, normal joint line, normal head counter

2B: Flattening (Crescent sign)

Stage 3: Loss of sphericity, collapse of femoral head

Stage 4: Joint space narrowing, acetabular changes

Templating was done for the acetabular and femur components. The appropriate acetabular cup size, and anteversion was determined. On the femoral side, using a template, appropriate neck length, offset and stem size of the implant is chosen.

Surgical Technique: In our study we have used the posterolateral approach for to do the uncemented total hip replacement. The hip joint was approached by splitting the gluteus maximus and incising the short external rotators by keeping it under tension by flexing the knee and rotating it externally. The sciatic nerve was protected with the help of the external rotators. Acetabular cup sizes used were one size higher than the last reamer used. In five patients we have used screws to fix the acetabular cup along the posterosuperior quadrant keeping in mind centre of the offset placed superiorly or posterosuperiorly. The acetabular cup placed was covered with a mop to protect it from any debris. The proximal femur was exposed and delivered out by markedly internal rotating the limb. The femoral canal was hand reamed to the anticipated stem size as determined by templating and maintaining the anteversion. On introducing the femoral stem, the stability was tested to rotational and extraction forces and care was taken not to fracture the proximal femur. The prosthetic head of the appropriate size was placed on the trunion and affixed with mallet over a plastic capped head impactor. A wash is given and any remaining debris removed. The femoral head was reduced and the stability confirmed through a functional range of motion wound was closed over a suction drain. (Fig 1).

Postoperative Protocol: The hip is positioned in approximately 15 degrees of abduction while the patient is recovering from the anaesthetic using a triangular pillow to maintain abduction and prevent extremes of flexion. First post op day, check X-rays are taken. The patient is taught static quadriceps exercises, knee and ankle mobilization exercised and made to sit. Second post op day dressing changed and smaller dressing is applied. Gait training was started using a walker with weight bearing to tolerance. Drains were removed 24 to 48 hours after surgery. IV antibiotics were given for 48 hr later switched over to oral antibiotics for further 5 days more. DVT prophylaxis was given in the form of low molecular weight heparin/heparin for first five days after surgery. 12th Post op day sutures are removed and discharged from the hospital to be reviewed after one month. They were advised not to squat, not to sit cross legged, not to use Indian toilets and not to cross the lower limb across the midline. The patients were followed up at 6 weeks, 3 month, 6 month intervals.

Clinical Assessment: During each visit the deformity and ROM were measured with goniometer. The clinical and functional outcomes were evaluated by Modified Harris Hip Score. Based

on a total of 100 points possible, each question is awarded a certain number of points. Questions are further grouped into categories. No pain in the hip is awarded 44 points, slight pain 40 points, down to 0 points for disabling pain. If there is no limp, do not use a walking aid, and can walk more than six blocks, 33 points were awarded less if the patient was to use a cane, or walk only two blocks, etc. Functional activities, consists of questions about how the patient climb stairs, put on shoes, length of time you can sit in a chair, and if the patient can use public transportation. Finally, the physical exam results are tabulated, and based on the absence of deformity and range of motion; up to 9 points were awarded. The score is reported as 90-100 for excellent results, 80-90 being good, 70-79 fair, 60-69 poor, and below 60 a failed result. Based on this reasoning a point scale with a maximum of 100 points is used with the following maximum possible scores: Pain 44, Function 47, Range of Motion 5, Absence of deformity 4, Total 100.

Radiological Assessment: A radiograph was taken at the end of the procedure and during follow up visits. (Fig 2) The standard radiograph was an anteroposterior view of Pelvis including both hips and sufficient length of Femur. The radiological assessment included positioning and alignment of the acetabular and Femoral components and complications such as periprosthetic fractures, loosening, osteolysis, dislocation, subsidence and

heterotrophic ossification. Cups without radiolucent Lines or migration on the radiographs that were made at the time or the last follow-up were considered to be well fixed. Cups with a circumferential radiolucent line of <1 mm in width and without migration were considered to have a stable fibrous union. Cups with progressive radiolucent lines and those exhibiting migration were considered to be loose. Radiographic osteolysis was defined as so-called punched-out areas devoid of trabecular bone, usually with a sclerotic border. Periacetabular osteolytic lesions were assessed according to the zones described by DeLee and Charnley and the femoral osteolytic lesions were assessed according to the zones described by Gruen.

Method of Statistical Analysis: Appropriate statistical analysis was applied for comparing the incidences of adverse events and other complications. Additional exploratory (parametric as well as non-parametric) analysis of the data was performed as deemed essential by using appropriate statistical tests. The following methods of statistical analysis have been used in this study. The Excel and SPSS software packages were used for data entry and analysis. The results were averaged (mean + standard deviation) for each parameter for continuous data and numbers and percentage for categorical data presented in Table and Figure.

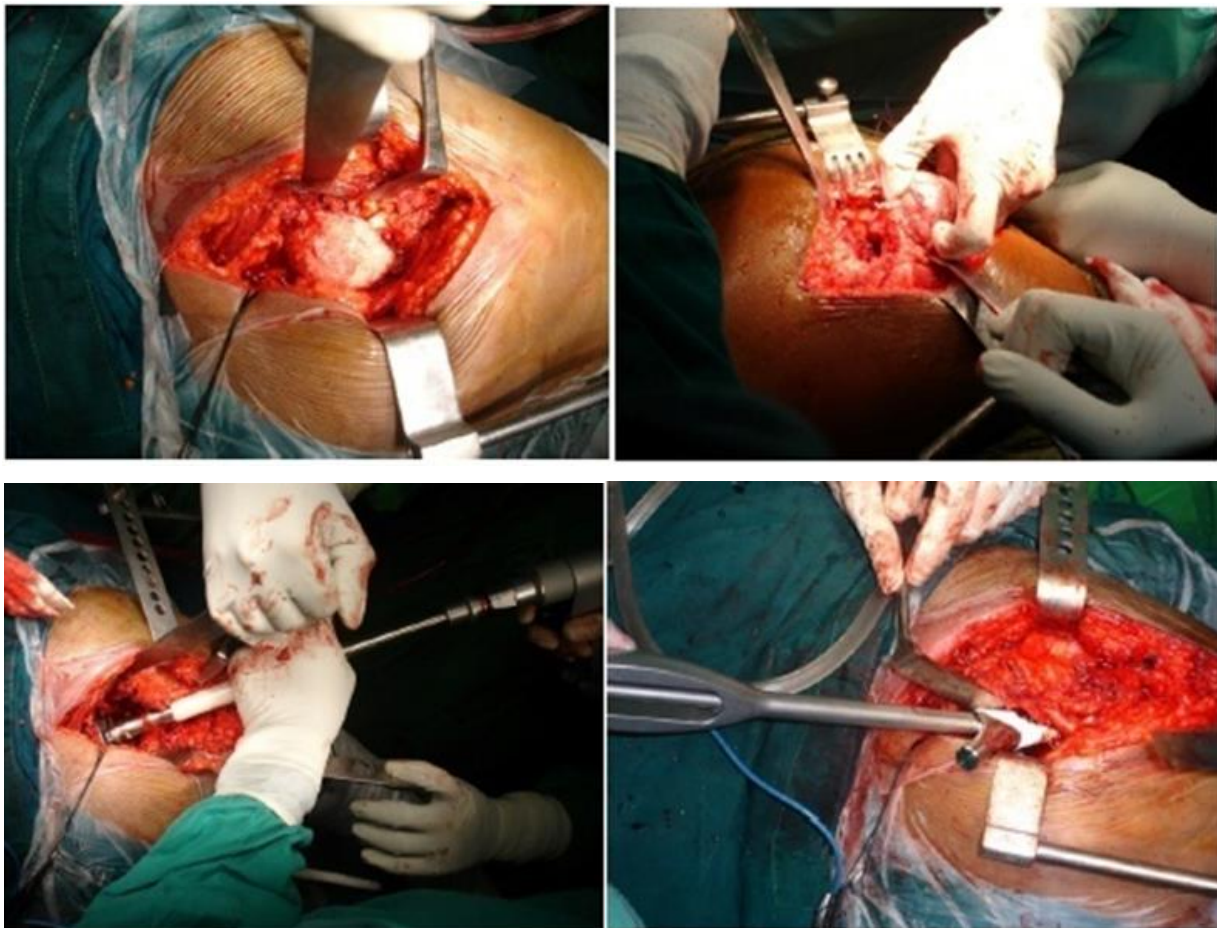


Fig 1: Operative procedure of Total Hip Replacement

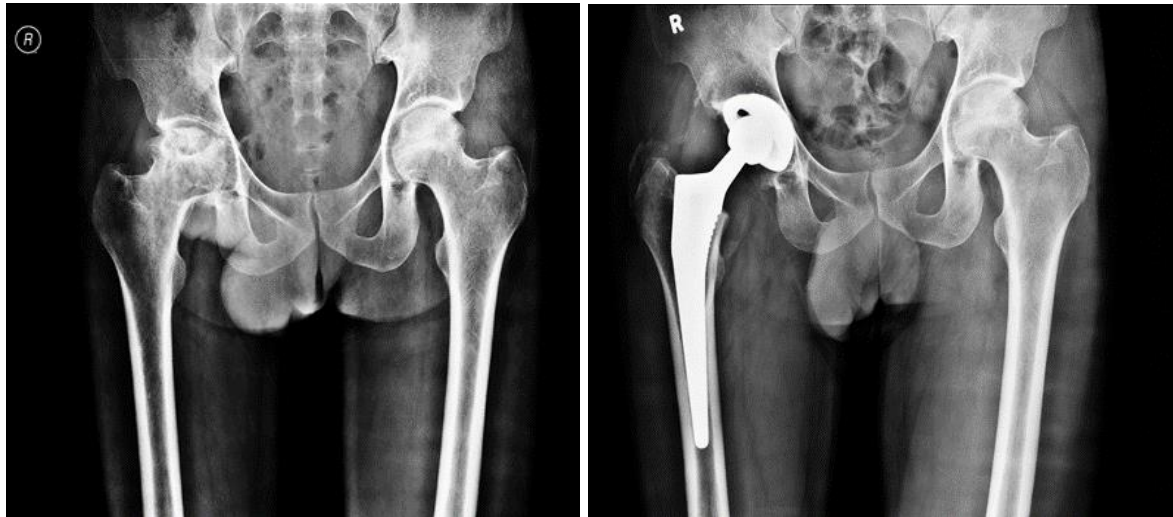

Fig 2: Pre op and post op x-ray

Results

The study was carried out on 36 hips of 30 patients who underwent uncemented Total Hip Replacement. In all the patients, posterolateral approach was used. Intraoperatively, for two patients we came across increased vascularity, due to previous surgery on the same hip. Haemostasis was achieved. Bone grafting was done in one Patient with acetabular cyst and in 2 patients the acetabular cup was fixed with 1 acetabular screw and 3 patients the acetabular cup was fixed with 2 acetabular screws each. Two patient developed foot drop in the immediate postoperative period one patient recovered within 3 weeks and other failed to recover even after 8 months.

Age distribution: This study was conducted on patients with age ranging from 30 to 60 years with a mean age of 43.8 years and standard deviation of 8.605.

Table 1: Showing age distribution of all patients

Age	Frequency	Percent
30-39 Yrs	8	22.22%
40-49Yrs	15	41.67%
50-60Yrs	13	36.11%
Total	36	100.00%

Gender Distribution: In this study, 23 were males among which 4 were operated bilateral and 7 were females among which 2 were operated bilaterally. Side Affected: 6 patients underwent bilateral total hip replacement and 24 patients underwent unilateral total hip replacement. Total hip replacement was done 16 on the left side and 20 on the right side.

Table 2: Showing distribution and percentage of patients based on Ficat and Arlet stage of disease

Stage	Frequency	Percent
3	19	52.78%
4	17	47.22%
Total	36	100.00%

Prosthesis: DePuy company. Femoral stem: We used the De Puy Corail stem. Stem size: The maximum stem size used was 12 and minimum was 8. In this study, stem size 11 was most frequently used (44.40%), followed by stem size 12(30.60%).

Table 3: Stem size

Stem_size	Frequency	Percent
8	2	5.60%
9	4	11.10%
10	3	8.30%
11	16	44.40%
12	11	30.60%
Total	36	100.00%

Femoral Head: In patients we used head size 28 +1.5 head offset was used more frequently and in one case we used head size of 40.

Acetabular Component: DePuy Duraloc Shell. The maximum shell size used was 58 and minimum was 48. Shell size 52(30.55%) was the most commonly used and size 48(19.44%) was the least commonly used. Liner: The liner size used

corresponded to the size of the shell.

Follow up: The minimum patient follow-up for the study was 6 weeks and the maximum was more than 6 months (up to 12 months). 30 patients were followed up during the period of 12 weeks to 6 months. 4 patients between 6 to 12 weeks and 2 were within 6 weeks.

Table 4: Preoperative and postoperative scores according to the various parameters of the Modified Harris hip Score System

	Mean	Std. Deviation	Minimum	Maximum	Std. Error Mean	Paired t value	p value
Pain pre	12.22	4.847	10	30	0.808	-24.14	0.000
Pain post	40.39	5.426	30	44	0.904		
functional gait pre	11.17	6.818	0	30	1.136	-13.95	0.000
functional gait post	29.33	3.216	21	33	0.536		
functional activity pre	5	2.586	0	10	0.431	-17.21	0.000
functional activity post	12.67	1.434	10	14	0.239		
absence of deformity pre	3.78	0.929	0	4	0.155	-1.435	0.160
absence of deformity post	4	0	4	4	0		
range of motion pre	1.89	1.326	0	4	0.221	-12.16	0.000
range of motion post	4.83	0.378	4	5	0.063		
Modified Harris Hip Score pre	34.61	11.665	18	75	1.944	-24.96	0.000
Modified Harris Hip Score post	90.83	7.633	71	99	1.272		

*p' value of less than 0.05 indicates statistical significance.

For the total score and each of the parameters, higher score implies lesser disability. The mean total preoperative score was 34.61. The maximum score being 74 and the minimum being 17. Postoperatively the total mean score was 90.83, with 72 being the minimum and 97 being the maximum. with regards to the different parameters In the scoring system ie, pain, gait, functional activity and ROM, there was a statistically significant improvement ('p' value of <0.001) in the postoperative score when compared to preoperative score. But no statistically significant difference in score was found in the parameter absence of deformity, Post operatively, implying that most of the patients did not have any severe deformities preoperatively.

Table 5: Comparison of the preoperative versus postoperative scores according to the grading

Grade	Pre	Percentage	Post	Percentage
Poor	33	91.67%	0	0.00%
Fair	2	5.56%	5	13.89%
Good	1	2.78%	5	13.89%
Excellent	0	0.00%	26	72.22%
Total	36	100.00%	36	100.00%

The score is reported as 90-100 for excellent results, 80-90 being good, 70-79 fair, 60- 69 poor, and below 60 for a failed result. Pre operatively 91.67% had a poor score. The results showed a significant improvement, wherein 72.22% had an excellent score and 13.88% showed good and fair results each. No patient had a poor score. Postoperative Limb Length Discrepancy: 2 patients (5.55%) had 1cm limb lengthening and 1 patients (2.77%) with 1.5cm lengthening. Postoperative Acetabular Cup Angle: In 47.22% of the patients the acetabular cup angle was 40°. The average acetabular angle was 45.08°±5.118. Final Outcome According to age: In the age group of patients 30-39 years (of the study group), all of these patients had excellent postoperative outcome scores. In the patients 40-49 years, 66.66% had excellent outcome scores and 20.00% had good and 13.33% had fair outcome scores. In the patients 50-59 years, 61.53% had excellent outcome, 15.38% had good outcome and 23.07% had fair outcome. There was no statistically significance between the stage of disease and final outcome. 2 patients with acetabular angle <50 degree had fair postoperative outcome scores and 9 had excellent score where as in the >50 degree group, 1 had fair, 3 had good and 6 had excellent Scores. There is no statistically significant association of outcome with Acetabular angle. In 13.89% of the patients the femoral stem was in varus position and in 86.11% it was placed centrally. No significant association was found between outcome and femoral component placement. Out of the 3 patients who had fair outcome score 2 patients had

centrally placed femoral stem and 1 was placed in varus.

Complications: The most common complication noted was anterior thigh pain (13.89%). Nerve injury were seen in 2 individual patients. Patients (63.89%) did not have any complications.

Table 6: Shows the frequency of various complications seen in the study

Complications	Frequency	Percent
Nerve injury	2	5.56%
Superficial Infection	2	5.56%
Periprosthetic Fracture	0	0.00%
Anterior thigh pain	5	13.89%
Stress Shielding	3	8.33%
Dislocation	1	2.78%
No Complication	23	63.89%
Total	36	100.00%

Complications versus Outcome Score: 26% of the patients who had single or multiple complications showed good to excellent results. Only patient with dislocation showed fair result.

Femoral Component Placement versus Complications: Out of the 5 patients with varus positioning of the stem, 1 patient had stress shielding and 1 patient had anterior thigh pain. Stress shielding and dislocation were also seen in the patient with anterior thigh pain with central stem. 2 patients with stress shielding, 4 patients with anterior thigh pain had centrally placed stems. three patient out of the five with varus stem did not have any complications while 20 out of 31 with central stem had no complications. Anterior thigh pain occurred in only 13.89% of the patients (5 patients) in the present study, which disappeared after few months. Out of these five patients, 3 had size 11 stem and 2 had size 12. Stress shielding was noted in 3 (8.33%) of the patients and 2(66.66%) of them were above the age of 40. All the patients had good to excellent outcome score. 33.33% of the patients with varus stem and 5.71% with central stem had stress shielding. There was no statistical data to prove any association of stress shielding to placement of the stem. There is no statistically significant association between stress shielding and femoral Component Placement.

Discussion

Total hip arthroplasty is a well-documented surgical procedure which relieves pain and functional disability, improving the quality of life [9]. The study was carried out on 36 hips of 30

patients who underwent uncemented Total Hip Replacement. In western literature, as per Harkess, Charnley, Eftekhari total hip arthroplasty has primarily been described for patients in older age group of sixty and above^[8]. In our study, 36.11 % of the patients were found to be in the 50 and above age group, with age ranging from 30 to 60 years and a mean age of 43.8 years. Majority, 27 (75%) were males and 9 (25%) were females. We used modified Harris hip score to assess the functional outcome in our study. Avascular necrosis of femoral head is one of the indications for THR surgery. Our study included new generation prosthesis that demonstrated improved clinical and radiological outcomes compared with those associated with early designs of prostheses inserted without cement. Excellent or good pain relief and function were obtained in 86.01% which was performed in patients suffering from avascular necrosis of femoral head. The mean total preoperative score was 34.61, which improved postoperatively to a mean score of 90.83. Bourne *et al.*^[10], in a study of 101 total hip replacements with the PCA (porous-coated anatomic) prosthesis (Howmedica, Rutherford, New Jersey), reported an average Harris hip score of 96 points, but only patients who were free of pain were evaluated. When patients who had pain were included, the overall average score was 90 points. In a study by Katz *et al.*^[11] the results of 14 arthroplasties, in which the stem had been fixed without cement, the hip score averaged 84 points at forty-six months. Barrack and Lebar^[12] reported an average Harris hip score of 93 points after 49 arthroplasties in which the LSF (long-stem stable fixation) prosthesis (OTI [Osteoimplant Technology International], Hunt Valley, Maryland) had been used. In our study, patients in the age group 30-39 years, (22.22% of the study group), all had excellent postoperative outcome scores. In the 40 – 49 year age group, 66.66% had excellent and 20% had a good and 13.33% had fair result. Another factor that may be of importance in determining the outcome of arthroplasties without cement is the stage of disease. In our study the patients belonged to stage 3 and 4 of Ficat and Arlet radiographic classification of avascular necrosis of femoral head and we found that there was no statistical significance between these two stages and final outcome. Bourne *et al.*^[10] who studied the outcomes of total hip replacement with insertion of PCA prosthesis without cement in patients who had advanced osteoarthritis, reported pain in the thigh five years after 27 percent (twenty-seven) of 101 arthroplasties and more than 2 millimetres or subsidence of the femoral component in twenty-five hips. In our study we did not have any cases or subsidence of the implant. Anterior thigh pain occurred in only 13.89% of the patients (5 patients) in the present study, which disappeared after few months. Out of the five patients, three had size 11 stem and two had size 12. DePuy corail stem was used in all five. Our study detected no association between pain in the thigh and position of the stem which shows similar results as seen in a study by Matthew J. Kraay, Victor M. Goldberg, *et al.*^[13], pain in the thigh occurred after only 5 percent (five) of the total hip arthroplasties and detected no association between pain in the thigh and the size of the stem. Callaghan *et al.*^[14] reported that eight of forty-six patients (forty-nine hips) had pain in the thigh at two years after an arthroplasty with the use of the PCA stem. Heekin *et al.*^[15] reported pain in the thigh in association with 15 percent of ninety-one hips at five years in a study of a similar population. Extensive Pedestal formation is considered another potential radiographic sign of instability of the implant. In the present study this was not seen in any of the cases. However, our follow-up may have been too short to develop complications like osteolysis. In contrast, Campbell *et al.* reported that 28 percent

(twenty-eight) of 110 stems had notable subsidence at two years, and Barrack and Lebar^[12] found that 6 Percent (three) of forty-nine stems had subsided at least three to four millimetres. Studies with longer follow-up have demonstrated a notably higher prevalence of femoral osteolysis. In our study during the procedure, we did not have any periprosthetic fractures. Dislocation was noticed in one of patient immediate post operatively whose acetabular cup size was 58. The posterior dislocation was treated by closed reduction and immobilization for 3 weeks. The patient had fair outcome. Stress shielding was noted in 8.33% of the Patients and 66.66% of them were above the age of 40. All the patients had good to excellent outcome score. There was no statistical data to prove any association of stress shielding to placement of the stem. In another study stress-shielding is common in patients who are sixty-five years of age or older, and it can be pronounced. However, these reactive changes did not adversely affect the clinical outcome or radiographic stability or predispose the distal aspect of the femur to osteolysis in our series. Konyves and Bannister^[16] noted that lengthened limbs were also associated with lower clinical hip scores. Limb-length discrepancy can result from a poor preoperative patient evaluation as well as intraoperative technical errors with regard to the level of resection of the femoral neck, the prosthetic neck length, or the failure to restore offset. In our study 2 patients had lengthening of less than 1.5 cm and both of them had excellent outcome and 1(33.33%) had fair results.

Conclusion

In conclusion, the outcome of total hip arthroplasty done in cases of avascular necrosis of femoral head most of them who are in stage 3 and 4 of Ficat and Arlet classification in adults without cement is determined by multiple factors, including the design of the component, the selection of the patients, and the operative technique. The results of the procedure must be evaluated in long-term studies. Our study suggests that the current generation implants without cement can provide satisfactory clinical and radiographic outcomes after an intermediate duration of follow-up. Though the study was not free of complications, the overall functional and clinical outcome showed good results. Further long term follow up is required for evaluating the long term complication which is one of the draw back of the study.

Declaration of patient consent

We obtained the consent from the patients who are all included in this study. They understand that their names and initials will not disclose.

Financial support and sponsorship: Nil

Conflicts of interest: There are no conflicts of interest

References

1. Mont MA, Jones LC, Hungerford DS. Nontraumatic osteonecrosis of the femoral head: ten years later. The Journal of bone and joint surgery American volume. 2006; 88(5):1117-32.
2. ME S. Diagnostic imaging and role of stage and lesion size in determining outcome in osteonecrosis of then femoral head. Techniques in Orthopedics. 2001; (16):6-15.
3. Khanuja HSMM, Etienne G, Hungerford DS. Treatment algorithm for osteonecrosis of the hip. Techniques in Orthopedics. 2001; (16):80-9.

4. McKee GK, Watson-Farrar J. Replacement of arthritic hips by the McKee-Farrar prosthesis. *The Journal of bone and joint surgery British volume*. 1966; 48(2):245-59.
5. Charnley J. Total hip replacement. *Jama: the journal of the American Medical Association*. 1974; 230(7):1025-8.
6. Charnley J. *Low friction arthroplasty of the hip: theory and practice*: Springer-Verlag, 1979.
7. Russotti GM, Coventry MB, Stauffer RN. Cemented total hip arthroplasty with contemporary techniques. A five-year minimum follow-up study. *Clinical orthopaedics and related research*. 1988; (235):141-7.
8. Cook SD, McCluskey LC, Martin PC, Haddad RJ Jr. Inflammatory response in retrieved noncemented porous-coated implants. *Clinical orthopaedics and related research*. 1991; (264):209-22.
9. EN S. *Surgery of the Musculoskeletal system* Evarts C, editor: Churchill Livingstone, 1983.
10. Bourne RB, Rorabeck CH, Ghazal ME, Lee MH. Pain in the thigh following total hip replacement with a porous-coated anatomic prosthesis for osteoarthritis. A five-year follow-up study. *The Journal of bone and joint surgery American volume*. 1994; 76(10):1464-70.
11. Katz RL, Bourne RB, Rorabeck CH, McGee H. Total hip arthroplasty in patients with avascular necrosis of the hip. Follow-up observations on cementless and cemented operations. *Clinical Orthopaedics and Related Research*. 1992; (281):145-51.
12. Barrack RL, Lebar RD. Clinical and radiographic analysis of the uncemented LSF total hip arthroplasty. *The Journal of arthroplasty*. 1992; 7:353-63.
13. Ragab AA, Kraay MJ, Goldberg VM. Clinical and radiographic outcomes of total hip arthroplasty with insertion of an anatomically designed femoral component without cement for the treatment of primary osteoarthritis. A study with a minimum of six years of follow-up. *The Journal of bone and joint surgery American volume*. 1999; 81(2):210-8.
14. Callaghan JJ, Dysart SH, Savory CG. The uncemented porous-coated anatomic total hip prosthesis. Two-year results of a prospective consecutive series. *The Journal of bone and joint surgery American volume*. 1988; 70(3):337-4641.
15. Meek RM, Garbuz DS, Masri BA, Greidanus NV, Duncan CP. Intraoperative fracture of the femur in revision total hip arthroplasty with a diaphyseal fitting stem. *The Journal of bone and joint surgery American volume*. 2004; 86-A(3):480-5.
16. Heekin RD, Callaghan JJ, Hopkinson WJ, Savory CG, Xenos JS. The porous-coated anatomic total hip prosthesis, inserted without cement. Results after five to seven years in a prospective study. *The Journal of bone and joint surgery American volume*. 1993; 75(1):77-91.
17. Konyves A, Bannister GC. The importance of leg length discrepancy after total hip arthroplasty. *The Journal of bone and joint surgery British volume*. 2005; 87(2):155-7.