



ISSN (P): 2521-3466
ISSN (E): 2521-3474
© Clinical Orthopaedics
www.orthoresearchjournal.com
2019; 3(1): 122-124
Received: 06-11-2018
Accepted: 09-12-2018

Dr. Mohit Bansal
Senior Resident, Department of
Orthopaedics Government
Medical College Amritsar,
Punjab, India

Dr. Maninder Singh
Assistant Professor
Department of Orthopaedics
Government Medical College
Amritsar, Punjab, India

Comparative evaluation of efficacy of PFN and PFN anti-rotation in treating patients with femur fracture

Dr. Mohit Bansal and Dr. Maninder Singh

DOI: <https://doi.org/10.33545/orthor.2019.v3.i1c.23>

Abstract

Background: Intertrochanteric fractures are defined as fractures of proximal part of femur located between lesser and greater trochanter. We planned the present study to assess the efficacy of PFN and single PFN anti-rotation in treating patients with intertrochanteric fractures of femur.

Materials & methods: The present included assessment of 20 cases of intertrochanteric fractures of skeletally mature adults, out of which, ten each were operated upon with PFN and PFN anti-rotation and were followed up for 6 months postoperatively. Surgical procedure was carried out in all the patients, as per their group, under the hands of skilled and experienced orthopedic surgeons. Clinical and radiographic outcome in all the patients was assessed. Harris hip score was used for assessing the functional outcome as per criteria described previously in the literature.

Results: We didn't observed any significant difference while comparing the mean time to sit, mean time to stand and mean time to walk among subjects of the double screw group and the helical screw group (P-value > 0.05). We didn't observe any significant results while comparing the mean HHS among patients of both the study groups at different time intervals.

Conclusion: In treating intertrochanteric fractures of femur, both the treatment protocols could be used with equal efficacy.

Keywords: Proximal femur nail, Harris hip score

Introduction

Hip fractures or fractures of proximal femur are one of the most frequent and appalling fractures affecting the elderly population with 90% occurring in >60 years age group. Intertrochanteric fractures are defined as fractures of proximal part of femur located between lesser and greater trochanter. Population of senior citizens is increasing as longevity increases day by day^[1-3]

Before the introduction of suitable fixation devices, treatment of intertrochanteric fractures of femur was non operative and consisted of prolonged bed rest with traction until fracture healing occurred followed by a lengthy programme of ambulation training.⁴ Keeping in mind the higher age of patients who suffer from intertrochanteric fractures and most of these patients also have osteoporosis it was proposed to use a comparatively recent modification of this screw proximal femur nail (PFN) which has a helical blade (in place of two screws) and is supposed to give better hold in osteoporotic neck of femur.⁵⁻⁷ Hence; we planned the present study to assess the efficacy of PFN and single PFN anti-rotation in treating patients with intertrochanteric fractures of femur.

Materials & methods

The present study was conducted in the department of orthopedics of the medical institute and it included assessment of 20 cases of intertrochanteric fractures of skeletally mature adults, out of which, ten each were operated upon with PFN and PFN anti-rotation and were followed up for 6 months postoperatively. Complete demographic and clinical details of all the patterns were obtained. Complete biochemical and hematological investigations were carried out in all the patients. Ethical approval was obtained from institutional ethical committee and written consent was obtained after explaining in detail the entire research protocol. Surgical procedure was carried out in all the patients, as per their group, under the hands of skilled and experienced orthopedic surgeons.

Correspondence
Dr. Maninder Singh
Assistant Professor
Department of Orthopaedics
Government Medical College
Amritsar, Punjab, India

Clinical and radiographic outcome in all the patients was assessed. Harris hip score was used for assessing the functional outcome was assessed as per criteria described previously in the literature [8]. All the results were analyzed by SPSS software. Chi-square test was used for assessment of level of significance.

Results

The present study included assessment and comparison of efficacy of PFN and PFN anti-rotation in patients undergoing treatment for intertrochanteric fractures of femur. Mean age of the patients of the PFN and PFN anti-rotation group was 63.58 and 62.15 years respectively. Majority of the patients belonged to the age group of more than 60 years. 60 percent of the patients of the PFN group were females while 50 percent of the patients of the PFN anti-rotation group were females. Domestic fall was the most common etiologic factor of injury in the present study. Mean time to sit among subjects of the PFN group was 2.9 days while it was 2.7 days among the subjects of the PFN anti-rotation respectively. We didn't observed any significant difference while comparing the mean time to sit, mean time to stand and mean time to walk among subjects of the double screw group and the helical screw group (P-value > 0.05). We didn't observe any significant results while comparing the mean HHS among patients of both the study groups at different time intervals.

Discussion

In the present study, mean age of the patients of the PFN and PFN anti-rotation group was 63.58 and 62.15 years respectively. Gadegone WM *et al* evaluated the results of augmented PFN in terms of prevention of postoperative complications and failure rates in unstable trochanteric fractures. They carried out a prospective study of 82 cases with unstable trochanteric femoral fractures from April 2010 to December 2015. Forty-two females and 40 males in the age group between 58 and 81 years were included in this study. There were 45 cases of AO 31 A2 (2.2, 2.3) and 37 cases of AO 31 A3 (3.1, 3.2, 3.3). Fractures were fixed by PFN with augmentation by an additional screw from trochanter to inferior quadrant of femoral head or cerclage wire to strengthen the lateral trochanteric wall. The bone healing is observed in all the cases in the mean period of 14.2 weeks. Nine patients developed complications, including lateral migration of neck screws (n = 5), Z effect (n = 1), infection (n = 2), and breakage of distal interlocking bolt in one case. Removal of screws was required in five cases. Patients were followed up for a mean of 8.4 months. At the end of follow-up the Salvati and Wilson hip function was 32 (out of 40) in 88% of patients. The stabilization of lateral trochanteric wall with additional screw or cerclage wire increases the stability of construct [9].

Majority of the patients belonged to the age group of more than 60 years. 60 percent of the patients of the PFN group were females while 50 percent of the patients of the PFN anti-rotation group were females. Domestic fall was the most common etiologic factor of injury in the present study. Mean time to sit among subjects of the PFN group was 2.9 days while it was 2.7

days among the subjects of the PFN anti-rotation respectively. In another study, Carulli C *et al*. reported their clinical and radiological results of fixation with Proximal Femoral Nail "antirotation" (PFNa) in a population of patients compared to a control group treated by Sliding Hip Screw (SHS). A prospective study was conducted in 71 consecutive patients treated by PFNa (group A), and 69 by a SHS (group B), with a mean age of 81.6 and 83.4 years respectively. Short Form 12 was administered to check postoperative results, and the following parameters were evaluated: range of motion, evaluation of pain, gait ability, X-rays, and Tip Apex Distance Index. A minimum follow-up was conducted in 128 patients: 66 subjects belonging to the PFNa group and 62 to the DHS group. All patients in the group A were able to reach partial or full weight-bearing on the operated leg before leaving the hospital. Forty-four patients (63.8%) of the group B were able to walk with partial weight-bearing before discharge. They recorded 17 complications with a final overall percentage of 17.2% on the overall study population with one single case of failure in both the two groups. A statistical significance of superiority for PFNa was demonstrated regarding surgical time, amploscope time, intraoperative blood loss, hospital stay, recovery of weight-bearing before discharge. Less significant results were found for walking ability at the three-months follow-up and patients' satisfaction 6 months after surgery [10].

We didn't observed any significant difference while comparing the mean time to sit, mean time to stand and mean time to walk among subjects of the double screw group and the helical screw group (P-value > 0.05). We didn't observe any significant results while comparing the mean HHS among patients of both the study groups at different time intervals. Swamy A *et al*. assessed and compared the dynamic hip screw & proximal femoral nail in treatment of intertrochanteric fracture. They observed that proximal femoral nailing was better procedure as compared to dynamic hip screw for intertrochanteric fracture [11].

Table 1: Age-wise distribution of patients

Age group (years)	PFN	PFN anti-rotation
Less than 40	1	2
40 to 60	3	2
More than 60	6	6

Table 2: Gender-wise distribution of patients

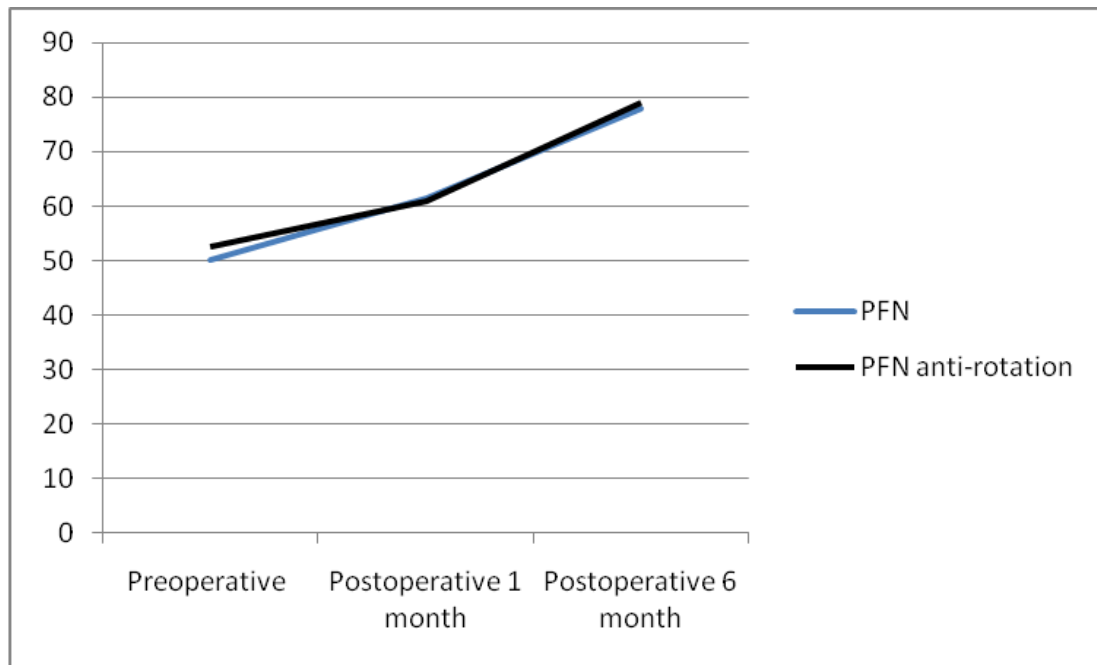
Gender	PFN	PFN anti-rotation
Males	4	5
Females	6	5

Table 3: Comparison of mean time when patients were allowed to partially bear weight among subjects of both the study groups

Parameter	PFN	PFN anti-rotation	P-value
Mean time to sit (days)	2.9	2.7	0.99
Mean time to stand (days)	5.2	5.1	0.15
Mean time to walk (days)	5.8	5.6	0.36

Table 4: Comparison of mean HHS among subjects of both the study groups

HHS Score	PFN	PFN anti-rotation	P-value
Preoperative	50.2	52.6	0.55
Postoperative 1 month	61.5	60.8	0.36
Postoperative 6 month	77.9	78.9	0.71



Graph 1: Comparison of mean HHS among subjects of both the study groups

Conclusion

Under the light of above obtained results, the authors conclude that in treating intertrochanteric fractures of femur, both the treatment protocols could be used with equal efficacy. Further studies are recommended.

References

- Sadic S, Custovic S, Jasarevic M, Fazlic M, Krupic F. Proximal Femoral Nail Antirotation in Treatment of Intertrochanteric Hip Fractures: a Retrospective Study in 113 Patients. *Medical Archives*. 2015; 69(6):352-356.
- Endigeri P, Pattanashetty OB, Banapatti DB, Pillai A, Ullas T. Outcome of intertrochanteric fractures treated with proximal femoral nail: A prospective study. *J Orthop Traumatol Rehabil* 2015; 8:25-9.
- Nherera L, Trueman P, Horner A, Watson T, Johnstone AJ. Comparison of a twin interlocking derotation and compression screw cephalomedullary nail (InterTAN) with a single screw derotation cephalomedullary nail (proximal femoral nail antirotation): A systematic review and meta-analysis for intertrochanteric fractures. *J Orthop Surg Res*. 2018; 13:46.
- Zhang K, Zhang S, Yang J *et al*. Proximal femoral nail vs. dynamic hip screw in treatment of intertrochanteric fractures: a meta-analysis. *Med Sci Monit*. 2014; 20:1628-33.
- Li M, Wu L, Liu Y, Wang C. Clinical evaluation of the Asian proximal femur intramedullary nail antirotation system (PFNA-II) for treatment of intertrochanteric fractures. *J. Orthop. Surg. Res*. 2014; 13:1-8.
- Gardenbroek TJ, Segers MJ, Simmermacher RK, Hammacher ER. The proximal femur nail antirotation: an identifiable improvement in the treatment of unstable pertrochanteric fractures. *J. Trauma*. 2011; 71:169-174.
- Shen L, Zhang Y, Shen Y, Cui Z. Antirotation proximal femoral nail versus dynamic hip screw for intertrochanteric fractures: a meta-analysis of randomized controlled studies. *Orthop. Traumatol. Surg. Res*. 2013; 99:377-383.
- Kumar GNK, Sharma G, Khatri K, Farooque K, Lakhota D, Sharma V *et al*. Treatment of Unstable Intertrochanteric Fractures with Proximal Femoral Nail Antirotation II: Our Experience in Indian Patients. *The Open Orthopaedics Journal*. 2015; 9:456-459.
- Gadegone WM, Shivashankar B, Lokhande V, Salphale Y. Augmentation of proximal femoral nail in unstable trochanteric fractures. *SICOT J*. 2017; 3:12.
- Carulli C, Piacentini F, Paoli T, Civinini R, Innocenti M. A comparison of two fixation methods for femoral trochanteric fractures: a new generation intramedullary system vs sliding hip screw. *Clinical Cases in Mineral and Bone Metabolism*. 2017; 14(1):40-47.
- Swamy A, Swamy A, Kshirsagar A, Sharma K. Comparative study between dynamic hip screw & proximal femoral nail in treatment of intertrochanteric fracture. *International Journal of Orthopaedics Sciences* 2017; 3(3):628-637.