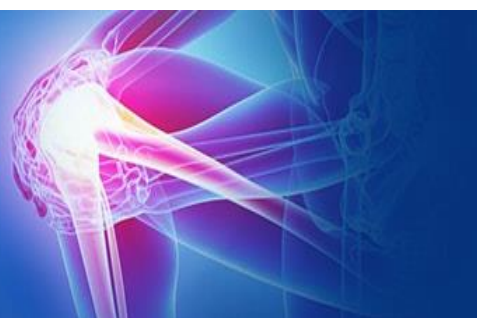



ISSN (P): 2521-3466  
ISSN (E): 2521-3474  
© Clinical Orthopaedics  
[www.orthoresearchjournal.com](http://www.orthoresearchjournal.com)  
2020; 4(1): 90-92  
Received: 08-11-2019  
Accepted: 12-12-2019

**Dr. Mohammed Aman Ul Haq Qureshi**  
Assistant Professor, Deccan  
College of medical sciences,  
Hyderabad, Telangana, India

**Dr. P Karthik Reddy**  
Assistant Professor, Deccan  
College of Medical Sciences,  
Hyderabad, Telangana, India

**Mohammed Jalal Mohiuddin**  
Assistant Professor, Deccan  
College of Medical Sciences,  
Hyderabad, Telangana, India

**Corresponding Author:**  
**Dr. P Karthik Reddy**  
Assistant Professor, Deccan  
College of medical sciences,  
Hyderabad, Telangana, India

## Case series-spontaneous chronic Tendo Achilles (TA) rupture and management

**Dr. Mohammed Aman Ul Haq Qureshi, Dr. P Karthik Reddy and Mohammed Jalal Mohiuddin**

**DOI:** <https://doi.org/10.33545/orthor.2020.v4.i1b.204>

### Abstract

Although being the strongest tendon in the body, the Achilles tendon is the most frequently ruptured tendon in the lower limb and comprises approximately 20% of all large tendon ruptures. The classical site of rupture is generally 3cm-6cm proximal to its insertion into the calcaneal tuberosity, as there is a hypo vascular zone present in this area of tendon. The most common mechanism usually involves eccentric loading on a dorsiflexed ankle with the knee extended (soleus and gastrocnemius on maximal stretch).

A bilateral Tendo Achilles rupture is uncommon, and for it to occur spontaneously is notably rare (1%). Risk factors for spontaneous TA ruptures includes local Corticosteroid use, Quinolone antibiotics (ciprofloxacin), previous tendon rupture, Systemic disease (like gout, hypothyroidism, diabetes, tuberculosis, gonorrhoea, syphilis, systemic lupus erythematosus, rheumatoid arthritis), Ageing, Increased BMI and Primary Achilles tendon tumors etc.

Described are the 10 feet (8 patients), two had bilateral presentation. All came after 3 weeks of injury and treated with debridement, V-Y plasty and FHL (flexor Hallucis Longus) transfer. All patients regained full movements at the ankle and resume their routine activities at 3 months follow-up.

**Keywords:** Spontaneous, Tendo Achilles, rupture, FHL, V-Y plasty

### Introduction

Although being the strongest tendon in the body, the Achilles tendon is the most frequently ruptured tendon in the lower limb and comprises approximately 20% of all large tendon ruptures [1]. The other tendons known for spontaneous rupture are quadriceps tendon, rotator cuff tendon and biceps long head tendon. The classical site of rupture is generally 3cm-6cm proximal to its insertion into the calcaneal tuberosity, as there is a hypovascular zone present in this area of tendon [2]. The vascular supply to the Tendo Achilles originates from three sources: the surrounding connective tissue, the Musculo-tendinous junction and the bone-tendon junction. Mid portion of the tendon shows least blood vessels density [3].

The most common mechanism usually involves eccentric loading on a dorsiflexed ankle with the knee extended (soleus and gastrocnemius on maximal stretch) [4]. A bilateral Tendo Achilles rupture is uncommon, and for it to occur spontaneously is notably rare (1%) [5].

Risk factors for the spontaneous TA rupture includes local Corticosteroid use, Quinolone antibiotics (ciprofloxacin), Previous tendon rupture, Systemic diseases (like gout, hypothyroidism, diabetes, tuberculosis, gonorrhoea, syphilis, systemic lupus erythematosus, rheumatoid arthritis), Ageing, Increased BMI and Primary Achilles tendon tumors [6]. All these diseases affect the collagen synthesis and also the repair process in tendon substance.

Ciprofloxacin is the one of the common antibiotic used for infection of Respiratory or urinary tract infection. There is strong correlation between the TA rupture and quinolones therapy with incidence of 1.2 per 10000 patients with quinolones medication. The dosage has no much effect and presentation may range as early as two hours to eighteen months after therapy [7].

There are various procedures documented for the reconstruction and repair of chronic tendon rupture. These include primary repair and augmentation with fascia advancement, tendon transfer, free tissue transfer, synthetic grafts or allografts [8].

The common method in use is the transfer of tendon for augmentation of the diseased Tendo Achilles. The FHL or peroneus brevis are the muscles used for this purpose. The FHL is a strong, long tendon and it allows bridging of large gaps resulting from retraction of rupture ends. The FHL muscle itself is able to produce force that supplements the strength exerted by the gastrocnemius-soleus complex. In case of athletic and sportive person who needs to have forced grip over ground FHL is needed. In such patient it's preferable to avoid FHL transfer and can utilize peroneus brevis<sup>[9]</sup>.

In the present study, we used FHL as the augmenting tendon and there are two cases with bilateral rupture which is very uncommon with very few case reports published in literature.

### Aims and Objectives

- To evaluate the cause of spontaneous rupture.
- To study the presentation and treatment plan of spontaneous rupture.
- To study final outcome of the reconstruction procedure.

### Methodology

**Study:** retrospective study done after IRB clearance at our Medical College.

**Sample size:** 8 patients (two has bilateral and six had unilateral involvement). The total number of ruptured tendon is 10.

### Inclusion criteria

- Spontaneous ruptures.
- All age groups.

### Exclusion criteria

- Traumatic ruptures

### Procedure

After selecting the patients, the demographic details of patients recorded. History of any chronic diseases and medications that can influence tendon strength as noticed. All patients examined clinically with Simmonds-Thompson test and radiologically by ultra sonogram.

For all the patients the procedure done was debridement, V-Y plasty and FHL transfer. The harvested distal stump of FHL passed through the tunnel made in calcaneum. The FHL anchored outside the heel over the stitch button. Five cases FHL weaved through Tendo Achilles substance and in remaining five just anchored in side of Tendo Achilles after anchoring to calcaneum.

Five cases operated by taking single long incision though the calf exposing the Apo neurosis and the tendon (Fig 3) and

remaining five case two separate incisions taken one for aponeurotic V-Y plasty and one for the ruptured tendon (fig 4). Suture material used is 5 number ethibond (both for TA approximation and FHL fixation).

Post operative below knee cast applied in plantar flexion for 8 weeks. Suture removal was done after 2 weeks and after 8 weeks of POP patient further maintained on high heel foot wear for 4 weeks.

Patients allowed returning for routine activity after that, without any special foot wear.

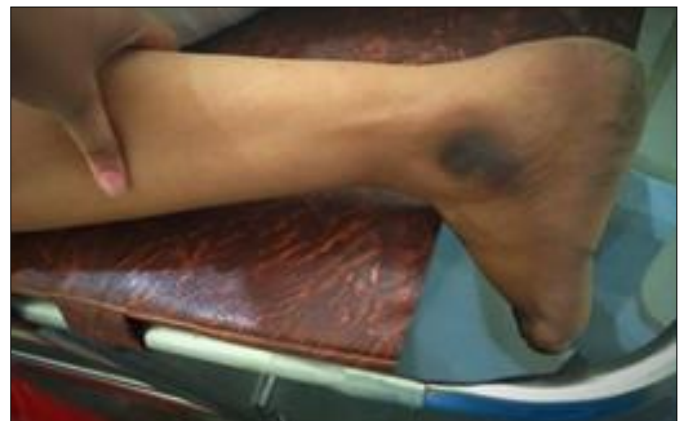### Result

There were three male and five Female (two had bilateral involvement) patients. Examination showed palpable gap seen in all the patients with positive Simmonds-Thompson test (fig 1). The presentation range 25 days to 6 weeks. The reason being minimal pain with disability and no history of significant injury, they took local medication for pain thinking as sprain.

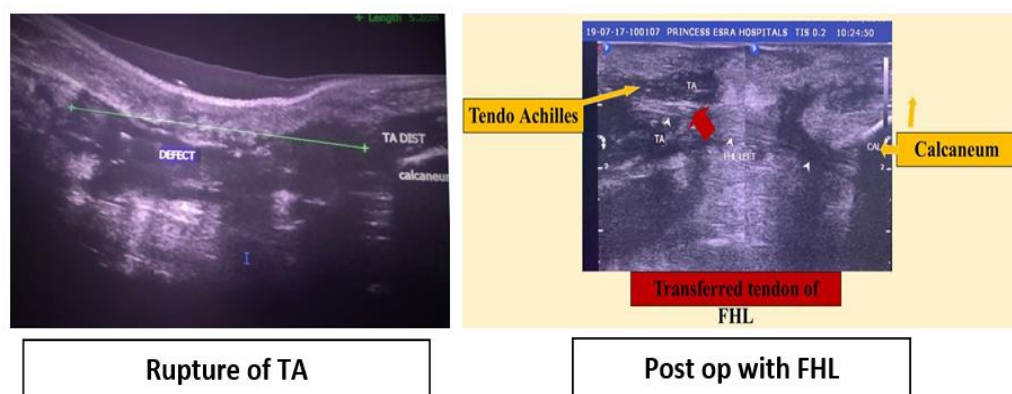
Ultrasound has demonstrated complete avulsion from the calcaneum insertion in 3 feet, low rupture five feet and high rupture in 2 feet (fig 2). All patients had degenerative picture of the tendon and the rupture ends. There was demonstrable gap of 2cms or more than 2cms in all patients which exist even on the plantar flexion indicating migration of proximal end.

The preexisting disorder was Hypothyroid in three females and one male (total 4 patients), rheumatoid arthritis in one male and one female (bilateral rupture). There was hyper uricemia in one female and one male (fig 5).

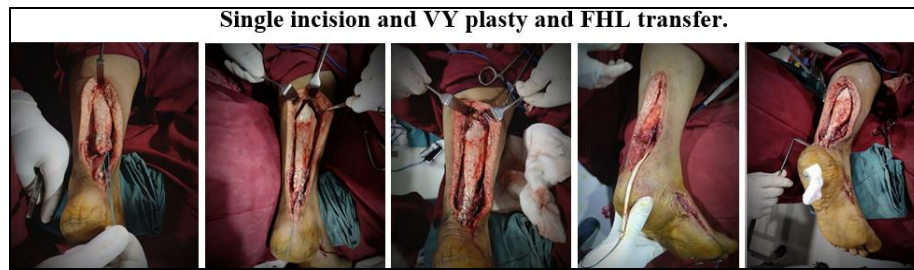None of the patients had history of any regional steroid intake or any quinolones (other drugs) administration. There was no any wound dehiscence or delayed healing. There was no coexistence of any other tendon rupture with this condition.



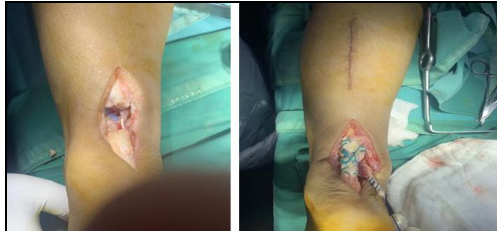**Fig 1:** Simmonds-Thompson test




**Fig 2:** Pre op and post op-Ultrasound images



**Fig 3:** steps of the surgery for TA debridement, V-Y plasty and FHL transfer.



**Fig 4:** Two incision and VY plasty and FHL transfer.



**Fig 5:** polarizing microscope

### Discussion

The spontaneous Tendo Achilles rupture has been described in literature. G. Thevendran *et al.* Described the risk factors of TA rupture which includes metabolic disorders, endocrinopathies, autoimmune disorders and various medications<sup>[10]</sup>. He described the degenerative and mechanical theories. In spontaneous ruptures it is mainly the degeneration causing the weakening of the TA. This was seen in all cases sent for biopsy where the degenerative histological changes found on microscopy. There are few case reports describing bilateral involvement and the incidence found is around 1%, as described by Khan Zada Z<sup>[11]</sup>. There was two such cases in our study population which make this series unique. Wong J *et al.*<sup>[12]</sup> compared the complication with conservative and operative management. It was found that there is high incidence (14%) of wound dehiscence in surgical repair when compare to conservative functional treatment (0.5%) and open repair had a lower risk of re-rupture (3.5%) than non-operative repair (12.6%). In our study we didn't have re-rupture in 6 months follow-up and there was no wound dehiscence found. All patients the FHL tendon was used, and it was found that there was no compromise over the regular activity of patient after FHL disconnection. It was easy to harvest and mechanically superior.

### Conclusion

Delayed or missed diagnosis of spontaneous Tendo Achilles rupture by primary treating physician is relatively common as

there is no history of major trauma. They may get treated as sprain with medication etc.

Any patient having risk factors of such conditions need to be checked for possible tendon rupture and referred at earliest. There is strong correlation of local steroid injection administered along the tendon for relief of pain in the heel region, to the tendon rupture, this practice need to be stopped.

Hyper-uricemia though rarely seen in females before menopause, can present as a complication of various tendon ruptures. The drugs and diseases predisposing TA rupture need to be kept under control and need long term medications to avoid such problems and other tendon need to be screened for the rupture if at all coexists.

### References

1. Habusta SF. Bilateral simultaneous rupture of the Achilles tendon: a rare traumatic injury. *ClinOrthopRelat Res.* 1995; 320:231-234.
2. Inglis AE, Sculco TP. Surgical repair of rupture of the tendo Achillis. *ClinOrthop Relat Res.* 1981; 156:160-169.
3. Thevendran G, Sarraf KM, Patel NK *et al.* The ruptured Achilles tendon: a current overview from biology of rupture to treatment. *Musculoskelet. Surg.* 2013; 97:9-20.
4. Khanzada Z, Rethnam U, Widdowson D, Mirza A. Bilateral spontaneous non-traumatic rupture of the Achilles tendon: a case report. *J Med Case Rep.* 2011; 5:263.
5. Van der Linden PD, Sturkenboom MC, Herings RM, Leufkens HM, Rowlands S, Stricker BH. Increased risk of Achilles tendon rupture with quinolone antibacterial use, especially in elderly patients taking oral corticosteroids. *Arch Intern Med.* 2003; 163:1801-1807.
6. Lee WT, Collins JF. Ciprofloxacin associated bilateral Achilles tendon rupture. *Aust NZJ Med.* 1992; 22:500.
7. Ribard P, Audisio F, Kahn MF *et al.* Seven Achilles tendonitis including 3 complicated by rupture during fluoroquinolone therapy *J Rheumatol.* 1992; 19:1479-81.
8. Ozan F, Dogar F, Gurbuz K, Ekinici Y, Koyuncu S, Sekban H. Chronic Achilles Tendon Rupture Reconstruction Using the Lindholm Method and the Vulpius Method. *J Clin Med Res.* 2017; 9(7):573-578.
9. Oksanen MM, Haapasalo HH, Elo PP, Laine HJ. Hypertrophy of the flexor hallucis longus muscle after tendon transfer in patients with chronic Achilles tendon rupture. *Foot Ankle Surg.* 2014; 20(4):253-7.
10. Thevendran G *et al.* The ruptured Achilles tendon: a current overview from biology of rupture to treatment. *Musculoskelet Surg.* 2013; 97:9-20.
11. Khanzada Z, Rethnam U, Widdowson D, Mirza A. Bilateral spontaneous non-traumatic rupture of the Achilles tendon: a case report. *J Med Case Rep.* 2011; 5:263.
12. Wong J, Barrass V, Maffulli N. Quantitative review of operative and nonoperative management of Achilles tendon ruptures. *Am J Sports Med.* 2002; 30(4):565.